

Endoscopic Ultrasound : A New Hope for Patients

S PERVEEN^a, V DHIR^b, RK PARAMASIVAM^c, MR HOSSAIN^d, MA AHMED^e, A MAYDEO^f

Summary:

Endoscopic Ultrasound (EUS) combines endoscopic view and ultrasound images to obtain information about the gastrointestinal tract and the surrounding tissues and organs in abdomen and mediastinum. Placing the transducer on the tip of an endoscope allows it to get close to the organs inside the body. The EUS can also obtain information about the layers of the intestinal wall as well as adjacent areas such as lymph nodes and the blood vessels. It can study the flow of blood inside blood vessels using Doppler ultrasound and obtain tissue samples by passing a FNA needle into enlarged lymph nodes or suspicious tumors. Staging of cancer is becoming an important use of EUS. It can provide information regarding the depth of penetration and spread of cancer to adjacent tissues and lymph nodes, useful for staging. Interventional EUS offers durable analgesia for

palliation and minimally invasive drainage procedures which does not result in cutaneous fistulae. In future, Interventional EUS will open up a new frontier hence further improving the contributory role of GI endoscopy.

Our aim was to evaluate the role of endoscopic ultrasound (EUS) in literatures of the past 3 decades as diagnostic and therapeutic aid based on original articles (randomized controlled trials, prospective and retrospective studies), meta-analyses, reviews and surveys pertinent to gastrointestinal EUS. MEDLINE and PubMed search (1984-2013) were conducted using 'Endoscopic Ultrasound' for re-triiving pertinent studies and arranged according to equipment introduction, uses, procedures, advantage, disadvantage, complications,, therapeutic applications and limitations of EUS. Figures included are taken during performance of the EUS procedures at the institute.

(J Bangladesh Coll Phys Surg 2015; 33: 23-31)

Introduction:

Endoscopic Ultrasound (EUS) combines endoscopy and ultrasound to obtain images and information about the digestive tract and the surrounding tissues and organs. It uses an endoscope with an ultrasound probe at the tip. Endoscopy visualizes the digestive tract whereas ultrasound produces images that are near the digestive tract such as liver, gallbladder, pancreas, aorta etc. It facilitates precise imaging of the gut layers as well as extraluminal structures. In 1980, since the development of endoscopic ultrasound, many symposia and studies have evaluated the application of the EUS technique in clinical practice.¹⁻⁹

In Bangladesh for a population of 160 million where pancreatic ailment occupy a major portion of GI disease there is only one EUS at Dhaka medical college. Along with trained personnel the number of instrument must be increased to help those ailing population. Though EUS can never replace gastroscop for routine endoscopic procedure but it is emerging as the most important interventional advancement in near future. This review outlines the diagnostic and therapeutic applications and limitations of EUS along with comparisons to conventional imaging procedures.

Equipment

Echoendoscopes are designed using either a radial or curvilinear array system. It is a modified endoscope, having both optical video views as well as ultrasound image capability. Acoustic coupling with the mucosa is achieved by using a probe with water-filled balloon at its tip (Fig 1).

Radial Echoendoscope

Radial echoendoscopes consists of a rotating ultrasound transducer situated distal to an oblique-viewing lens at the tip of the endoscope. The images obtained are cross-sectional (360°) in nature, like 'slices' obtained via CT scan (Fig 2). They are also provided with Doppler capabilities.

- a. Lt. Col. Shaila Perveen, Senior Physician & Gastroenterologist, CMH Jessore.
- b. Dr. Vinay Dhir, Chief of Endoscopic Ultrasound, Baldota Inst of Digestive Sciences (BIDS), Mumbai, India.
- c. Dr. Rajesh Kumar Paramasivam, Interventional Gastroenterologist, Kualalumpur, Malaysia.
- d. Maj. Gen. Md Rabiul Hossain, Consultant Physician General, Bangladesh Armed Forces.
- e. Lt. Col Mir Azimuddin Ahmed, Head of the Department of Pathology, AFMC, Dhaka Cantonment.
- f. Dr. Amit Maydeo, Chief of Gastroenterology & Director, Baldota Inst of Digestive Sciences (BIDS), India.

Address of Correspondence: Lt. Col. Shaila Perveen, Classified Medical Specialist, Bangladesh Armed Forces, phone: +8801819294922. Endoscopy Fellow, Indian College of Endoscopy, Mumbai, India, phone: +919930946588.

Received: 9 January, 2014

Accepted: 12 October, 2014

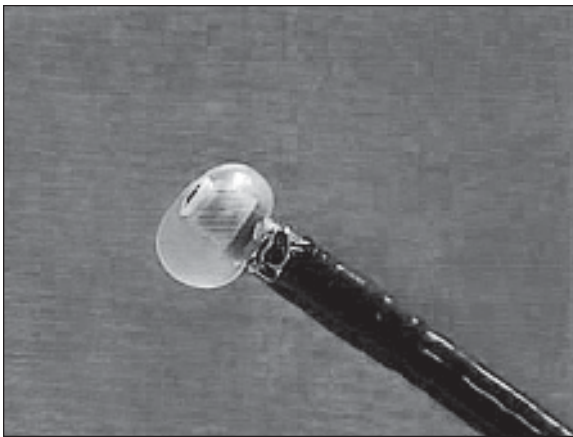


Fig.-1: Endoscopic ultrasound with water-filled balloon at the tip

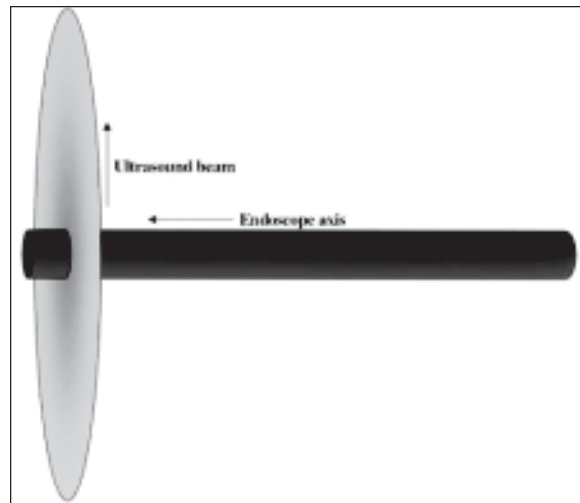


Fig.-2: The radial scope scans at an axis perpendicular to the shaft

Linear Echoendoscope

Linear echoendoscope is oriented in the same plane as the scope shaft with the field of view ranging between 120° to 180° and accessory channel. It has the capability to perform fine needle aspiration using the accessory channel (Fig 3). As the needle passes in the same axis as the ultrasound beam, it is visible entirely when passed into the targeted lesion. Forward viewing linear (FVL) array echoendoscope provide vision like gastroscopes.

Needles

FNA needles for EUS applications range in size from 25G to 19G. Larger needles may increase trauma and

result in a more bloody sample but are required for therapeutic EUS procedures where guidewires must be passed through the needle. Needles may have beveled or ball-tips and contain stylets. Suction may be applied to aid in aspiration of fluid or tissue (Fig 4). An EUS nylon cytologic brush is useful in sampling pancreatic lesions, where needle aspirates are acellular.¹⁰

For the evaluation of submucosal lesions and lymphomas 19G Trucut biopsy needles are more accurate than EUS-FNA needles.¹¹ These devices can not function well when the echoendoscope is angulated, particularly in the second part of the duodenum.¹²

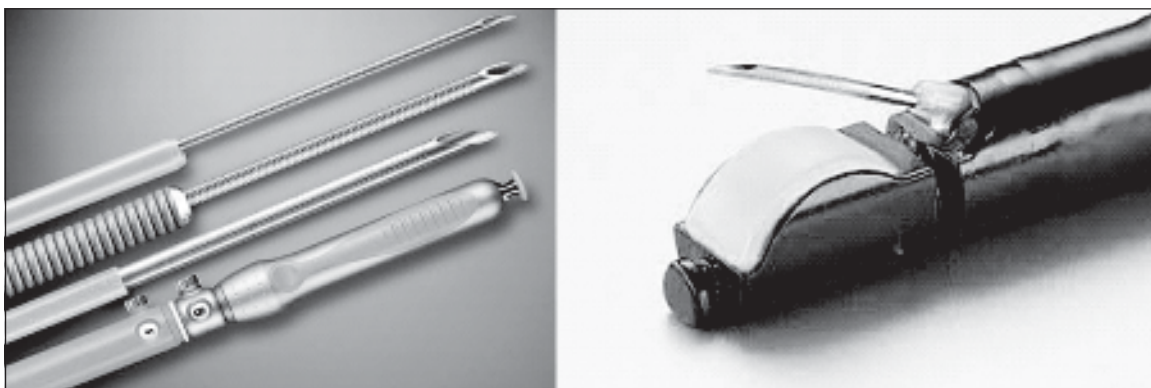

Fig.-3: The linear echoendoscope with needles inserted through the accessory channel are visualised by the ultrasound beam

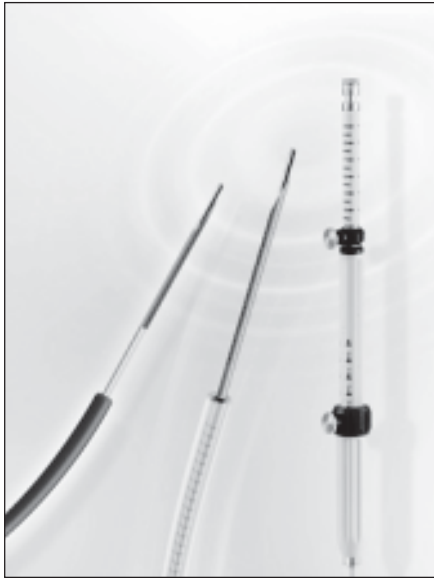

Fig.-4: Fluid can be aspirated by suction needle during EUS

Indications for EUS: They are diagnostic and therapeutic or interventional

Diagnostic uses of EUS :

- Evaluating pancreatic disease
- Studying bile duct abnormalities
- Diagnosis of various cancers
- Staging of gastrointestinal and lung cancers
- Determining prognosis of cancer
- Differentiation of tumors of the GIT
- Studying sphincters of rectum and anal canal
- Evaluation of GIST
- Studying the flow of blood
- Diagnostic aid when other tests are inconclusive

Therapeutic or Interventional Uses of EUS:

- Injection therapy and
- Drainage procedures of structures adjacent to GI lumen are facilitated with great accuracy by stent placement.

Procedures

Diagnostic EUS Procedure

The procedure is a highly specialized technique that is performed by a gastroenterologist (medical or surgical) with specialized training. For the patient, the procedure is almost identical to the normal endoscopic procedure unless ultrasound-guided biopsy of deeper structures is performed. It is performed on an out patient basis with the patient under anesthesia as it may cause mild to

moderate discomfort hence they are not able to return to work or to drive for 24 hours. The echoendoscope is passed through the mouth until the tip reaches the targeted region. If the lesion of interest lies within the gut wall, water can be instilled into the gut lumen so that high quality images can be obtained using water as a conductive medium.

Heart, pleura, spine, vascular structures and posterior mediastinal lymph nodes are visualized through the oesophageal wall (Fig 5). Through the gastric wall, body and tail of the pancreas, spleen, splenic vessels, celiac trunk, retroperitoneal lymph nodes, left adrenal gland and left lobe of the liver is viewed. Pancreatic head, pancreatic duct, common bile duct, portal vein are viewed from the proximal duodenum (Fig 6). Through second part of duodenum, ampulla, uncinate process of pancreas, superior mesenteric vessels can be visualized.

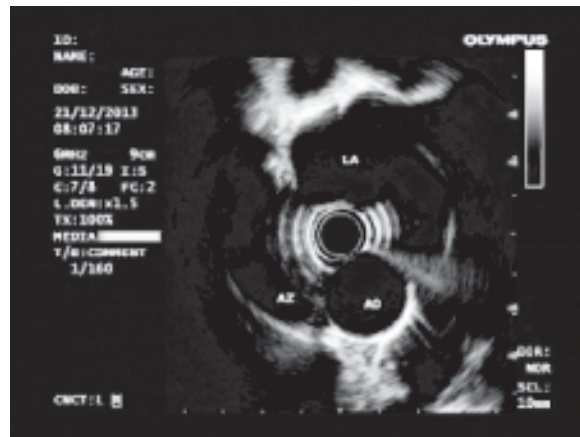


Fig.-5: Posterior mediastinal structures visualized via the oesophagus. (AO = aorta, LA = Left atrium, AZ=Azygous vein).

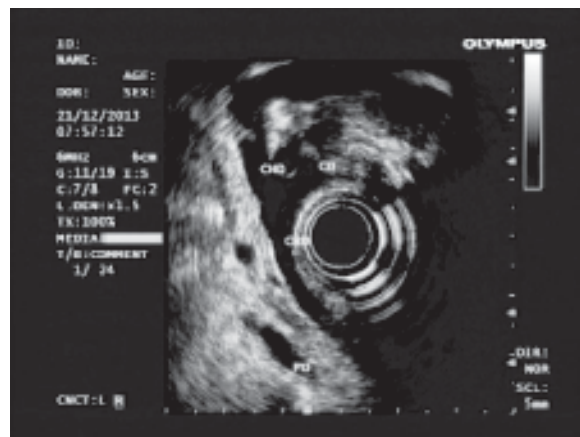


Fig.-6: From the duodenal cap, entire common bile duct (CBD) to the left and pancreatic duct (PD) below right.

Interventional EUS Procedure

The patients are placed in left lateral decubitus position. A linear echoendoscope is used to evaluate the mediastinal and abdominal lesions. After the lesion is identified, color flow and Doppler sonography are performed to choose a vessel free needle tract. Usually 22-25 gauge needle equipped with a stylet tightly fitting the needle is used to minimize contamination by the intervening GI mucosa. The catheter that contains the needle is then inserted through the working channel of the endoscope. When the tip of the catheter is visualized, the needle is advanced from the catheter sheath, through the wall of the bowel into the target lesion under ultrasound guidance. The stylet is removed when needle is within the target lesion and aspiration biopsy is performed by moving the needle back and forth for 2-3 passes with several strokes. The needle is then retracted. If additional passes are needed, the stylet is reinserted into the needle and the steps are repeated.¹³ This procedure is stopped after confirmation of adequacy of the material obtained. The presence of an cytopathologist to give instant feedback regarding specimen quality improves diagnostic certainty.¹⁴

Diagnosis of pancreatic diseases like chronic pancreatitis, pancreatic duct abnormalities and stones can be accurately diagnosed by EUS. The technique is highly sensitive for detection of pancreatic cancer (90-95% sensitivity). The sensitivity and specificity of EUS and EUS-FNA for the diagnosis of pancreatic tumors is 85% and 98% respectively.¹⁵ Autoimmune pancreatitis has characteristic appearances and use of EUS-FNA increases the diagnostic yield.¹⁶

EUS is superior to CT, MRI and somatostatin receptor scintigraphy in the localisation of pancreatic neuroendocrine tumors, which are often <1 cm.¹⁷ It is also superior to CT, MRI and transabdominal USG for the staging of periampullary carcinomas.¹⁸ Differentiation between the pancreatic cystic tumors (benign, malignant or potentially malignant) using conventional imaging is difficult. EUS can be considered complementary for distinguishing such lesions.^{19,20} US-FNA sampling of cystic fluid distinguishes mucinous from non-mucinous cysts with high specificity by measurement of cyst fluid CEA levels but does not predict malignancy.²¹ However, when ERCP does not visualize a part of the pancreatic duct or common bile duct, this area is usually seen well on EUS. It detects

vascular involvement by pancreatic tumors better than angiography.^{22,23,24} Preoperative endoscopic ultrasound with fine needle tattooing can localize 100% of insulinomas.²⁵

Studying bile duct abnormalities like stricture or dilatation, stones in the bile duct or gallbladder, tumors of bile duct, gallbladder or liver. A cost-benefit analysis found EUS to be of greatest value for doubtful choledocholithiasis having a sensitivity between 89–94% and a specificity of 94%.^{26,27} However, ERCP remains preferable for patients whose probability of choledocholithiasis is high (>55%) because of therapeutic advantage.²⁸

Diagnosis of cancer is often best done by EUS. Cancers located in the esophageal wall, gastric wall, mediastinum, bile ducts and pancreas can be accurately characterized in depth by it. FNA can be done to confirm the presence of cancer cells.

Staging of gastrointestinal cancers include cancers of the esophagus, stomach, pancreas, bile ducts and rectum. EUS helps in determining the extent of these tumors (staging). According to the TNM classification depth of invasion (T), presence of locoregional lymph nodes (N) and presence of distant metastases (M) are important.²⁹ EUS imaging is beneficial in locoregional T and N staging, providing an accuracy of approximately 85% in GI luminal cancers.³⁰ Often lymph nodes in the involved area may be sampled with FNA to diagnose lymph node involvement. Regarding cost involvement, advances such as contrast enhanced endoscopic ultrasound (CE-EUS) and real time elastography show potential to improve the accuracy for the differential diagnosis of benign and malignant lymph nodes. Complementary to size criteria, CEUS could also be used to evaluate response of tumor angiogenesis to anti-angiogenic therapies in the assessment of treatment response.³¹

Staging of lung cancer by EUS-FNA is >90% accurate in nodal staging of non small cell lung cancer (NSCLC), being more sensitive than CT³² and more specific than PET.^{32,33} This also has efficacy in assessing tumor stage, taking biopsy of tumor adjacent the oesophagus and assessment of metastatic disease in the left lobe of the liver and left adrenal gland. EUS-FNA reduces the need for mediastinoscopy or thoracotomy by up to 50%.³⁴

The prognosis of a cancer is related to the stage of the cancer at the time of detection. The impact of EUS-FNA is significant in changing the management of patients with GI, pancreatic and pulmonary malignancy often resulting in the avoidance of unnecessary interventions or surgery.^{35,36,37}

Differentiation and screening for tumors of malignant from benign origin of gastrointestinal tract (pancreatic, esophageal and gastric) can be done by EUS.

Studying the muscles of the lower rectum and anal canal in evaluating reasons for fecal incontinence and tracing perianal fistulous tracts can be done by EUS.

GIST or ‘submucosal lesions’ are encountered during routine endoscopy often, mucosal biopsies of which are

non-diagnostic. EUS determines the layer of origin and detects characteristic appearances (Fig7, 8) of cysts, lipomas, leiomyomas and stromal tumors. EUS-FNA of such lesions has a diagnostic yield of up to 91%.³⁸

Studying the flow of blood can be done by using Doppler ultrasound.

EUS guided injection therapy

Injection of bupivacaine for Coeliac plexus block and neurolysis with absolute alcohol attains durable analgesia in up to 91% of patients with pancreatic cancer.³⁹ A linear echoendoscope is directed towards the coeliac ganglia at the origin of the coeliac trunk with a 22-19G FNA or CP needle. EUS technique is safer than the CT guided percutaneous approach.⁴⁰ The

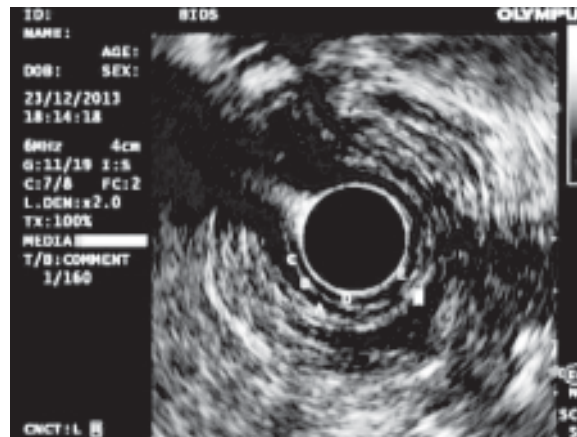


Fig.-7: The five layers of the gastric wall at EUS, from outer to inner: A is serosa(white) , B and D are two muscle (black) layers , C the third layer (white) is submucosa, E is the mucosa(white)

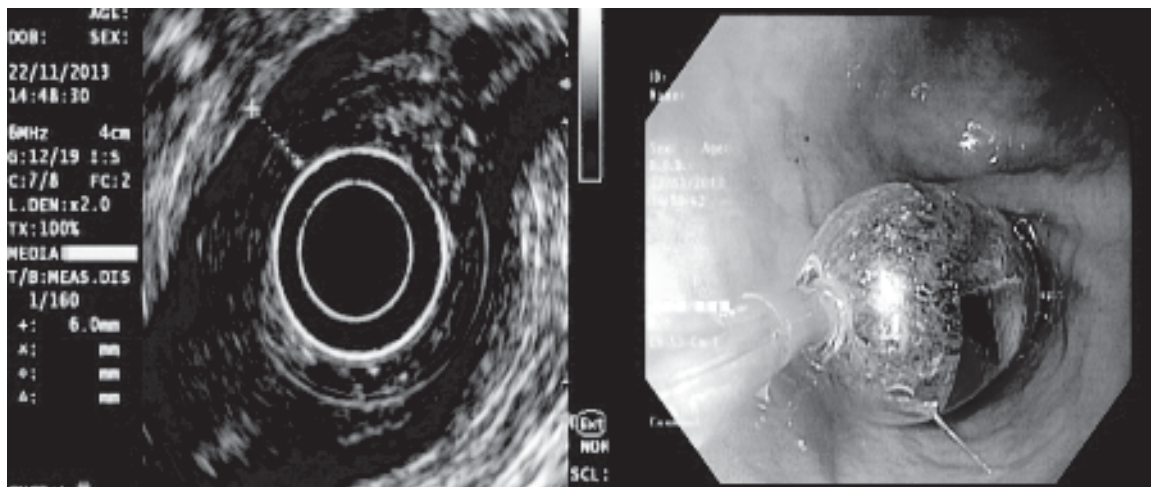


Fig.-8: Hypertrophic pyloric stenosis in a patient of 67 years with GOO showing thickening of muscle layers later relieved by balloon dilatation.

procedure is less efficacious in chronic pancreatitis. Corticosteroids (triamcinolone) reduced pain scores beyond 12 weeks in 26% of these subjects.⁴¹

The poor prognosis of pancreatic cancer has prompted the use of EUS for intratumoral injection of chemotherapeutic agents.⁴² EUS guided fine needle injection (FNI) of adenoviral vectors targeting tumor cells has been described.^{43,44} Combination of ethanol lavage and paclitaxel injection was safe and effective in ablating the epithelial lining of cystic tumors of the pancreas.⁴⁵ In future, by directly injecting malignant tumors with chemotherapeutic agents from inside the body will particularly benefit patients with pancreatic, esophageal and rectal cancer.

EUS guided drainage procedures

Surgical and percutaneous approaches to necrosectomy drainage of pancreatic pseudocyst are associated with

significant morbidity and mortality.⁴⁶ EUS-guided stenting and drainage of pancreatic pseudocyst is minimally invasive and does not result in cutaneous fistulae. It is performed by transgastric or transduodenal puncture under EUS guidance, followed by a cystogastrostomy or cystoenterostomy by insertion of stents (Fig 9, 10). The procedure was successful in 94% of cases with no mortality in one series of 51 patients.⁴⁷ Similar techniques have been reported for the drainage of mediastinal⁴⁸ hepatic⁴⁹ splenic⁵⁰ subphrenic⁵¹ and pelvic⁵² abscesses. EUS-guided transmural cholecystoenterostomy has been described in patients who are at high risk for surgical intervention.^{53,54} In failed ERCP cases, EACP (endoscopic anterograde cholangio pancreatography) can be done using the curved linear array echoendoscope. It involves 'anterograde' in contrast to the 'retrograde' approach of ERCP route.⁵⁵ In EACP, by EUS-guided puncture of

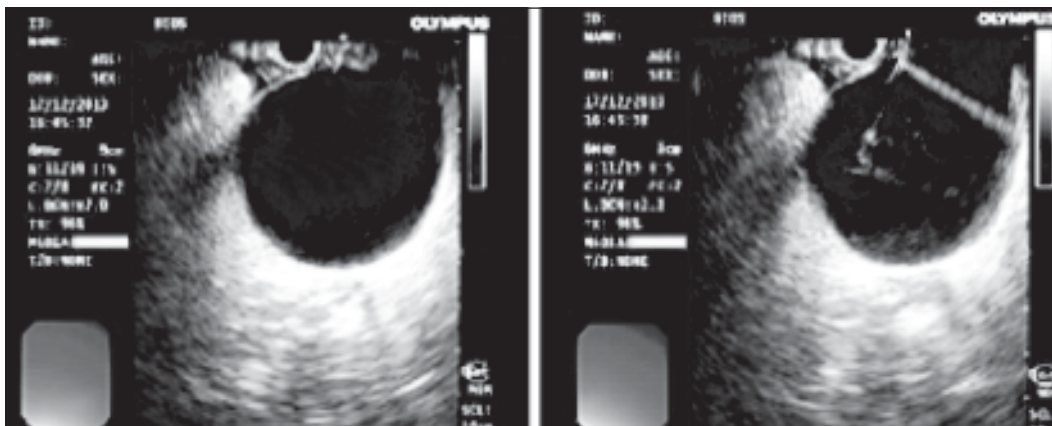


Fig.-9: A pancreatic pseudocyst. The FNA needle is seen passing from the gastric wall into the cyst under EUS guidance. It allows fluid aspiration and stent insertion.

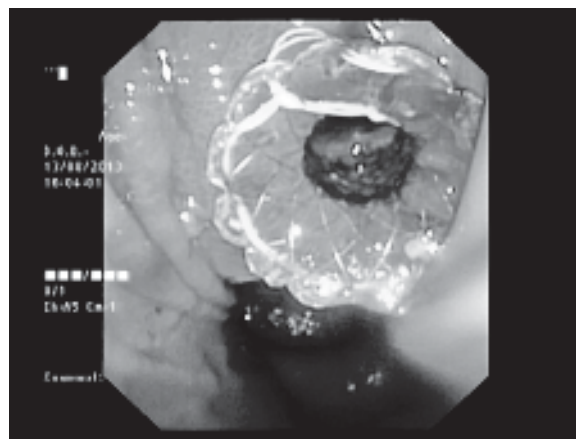


Fig.-10: The insertion of a metallic stent over guidewires from the stomach into the pseudocyst to allow drainage of the cyst into the stomach (cystogastrostomy) under EUS guidance.

a dilated pancreatic or biliary duct system, passage of a guidewire and insertion of a trans-duodenal or trans-gastric stent offers cholangio pancreatic drainage and can obviate the need for percutaneous drainage.

Advantage of Endoscopic Ultrasound

Since the development of endoscopic ultrasound, many symposia and studies have evaluated the application of the EUS technique in clinical practice. In traditional ultrasound a transducer is placed on the skin distantly overlying the organs of interest. In EUS because of the proximity of the EUS transducer to the organ(s) of interest, the images obtained are of high quality and more accurate than the ones obtained by traditional ultrasound. EUS has been shown to be superior to routine abdominal ultrasound, barium studies, CAT scans and even MRI scans for evaluating GI cancers and lesions that are below the mucosal surface. It can give detail information about the layers of the intestinal wall as well as adjacent structures such as lymph nodes and the blood vessels, often otherwise obtainable only by CT, MRI or even surgical intervention.

Limitations of Endoscopic Ultrasound

Present limitations of endoscopic ultrasound include:

1. Optimal focal range of 4 cm only.
2. Features of various pancreatic diseases and lymph nodes can appear similar and criteria

to distinguish diseases overlap. At present differentiation of focal chronic pancreatitis from carcinoma is also difficult.⁵⁶

3. Higher cost of the instrument and lack of expertise limits its widespread use though EUS guided fine needle aspiration (FNA) is the least costly staging strategy in the workup of patients with nonmetastatic pancreatic head adenocarcinoma; primarily because of confirmation of nonperitumoral lymph node involvement avoiding unnecessary surgery.⁵⁷

Complications

EUS is safe and well tolerated but no procedure is without risk. Complication rate for EUS is about one in two thousand, similar to other endoscopy procedures.⁵⁸ Sometimes, patients can develop reactions to the medications used during EUS. Perforation, the main complication of serious nature requiring surgical repair is quite rare. Complications occur more often when FNA

is performed but are still uncommon (0.5-1.0%). Most complications occur during therapeutic applications which is between 1–2%.⁵⁹ They include pancreatitis,, infection (particularly for EUS-FNA of pancreatic cystic lesions), haemorrhage and duodenal perforation. Infections following FNA of solid lesions or lymph nodes are rare and prophylactic antibiotics are not recommended.⁶⁰ If pancreatitis occurs it usually resolves spontaneously in a few days.

Conclusion:

At present EUS are utilized mostly for the diagnosis of gastrointestinal luminal and extraluminal diseases, staging of malignancies and limited number of therapeutic uses.. Expanding number of applicable therapeutic possibilities with accuracy and relative safety is making it cost-effective. If gastroenterologists of present time are not aware of the new frontier opened by EUS for future gastrointestinal intervention they will be lagging behind.. Equipment evolutions and improvements in image interpretation will overcome the present limitations hence further improving the contributory role of endoscopic ultrasound in near future.

References:

1. Meenan J and Vu C. Basics of EUS: Equipment. In: Hawes R, Fockens P. Endosonography. Philadelphia, W B Saunders 2006; 2 nd edition: 17–26.
2. Kawai K, Classen M. Endoscopic Ultrasonography. Proceedings of an international workshop on the occasion of the world congress. Scand J Gastroenterol 1984; 19(suppl 94):1-106,.
3. Tytgat GNJ, Tio TL. Endoscopic ultrasonography. Proceedings of the 4th international symposium on endoscopic ultrasonography. Scand J Gastroenterol 1986; 21 (suppl 123):110-171.
4. Tio TL, Tytgat GNJ. Atlas of transintestinal Ultrasonography. Aalsmeer, Smith, Kline & French b.v./ Mur-Kostler-voren, The Hague, Gegenens Koninklijke Bibliotheek, 1986;125-32.
5. Strohm WD, Classen M. Endoscopic ultrasonography: Gastroenterologic Endoscopy, Philadelphia, W.B.Saunders Co. 1987 ; Sivak M (ed): pp 182-202.
6. Kawai K. Endoscopic Ultrasonography in Gastroenterology. Tokyo, Japan, Igaku-Shoin Ltd. 1988; K(ed): pp 224-43.
7. Cotton P, Tytgat G, Williams C. Endosonography atlas London, UK, Current Science Ltd. 1990; 1st ed: pp 51-58.
8. Sivak MV, Boyce G (eds): Endoscopic ultrasonography Gastrointest Endosc 1991;36(suppl): pp1-46.

9. Shorvon PJ, Lees WR, Frost RA, et al. Upper gastrointestinal endoscopic ultrasonography in gastroenterology. *BR J Radiol* 1987; 60:429-438.
10. Al-Haddad M, et al. Safety and efficacy of cytology brushings versus standard FNA in evaluating cystic lesions of the pancreas: a pilot study. *Gastrointest Endosc* 2007; 65 (6): 894-8.
11. Levy MJ, et al. Comparison of endoscopic ultrasound-guided trucut biopsy (EUS-TCB) to endoscopic ultrasound-guided fine needle aspiration (EUS-FNA). *Gastrointest Endosc* 2003;57: 240-244.
12. Jones, DB. Role of endoscopic ultrasound in staging upper gastrointestinal cancers. *A NZ J Surg* 2007; 77(3): 166-72.
13. Vanessa M Shami and Irving Waxman. Technology Insight: current status of endoscopic ultrasonography. *Nature Clinical Practice Gastroenterology & Hepatology* 2005; 2: 38-45.
14. Klapman JB, et al. Clinical impact of on-site cytopathology interpretation on endoscopic ultrasound-guided fine needle aspiration. *Am J Gastroenterol* 2003; 98 (6): 1289-94.
15. Hawes R, Fockens P. *Endosonography*. Philadelphia: Saunders 2006: pp. 177-204.
16. Farrell JJ, et al. EUS findings in patients with autoimmune pancreatitis. *Gastrointest Endosc* 2004; 60 (6): 927-36.
17. Zimmer T, et al. Localisation of neuroendocrine tumours of the upper gastrointestinal tract. *Gut* 1994; 35 (4): 471-5.
18. Cannon ME, et al. EUS compared with CT, magnetic resonance imaging, and angiography and the influence of biliary stenting on staging accuracy of ampullary neoplasms. *Gastrointest Endosc* 1999; 50 (1): 27-33.
19. Ahmad NA, et al. Can EUS alone differentiate between malignant and benign cystic lesions of the pancreas? *Am J Gastroenterol* 2001; 96 (12): 3295-300.
20. Sedlack R, et al. Utility of EUS in the evaluation of cystic pancreatic lesions. *Gastrointest Endosc* 2002; 56 (4): 543-7.
21. Khalid A, W. Brugge. ACG practice guidelines for the diagnosis and management of neoplastic pancreatic cysts. *Am J Gastroenterol* 2007; 102 (10): 2339-49
22. Rosch T, Braig C, Gain T, et al: Staging of pancreatic and ampullary carcinoma by endoscopic ultrasonograph. *Gastroenterology* 102: 188-199, 1992.
23. Yasuda K, Mukai H, Fujimoto S, et al. The diagnosis of pancreatic cancer by endoscopic ultrasonography. *gastrointest Endosc* 1988; 34:1-8.
24. Snady H, Cooperman A, Siegel J. Assessment of vascular involvement by pancreatic disease-a comparison of endoscopic ultrasonography to computerized tomography and angiography. *Gastrointest Endosc* 1990; 36(A):197-99.
25. Gress FG, Barawi M, Kim D, Grendell JH. Preoperative localization of a neuroendocrine tumor of the pancreas with EUS-guided fine needle tattooing. *Gastrointest Endosc* 2002; 55: 594-597.
26. Garrow D, et al. Endoscopic ultrasound: a meta-analysis of test performance in suspected biliary obstruction. *Clin Gastroenterol Hepatol* 2007; 5 (5): 616-23.
27. Tse F, et al. EUS: a meta-analysis of test performance in suspected choledocholithiasis. *Gastrointest Endosc* 2008; 67 (2): 235-44.
28. Sahai AV, et al. Bile duct stones and laparoscopic cholecystectomy: a decision analysis to assess the roles of intraoperative cholangiography, EUS, and ERCP. *Gastrointest Endosc* 1999; 49 (3-1): 334-43.
29. American Joint Committee on Cancer, *AJCC Cancer Staging Manual* 6th ed. New York:Springer 2002; pp. 21-23.
30. Grimm H, et al. Endosonography for preoperative locoregional staging of esophageal and gastric cancer. *Endoscopy* 1993; 25 (3): 224-30.
31. Cui XW, Jenssen C, Saftoiu A, Ignee A, Dietrich CF. New ultrasound techniques for lymph node evaluation. *World J Gastroenterol* 2013 ;19(30): 4850-60.
32. Toloza EM, et al. Invasive staging of non-small cell lung cancer: a review of the current evidence. *Chest* 2003; 123 (1 Suppl): 157S-166S.
33. Fritscher-Ravens A, et al. Endoscopic ultrasound, positron emission tomography, and computerized tomography for lung cancer. *Am J Respir Crit Care Med* 2003; 168 (11): 1293-7.
34. Larsen SS, et al. Endoscopic ultrasound guided biopsy of mediastinal lesions has a major impact on patient management. *Thorax* 2002; 57 (2): 98-103.
35. Ortensen MB, et al. Clinical impact of endoscopic ultrasound-guided fine needle aspiration biopsy in patients with upper gastrointestinal tract malignancies. A prospective study. *Endoscopy* 2001; 33 (6): 478-83.
36. Wallace MB, et al. Endoscopic ultrasound in lung cancer patients with a normal mediastinum on computed tomography. *Ann Thorac Surg* 2004; 77 (5): 1763-8.
37. Le Blanc JK, et al. Endoscopic ultrasound in non-small cell lung cancer and negative mediastinum on computed tomography. *Am J Respir Crit Care Med* 2005; 171 (2): 177-82.
38. Ando N, et al. The diagnosis of GI stromal tumors with EUS-guided fine needle aspiration with immunohistochemical analysis. *Gastrointest Endosc* 2002; 55 (1): 37-43.
39. Guaratnam NT, et al. A prospective study of EUS-guided celiac plexus neurolysis for pancreatic cancer pain. *Gastrointest Endosc* 2001; 54 (3): 316-24.
40. Ang TL. Endoscopic ultrasound: moving from diagnostics to therapeutics. *J Dig Dis* 2008; 9(3):117-28.
41. Gress F, et al. Endoscopic ultrasound-guided celiac plexus block for managing abdominal pain associated with chronic pancreatitis: a prospective single center experience. *Am J Gastroenterol* 2001; 96 (2): 409-16.

42. Micames CG, FG Gress. Local EUS-guided injection of chemotherapeutic agents as adjuvant to systemic treatment: the first steps are made. *Gastrointest Endosc* 2007; 65 (3): 454–6.
43. Chang KJ, et al. Phase I clinical trial of allogeneic mixed lymphocyte culture (cytoimplant) delivered by endoscopic ultrasound-guided fine-needle injection in patients with advanced pancreatic carcinoma. *Cancer* 2000; 88 (6): 1325–35.
44. Sangro B, et al. Phase I trial of intratumoral injection of an adenovirus encoding interleukin-12 for advanced digestive tumors. *J Clin Oncol* 2004; 22 (8): 1389–97.
45. Oh HC, et al. New treatment for cystic tumors of the pancreas: EUS-guided ethanol lavage with paclitaxel injection. *Gastrointest Endosc* 2008; 67 (4): 636–42.
46. Vosoghi M, et al. EUS-guided pancreatic pseudocyst drainage: review and experience at Harbor-UCLA Medical Center. *Gen Med* 2002; 4 (3): 72-75.
47. Lopes CV, et al. Endoscopic-ultrasound-guided endoscopic transmural drainage of pancreatic pseudocysts and abscesses. *Scand J Gastroenterol* 2007; 42 (4): 524–9.
48. Whrmann T, et al. Endoscopic debridement of paraesophageal, mediastinal abscesses: a prospective case series. *Gastrointest Endosc* 2005; 62(3): 344–9.
49. Seewald S, et al. EUS-guided drainage of hepatic abscess. *Gastrointest Endosc* 2005; 61 (3): 495–8.
50. Lee DH, et al. Endoscopic therapy of a splenic abscess: definitive treatment via EUS-guided transgastric drainage. *Gastrointest Endosc* 2006; 64 (4): 631–4.
51. Seewald S, et al. EUS-guided drainage of subphrenic abscess. *Gastrointest Endosc* 2004; 59 (4): 578–80.
52. Trevino JM, Drelichman ER and Varadarajulu S. Modified technique for EUS-guided drainage of pelvic abscess. *Gastrointest Endosc* 2008; 68 (6): 1215–9.
53. Kwan V, et al. EUS-guided cholecystenterostomy: a new technique. *Gastrointest Endosc* 2007; 66 (3): 582–6.
54. Lee SS, et al. EUS-guided transmural cholecystostomy as rescue management for acute cholecystitis in elderly or high-risk patients: a prospective feasibility study. *Gastrointest Endosc* 2007; 66 (5): 1008–12
55. Kenneth F. Binmoeller, Thai Nguyen-Tang. Endoscopic ultrasound-guided anterograde cholangiopancreatography *Journal of Hepato-Biliary-Pancreatic Sciences* 2011; 18(3): 319-331.
56. Rosch T, Classen M: Endosonography - What are the limits in gastroenterological diagnostics? *Endoscopy* 1991; 23: 144-146,.
57. Adler DG, et al. ASGE guideline: complications of EUS. *Gastrointest Endosc* 2005; 61 (1): 8–12.
58. Harewood Gavin C, Wiersema Maurits J . A cost analysis of endoscopic ultrasound in the evaluation of pancreatic head adenocarcinoma. *American Journal of Gastroenterology* 2001; 96: 2651–2656.
59. Yamao K, et al. Interventional endoscopic ultrasonography. *J Gastroenterol Hepatol* 2009 ; 5 (5): 616–23
60. Hirota WK, et al. Guidelines for antibiotic prophylaxis for GI endoscopy. *Gastrointest Endosc* 2003; 58 (4): 475–82.