

# Analysis of Histological Variants of Ameloblastomas of Jaws in Relation to their Clinical Presentations

SB RAHMAN<sup>a</sup>, SMA SADAT<sup>b</sup>, IA HAIDER<sup>c</sup>, MAHMED<sup>d</sup>

## Summary:

*Ameloblastoma is an odontogenic tumour with variable clinical characteristics and histological patterns. This study was done to find out the relationship between clinical presentation and histological types of ameloblastoma to provide a base line data for better and appropriate patient management. A cross sectional study on consecutive 50 histologically diagnosed Ameloblastoma patients attended to the department of Oral and Maxillofacial Surgery, Dhaka Dental College and Hospital from July 2011 to June 2012*

## Introduction:

Ameloblastoma is an odontogenic tumour with variable clinical characteristics and histological patterns<sup>1</sup>. Tumours of odontogenic tissues are comparatively rare, comprising of about 1% of all jaw tumours. Ameloblastomas constitute almost half (48.9%) of the odontogenic tumours<sup>2</sup>. It generally occurs in bone, and it has been postulated that the epithelium of origin is derived from one of the following sources; (1) cell rest of enamel organ, (2) epithelium of odontogenic cysts (3) disturbance of the developing enamel organ, (4) basal cells of the surface epithelium or (5) heterotrophic epithelium in other parts of the body<sup>3</sup>.

Ameloblastoma, a clinically significant neoplasm of odontogenic epithelium is commonly encountered in Bangladesh<sup>4</sup>. The tumour is by far more common in the

*were included in the study. 75% clinically solid types were associated with histological follicular type and 62.5% cystic types were histological plexiform type. Plexiform type was found commonly in younger age group of patients than the follicular types. Desmoplastic ameloblastoma were found solely in anterior mandible.*

**Key Words:** Ameloblastoma, Follicular, Plexiform, Desmoplastic.

*(J Bangladesh Coll Phys Surg 2017; 35: 61-67)*

mandible than in the maxilla and shows predilection for various parts of the mandible in different racial groups. The relative frequency of the mandible to maxilla is reported as varying from 80% -20% to 99%-1%<sup>5</sup>. Prevalence of the lesion is in between the 3<sup>rd</sup> and the 4<sup>th</sup> decade of life; Female to male ratio is about 1:1.7<sup>2</sup>.

Clinically ameloblastomas appear as aggressive odontogenic tumours often asymptomatic and slow growing with no evidence of swelling. It can even cause symptoms such as swelling, causing expansion of the cortical bone, perforation of the lingual and or buccal plates and infiltration of soft tissue; also can cause dental malocclusion, Pain and paresthesia of affected area<sup>6</sup>. Ameloblastomas are seldom found in maxilla, where their prognosis is much worse because of greater infiltration in trabecular bone in this anatomic location<sup>7</sup>.

Histologically ameloblastoma exhibits proliferating odontogenic epithelium within a background of fibrous stroma<sup>8</sup>. Numerous histological patterns can be seen in these lesions, such as; follicular, plexiform, acanthomatous, desmoplastic, basal cells and granular<sup>9</sup>.

The ameloblastoma is the most common of the odontogenic tumour exhibiting minimal inductive changes in connective tissues. It is true neoplasm, generally considered to be a benign with some peculiarities such as persistent local growth and its high loco regional invasion, non-capsulation and rarely metastasis<sup>10</sup>. It is an enigmatic tumour with a strong tendency to recur after treatment<sup>11,12,13</sup>. The recurrence rate may range from 15.9% to 20.6 %<sup>14</sup>. It is known that recurrences can take

- Dr. Sabrina Binte Rahman, Assistant Professor, Oral & Maxillofacial Surgery Dept., Dental Unit, Sir Salimullah Medical College, Mitford, Dhaka.
- Dr. S. M. Anwar Sadat, Assistant Professor, Oral & Maxillofacial Surgery Dept., Dental Unit, Shere-Bangla Medical College, Barisal.
- Prof. Dr. Ismat Ara Haider, Head, Dept of Oral and Maxillofacial Surgery, Dhaka Dental College Hospital, Dhaka
- Prof. Dr. Mohiuddin Ahmed, Principal, Sapporo Dental College Hospital, Dhaka.

**Address Correspondence:** Dr. S. M. Anwar Sadat, C7 Belinda, 116 Lake Circus Kalabagan, Dhaka, Mobile: +8801711156023, E-mail: an\_sadat@yahoo.com

**Received:** 6 February 2016      **Accepted:** 30 January 2017

longer than 20 years to become apparent and, therefore, the eventual recurrence rate may be higher<sup>15</sup>.

Recurrence in ameloblastoma is believed to be the result of several risk factors, notably tumour subtype, the clinico radiological appearance of the tumor, the anatomical site, treatment methods, and tumoral behavior<sup>12,16</sup>. It is generally accepted that the unicystic type exhibit less aggressive biologic behavior than the multicystic/solid type<sup>17</sup>. Follicular ameloblastoma are thought to be more aggressive in behavior than the plexiform type. In many studies it has been shown that follicular, granular, or acanthomatous growth pattern have a reportedly high likelihood of recurrence, whereas desmoplastic, plexiform, and cystic subtypes have a relatively low recurrence potential<sup>14</sup>. On the other hand some authors think that clinical behavior of ameloblastoma cannot be predicted from histological studies<sup>18</sup>.

Unfortunately, early literatures failed to distinguish the variants of the ameloblastoma, thereby eliminating any meaningful comments as to the efficacy of treatment for any of the variants of ameloblastoma. In fact, treatment and prognosis, including cure rates, are all dependent upon the variant of the ameloblastoma<sup>19</sup>. For this reason histological variants of ameloblastoma should be routinely find out in their morphological characterization.

Ameloblastoma is well recognized for its recurrence and often delayed to diagnose due to its slow growing nature. Due to this it is of great importance to clinicians and maxillofacial surgeons. In Bangladesh limited numbers of studies were conducted to observe the clinical and histological variations of Ameloblastoma and there are no series study and retrospective studies. The present study would analyze the histopathological subtypes & clinical presentations of ameloblastoma which would help for better understanding of the variability of this tumour and proper diagnosis of the lesion which eventually would contribute for appropriate management. The purpose of the study was to find out the relationship between clinical presentation and histological types of ameloblastoma to provide a base line data for better and appropriate patient management.

The purpose of the study was to find out the relationship between clinical presentation and histological types of ameloblastoma to provide a base line data for better and appropriate patient management.

#### **Patients and Methods:**

A cross sectional study on consecutive 50 histologically diagnosed Ameloblastoma patients attended to the department of Oral and Maxillofacial Surgery, Dhaka Dental College and Hospital from July 2011 to June 2012 were included in the study.

**Inclusion Criteria:** Patients histologically diagnosed as any type of Ameloblastoma of jaw were selected, Patient who have given consent were included in this study.

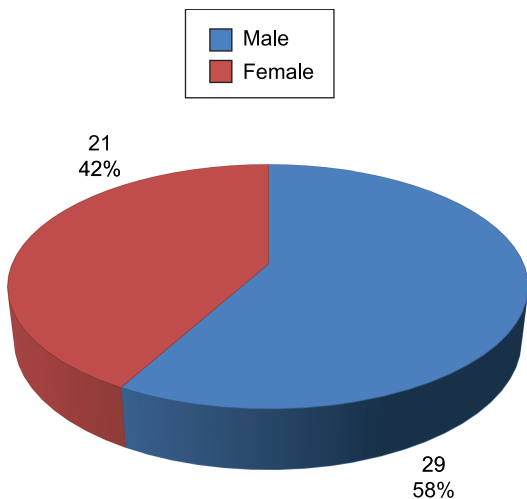
**Exclusion Criteria:** Patients who did not agreed to be included in this study, Patients whose clinical presentation was like ameloblastoma but histologically not confirmed, Psychotic/Unco-operative patient, Incomplete clinical data.

**Surgical procedure:** Under local anesthesia incisional biopsy was done. The surgical specimen was fixed in 10% formalin and sent for histopathological examination for histological typing.

**Ethical clearance:** All patients diagnosed as ameloblastoma reported at Oral and Maxillofacial Surgery Department of DDCH from July 2011 to June 2012 were included in this study. Since this is a cross sectional descriptive study, there was no physical risk of the patients throughout the study period. All patients had a case number to maintain their confidentiality. No information was withheld from the patient. An informed written consent was taken for every patient explaining the nature and objectives of the study. Finally ethical committee of Dhaka Dental College gave the ethical clearance for this study.

A summarized structured data collection sheet was used to collect necessary information of the subject group. Data were screened and cleaned for any discrepancy. After checking, cleaning, editing data were entered into template of SPSS@17 software. No specific formulation was applied due to small sample size. Descriptive statistics were generated first and then appropriate statistical tests were performed to find out association between different variables to establish baseline characteristics of the patient.

**Results:**



**Fig.-1:** Distribution of patients by sex (n=50)

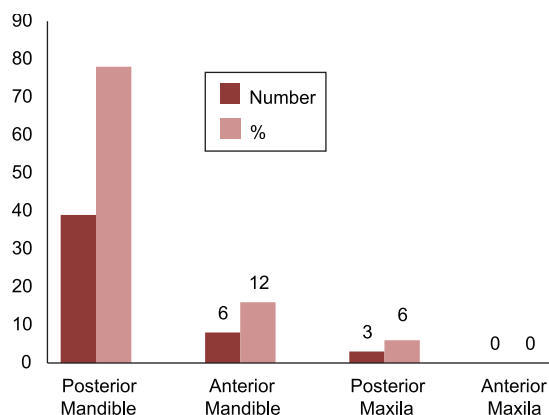
Figure shows that among the studied patients, 29 (58%) were male and 21 (42%) were female. It was found that male patients were higher than female patients. The male female ratio in the study is 1.4:1.

A total 50 patients of Ameloblastoma were studied with an age range of 10 to 50 years. Their mean ± SD age was 27.38± 11.74 years. 34% were between 11 to 20 years, 26 % were 21 to 30 years and 20% were 31 to 40 years age group. Most patients belonged to the second decade of life. The mean age of male patients were 28.5(±SD12.67) years, and female patients were 25.95(±SD10.56) years.

**Table-I**

Age distribution of the patients (n=50)		
Age in group	Frequency	Percent
Up to 10 years	3	6
11 to 20 years	17	34
21 to 30 years	13	26
31 to 40 years	10	20
41 to 50 years	7	14
<b>Total</b>	<b>50</b>	<b>100.0</b>

Fig.-2: Distribution of Patients by site of Ameloblastoma (n=50) Bar chart shows the distribution of Ameloblastoma patients in different sites. Of 50 patients 41 (82%) occurred in posterior mandible and 6 (12%) in anterior mandible. In this study no patient was found in anterior maxilla, in posterior maxilla it shows 3(6%). Mandible and Maxilla ratio was 15.6:1. Fig.-3: Clinical signs and symptoms (In percentage) of the patients: Figure reflects presenting



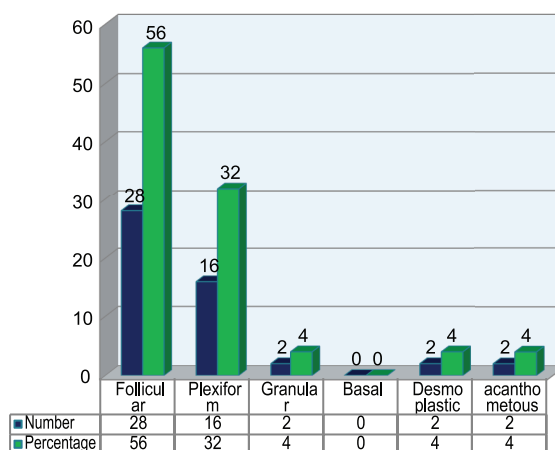
**Fig.-2:** Distribution of Patients by site of Ameloblastoma (n=50)

features of Ameloblastoma patients. Of all, 24 (48%) had complaints for swelling and 4(8%) didn't had swelling. 12(24%) patients had both pain and swelling, 2(4%) had paresthesia and 8(16%) had tooth mobility. It shows that swelling is the most common symptom that is 46(92%).

**Table-II**

Clinical types of Ameloblastoma		
Clinical type	N	%
Solid	31	62
Cystic	17	34
Desmoplastic	2	4

Table shows that the most frequent type was solid type(62%), second most common type was cystic type(34%). Desmoplastic type was only(4%) and no Peripheral variety was found.



**Fig.-3:** Histological type of Ameloblastoma: (n=50)

Plexiform type was found commonly in younger age group of patients than the follicular types. The mean age was 19.93 ( $\pm$ SD9.50) years in plexiform type and 28.89( $\pm$ SD11.101) years in follicular type. The P value was (0.003) which was statistically significant. (By Pearson Chi-Square test).

**Table-III***Histological types and age of the patient (n=50)*

Histological types	No of cases	Mean age (yrs)	Std. Deviation (yrs)
Follicular	28	28.8929	11.10669
Plexiform	16	19.9375	9.50417
Desmoplastic	2	37.0000	1.41421
Acanthomatous	2	42.5000	3.53553
Granular	2	41.0000	9.89949
Total	50	27.3800	11.74715

P=probability, SD=standard deviation.

The incidence was higher in male patients for follicular and plexiform type. In follicular variety male and female percentage was equal that is (50%) There was no male patient found for desmoplastic type and no female patient for Acanthomatous type. Granular type showed equal distribution. P value was 0.230 (not significant, by Pearson Chi-Square test).

**Table-IV***Histological types and sex of the patients (n=50)*

Histological type	Male	Female	P-value
Follicular	14 (50%)	14(50%)	
Plexiform	11(68.8%)	5(31.3%)	
Desmoplastic	0(.0%)	2 (100%)	0.230
Acanthomatous	2(100%)	0(.0%)	
Granular	1(50%)	1(50%)	

Table shows that swelling in follicular type were more in posterior mandible than anterior mandible (95.7%).No swelling follicular type was present in anterior maxilla. In posterior maxilla it was 2 (100%). Swelling in Plexiform types were also more in posterior mandible 14 (93.3%).Desmoplastic were exclusively present on anterior mandible 2 (100%).

Plexiform type was most common in the posterior mandible that is 15 (93.8%). Follicular type found 23(82.1%) in posterior mandible. In anterior mandible, Desmoplastic type was found highest in number that is 2(100%).There found no Granular and Plexiform variety in anterior mandible. In posterior maxilla follicular type was predominant 2 (7.1%). P value was (0.010) which was statistically significant. (By Pearson Chi-Square test).

**Table-V***Relationship of swelling in specific histological type and site (n=46)*

Histological type	Anterior mandible (N%)	Posterior mandible (N%)	Posterior maxilla (N%)	Total
Follicular	2 (66.7%)	22 (95.7%)	2 (100%)	26 (out of 28)
Plexiform	-	14 (93.3%)	1 (100%)	15 (out of 16)
Desmoplastic	2 (100%)	-	-	2 (out of 2)
Acanthomatous	1 (100%)	1 (100%)	-	2 (out of 2)
Granular	-	1 (50%)	-	1 (out of 2)

**Table-VI***Relation between histological type and site of Ameloblastoma:(n=50)*

Histological types	Anterior mandible	Posterior mandible	Posterior maxilla	P value
Follicular	3(10.7%)	23(82.1%)	2(7.1%)	0.010
Plexiform	0(0%)	15(93.8%)	1(6.3%)	
Desmoplastic	2(100%)	0(0%)	0(0%)	
Acanthomatous	1(50%)	1(50%)	0(0%)	
Granular	0(0%)	2(100%)	0(0%)	

**Table-VII***Relation between histological types and Clinical types of Ameloblastoma:(n=50)*

Histological types	Clinical types		P value
	Solid	Cystic	
Follicular	21(75%)	7(25%)	0.042
Plexiform	6(37.5%)	10(62.5%)	
Desmoplastic	2(100%)	0(0%)	
Acanthomatous	2(100%)	0(0%)	
Granular	2(100%)	0(0%)	

About (75%) of macroscopically solid type were related with histological follicular type, and (62.5%) of cystic type were histological plexiform type, P value (0.042) of which was statistically significant (By Pearson Chi-Square test).

#### **Discussion:**

As stated by Robinson, Ameloblastoma is usually unicentric nonfunctional, intermittent in growth, anatomically benign and clinically persistent<sup>20</sup>. Historically, Ameloblastoma has been recognized for over a century and a half. Its frequency, persistent local growth, and ability to produce marked deformity before leading to serious debilitation probably account for its early recognition. Recurrence, specially after conservative treatment, has also contributed to the awareness of this lesion<sup>21</sup>.

According to several studies Ameloblastoma occurs with equal frequency in men and women<sup>5,22,23</sup>. However an Indian (Podtar, 1969) and a Switzerland author (Farzad, 1999) showed a male preponderance as male / female ratio 1.7:1<sup>10</sup>. The present study found that Ameloblastoma occurred with higher incidence in male 58% (29 patients) than female 42% (21 patients). The male/female ratio was 1.4:1. Other studies showed that males were slightly higher than female<sup>14,25</sup>. Onguti MN (1997)<sup>26</sup> found female were higher in incidence than male. The findings of this study are similar to Molla MR<sup>24</sup> and Adekeye EO<sup>25</sup> but showed disparity with Onguti MN et al<sup>26</sup>.

The average age of patient's with intraosseous Ameloblastoma has been reported to be 39 years. This study revealed that the occurrence of Ameloblastoma in a significantly younger age group than has been used in previous studies. In this study Ameloblastoma were studied with an age range of 10 to 50 years. There mean

age was 27.38yrs ( $\pm$  SD11.7). Most of the patients belonged to the second to 3<sup>rd</sup> decades of life, a feature noted in Nigerian study<sup>27</sup>. It found that 34% were between 11 to 20 years, 26% were 21 to 30 years and 14% were 41 to 50 years age group. Ahmed M (1991) found that it is prevalent between 2<sup>nd</sup> to 4<sup>th</sup> decades of life. Haider IA (2004)<sup>28</sup> found that age distribution may vary widely from first to fifth decade of life and most commonly found in 21-30 years of age. i.e. In the 3<sup>rd</sup> decade. Sadat, Ahmed M et al (2005)<sup>10</sup> found that the age ranged from 19 years to 58 year, and peak age was in the 2<sup>nd</sup> and 3<sup>rd</sup> decades. The findings of the present study is closely to similar to, Sadat, Ahmed M et al<sup>10</sup>.

By the site of the lesion among the current studies showed that the 90% Ameloblastoma was occurred in mandible and 10% in maxilla. Molla MR et al (1991)<sup>24</sup> and Onguti MN et al (1997)<sup>26</sup> mentioned that about 80% of the tumours in the mandible. The molar and ramus area in the most frequently involved<sup>29</sup>. Haider IA (2004)<sup>28</sup> reported that most common sites of Ameloblastoma in mandible, (94.28%) involved the molar region. The present study showed that mandible is the most common site. About 41(82%) occurred in posterior mandible, of which body and ramus area was involved in 25(53.2%, like Japanese and Whites<sup>30</sup> but differ from Nigerian study where tumour have site predilection for the symphysis region in Africans<sup>25</sup>. Mandible/Maxilla ratio was 15.6:1 which is considerably similar to other authors<sup>24,26,28,29</sup>.

The present study found that 46(92%) had complaints of swelling and the 12 (24%) had both pain and swelling, 4(8%) didn't had swelling. Mehlich et al (1972)<sup>31</sup> reported that the presenting clinical signs and symptoms of the Ameloblastoma vary from patient to patient. The most common symptoms were swelling which occurred in 75% of the patients, followed by pain and swelling which was about 33%. Sadat, Ahmed M et al (2005)<sup>10</sup>

found swelling is the most common presenting feature 50% of Ameloblastoma, where swelling and pain are 29.16%. The findings of the present study showed that swelling is the common feature which is similar to other studies like Mehlisch<sup>31</sup>, Sadat<sup>10</sup>.

Clinically the present study found 62% was in solid, 32% were cystic, desmoplastic types were only 4% and there were no peripheral variety found. Sadat<sup>10</sup> found that solid type lesions were 66.67%, cystic type 25%. The findings of this study are considerably similar to Sadat et al<sup>10</sup>. In relation to histological findings, about 75% clinically solid types were associated with histological follicular type and 62.5% cystic types were histological plexiform type. (Here  $P=0.042$ ) which was statistically significant.

Histologically the present study showed that 26(56%) were found with follicular, 16(32%) plexiform type of ameloblastoma, desmoplastic, acanthotic and granular had 2(4%) in each. None of them had basal cell type. Waldron and EL-Mofty (1987)<sup>32</sup> identified as predominantly common patterns were follicular (64.9%), the plexiform were (16.9%). Haider IA (2004)<sup>28</sup> had found follicular types were more common 62.9% of cases than the plexiform type, which comprised 37.1% of cases. The findings of this study showed similar to Haider IA<sup>28</sup> and others.

This study showed that the relation of age with histological types was statistically significant ( $P=0.003$ ) Plexiform type was found commonly in younger age group of patients than the follicular types. The mean age was 19.93 ( $\pm$ SD9.50) years in plexiform type and 28.89 ( $\pm$ SD11.101) years in follicular type. Su-Gwan Kim et al (2001)<sup>33</sup> also showed similar relationship i.e.; they found that most teenaged patients had tumours with a plexiform pattern, whereas most patients in their twenties had tumors with a follicular pattern.

The number was higher in male patients for follicular and plexiform type. In follicular variety male and female percentage was equal that is (50%), desmoplastic type found exclusively in females 2 (100%). However other reports from Nigeria and elsewhere<sup>9,27</sup> showed equal gender distribution while a female predominance was reported in another series<sup>34</sup>.

Among 28 patients in follicular type, 26(92.9%) patient presented with swelling, of which 22(95.7%) were in posterior mandible. Posterior maxillary swelling was only follicular type 2 (100%) and no patient with swelling was presented with follicular type in anterior maxilla. In plexiform type most of the patients were presented with

swelling in posterior mandible 14 (93.3%). Plexiform type was not found in anterior mandible. Desmoplastic type was presented with swelling on anterior mandible only. This is not similar to usual presentation of desmoplastic variety which affects predominantly anterior maxilla<sup>35,36</sup>.

The present study reflected that Plexiform type was most common in the posterior mandible that is 15 (93.8%). Follicular type found 23(82.1%) in posterior mandible. In anterior mandible, Desmoplastic type was found highest in number that is 2(100%) This mandibular predilection of all the histological variants in this study agrees with several studies<sup>37</sup> with only 3 (two follicular, one plexiform) out of 50 cases occurring in posterior maxilla.

It was found that histologically follicular type is more associated with solid type, whereas plexiform type seems to be related with cystic type (determined by clinical and radiological findings). As it is evident from previous studies that the tendency of recurrence for solid type was more, hence it is indicative that follicular type also tends to be recurrent. Desmoplastic type is new variety of ameloblastoma in our country and its clinical picture is different than other countries. So to establish these features long term studies and follow-up is necessary. Furthermore for correct treatment option, the relationship of histological type with clinical presentation should be closely observed, so that appropriate management for ameloblastoma can be taken.

#### Conclusion:

In the department of Oral & Maxillofacial Surgery (Dhaka Dental College Hospital), accounts for 50 ameloblastoma patients, mostly present in posterior mandible (82%), with male predominance. Mostly people were affected in 2<sup>nd</sup> to 3<sup>rd</sup> decade with male/female ratio 1.4:1. About 75% clinically solid types were associated with histological follicular type and 62.5% cystic types were histological plexiform type. Plexiform type was found commonly in younger age group of patients than the follicular types. Desmoplastic ameloblastoma were found solely in anterior mandible.

#### References:

1. Masaaki, Kawamura, Nobuo, Inoue, Ichizo, Kobayashi, Ahmed M. Dredging Method-A New Approach for the Treatment of Ameloblastoma. Asian journal Oral Maxillofacial Surgery 1991: 3; 81-88.
2. Rastogi S, Nijhawan S, et al. Radiolucent-Radiopaque Lesion In The Mandible- A Nobel Diagnostic Approach. Journal of Clinical and diagnostic Research 2010:(4); 2300-2307.

3. Shafer WG, Hine MK, Levy BM, 1983. A textbook of oral pathology. 4th ed. Philadelphia: WB Saunders, 276-85.
4. Molla MR, Bhuiyan RA, Shaheed I, Shrestha P.A Review of Oral and Maxillofacial Service at Dhaka Dental College Hospital. Bangladesh Medical Journal 1991;20(2 and3);72-77.
5. Small LA, Waldron CA, 1955. Ameloblastoma of the jaws. Oral Surgery Oral Medicine Oral Pathology 1995; 8; 281-7.
6. Gungum S, Hosgoren B. Clinical and Radiographic Behavior of Ameloblastoma in 4 Cases. Journal Canadian Dental Association 2005; 71(7); 481-4.
7. Kahn. Ameloblastoma in young persons; a clinico pathological analysis and etiologic investigation. Oral surgery, Oral Medicine Oral pathology 1989; 67; 706-15.
8. Yazdi I, Seyedmajidi M, Foroughi R. Desmoplastic Ameloblastoma (a Hybrid Variant): Report of a Case and review of the Literatures. Archive Iranian Medicine 2009; 12(3); 304-308.
9. Adebisi KE, Ugboko VI, Omoniyi-esan GO, Ndukwe KC, Oginni FO. Clinicopathological analysis of histological variants of ameloblastoma in a Suburban Nigerian population. Head Face Medicine 2006; 2; 42.
10. Sadat SMA, Ahmed M, Hossain KA, Bhuiyan RA, Rita SN. Ameloblastoma of Jaws: A Clinico pathological Study of 24 cases. The Journal of Bangladesh Orthopedic Society 2005; 20; 29-33.
11. Olaitan AA, Arole G, Adekeye EO. Recurrent ameloblastoma of the jaws. A follow-up study. International Journal Oral Maxillofacial Surgery 1998; 27; 456.
12. Hong J, Yun PY, Chung IH, Myoung H, Suh JD, Seo BM, Lee JH, Cheung PH. Long term follow up on recurrence of 305 ameloblastoma cases. International Journal of Oral and Maxillofacial Surgery 2007; 36; 283-8.
13. Sammartino G, Zarrelli C, Urciuolo V et al. Effectiveness of a new decisional algorithm in managing mandibular ameloblastomas 10-years experience. British Journal Oral Maxillofacial Surgery 2007; 45; 306.
14. Reichart PA, Philipsen HP, Sonner S. Ameloblastoma: biological profile of 3677 cases. European Journal Cancer Board of Oral Oncology 1995; 31; 86 -99.
15. Eckardt AM, Kokemuller H, Flemming P et al. Recurrent ameloblastoma following osseous reconstruction—A review of twenty years. Journal of Craniomaxillofacial Surgery 2009; 37; 36.
16. Gardner DG, Heikinheimo K, Shear M, Philipsen HP, Coleman H, 2005. Ameloblastomas. In: BARNES L., et al and World Health Organization Classification of Tumors. Pathology & Genetics of Head and neck tumors. Lyon: IARC Press, 296-300.
17. Gardner DG. The treatment of ameloblastoma based on pathologic and anatomic principles. Cancer 1980; 46; 2514-9.
18. Shigeru U, Mushimoto K, Shirasu R. Prognostic evaluation of Ameloblastoma based on Histologic and Radiographic Typing. Journal Oral Maxillofacial Surgery 1989; 47; 11-16
19. Eric R. Carlson R, Marx E. The Ameloblastoma: Primary, Curative Surgical Management. Journal of Oral and Maxillofacial Surgery 2006; 64; 484-494.
20. Shafer, 2006. Cysts and tumors of odontogenic origin: textbook of oral pathology, 5th end. Elsevier Publication, 357-432.
21. Regezi JA, Sciubba JJ, 2009. Text book of Oral pathology: clinical-pathologic correlations. 5<sup>th</sup> addition, 261.
22. Robinson HBG. Ameloblastoma; a survey of three hundred and seventy nine cases from the literature. Archive Pathology 1937; 23; 831-843.
23. Daramola JO, Ajagbe HA, Oluwasanmi JO. Ameloblastoma of the jaws in Nigerian children: a review of 16 cases. Oral Surgery 1975; 40; 458-463.
24. Molla MR, Shaheed I, Shrestha. Ameloblastoma-A clinical study of 13 cases. Bangladesh Medical Research Council Bulletin 1991; 17(1); 29-36.
25. Adekeye EO. Ameloblastoma of the jaws: A survey of 109 Nigerian patients. Journal of Oral Surgery 1980; 38; 36-41.
26. Onguti MN, Cruchley AT, Howells GL, Williams DM. Ki-67 antigen in ameloblastomas: correlation with clinical and histological parameters in 64 cases from Kenya. International Journal Oral Maxillofacial Surgery 1997; 26; 376-379.
27. Mosadomi A. Odontogenic Tumours in an African Population. Analysis of twenty- nine cases seen over a 5 years period. Oral Surgery 1975; 40; 502-521.
28. Haider IA. Histological types of Ameloblastoma and their relationship with radiological findings. Thesis (MS) 2004. Dhaka Dental College and Hospital.
29. Tahoma KH. The pathogenesis of the odontogenic tumours. Oral Surgery 1961; 4; 1262.
30. Kramer IRH, 1963. Ameloblastoma: A clinicopathological appraisal. British Journal of Oral Surgery 1963; 1; 13 -28.
31. Mehlich DR, Dahlin DC, Mason JK. Ameloblastoma of jaws in Nigerian children: review of 16 cases. Oral Surgery 1972; 30; 9-22.
32. Waldron CA, Mofty EL. A Histopathological Study of 116 Ameloblastoma. Oral surgery Oral medicine Oral pathology 1987; 63; 441-451.
33. Kim S. Ameloblastoma: A clinical, radiographic, and histopathologic analysis of 71 cases. Oral Surgery Oral Pathology Oral Radiology Endodontic 2001; 91; 649-53.
34. Regezi JA, Kerr DA. Odontogenic tumors: analysis of 706 cases. Oral Surgery 1978; 36; 771-8.
35. Gardner DG, Heikinheimo K, Shear M, et al 2005. World Health Organization Classification of Tumours. Pathology and Genetics of Head and Neck Tumours. Lyon, International Agency for Research on Cancer, 296.
36. Beckley ML, Farhood V, Helfend LK, Alijanian A. Desmoplastic ameloblastoma of the mandible: a case report and review of the literature. Journal of Oral Maxillofacial Surgery 2002; 60(2); 194-8.
37. Ladeinde AL. Odontogenic tumors: A review of 319 cases in a Nigerian teaching hospital. Oral Surgery Oral Medicine Oral Pathology Oral Radiology Endodontic 2005; 99; 191-195.