

### A Young Male with Blurring of Vision

MD ROBED AMIN<sup>a</sup>, RAHAT ARA KHAN RUHEE<sup>b</sup>

(*J Bangladesh Coll Phys Surg 2019; 37: 46*)

DOI: <http://dx.doi.org/10.3329/jbcps.v37i1.39293>

Mr. X, a 24-year-old non-diabetic, normotensive man, hailing from Kaliganj presented in DMCH with the complaints of several episodes of vomiting for one day and blurring of vision for the same duration of time after ingestion of 180 mL (6 units) of vodka (ethyl alcohol) mixing with other agent on the previous night. The patient also complained of blurring of vision of his left eye which occurred suddenly, was painless, involving both eyes within a few hours. It progressed for the next 24 hours after which it started getting better. The patient admits to drinking alcohol every two to three months; however, is not a habitual drinker. These episodes involve binge drinking with smoking tobacco.

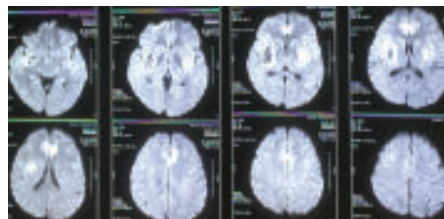
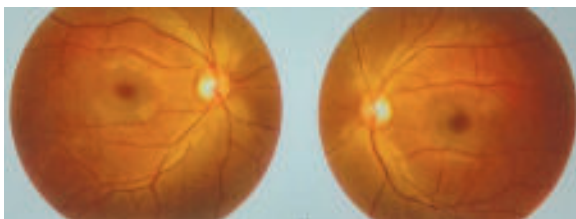
There was no history of trauma, orbital tenderness, quadrant or altitudinal hemianopia, dryness, grittiness, headache, facial pain, weakness, tinnitus or hearing difficulties. There was no hematemesis, melena, head trauma, headache, neck stiffness, altered mental status and the patient denied a history of migraine. His vomiting was not voluntarily induced and occurred spontaneously.

On examination, he was ataxic, incoherent speech. The patient admits to drinking alcohol every two to three months; however, is not a habitual drinker. These episodes involve binge drinking with smoking tobacco. Visual acuity was 6/60, field of vision is impaired peripherally, color vision was distorted,

Ophthalmoscopy revealed bilateral retinal whitening, flakes peripherally in all four quadrants. An MRI revealed hyperdensity in frontal and basal ganglion areas with haemorrhagic area in rt lentiform nucleus. Patient was diagnosed as Methanol poisoning with CNS and Eye toxicity.

The characteristic MRI findings in methanol toxicity are bilateral putaminal hyperdensity and Haemorrhagic manifestation as a result of necroses. This finding is although not specific to methanol toxicity but is commonly observed<sup>1</sup>. These findings are usually result from the direct toxic effects of methanol metabolites and metabolic acidosis in the basal ganglia<sup>2</sup>. Cerebral and intraventricular hemorrhage, cerebellar necrosis, diffuse cerebral edema, bilateral subcortical white matter necrosis or edema, and optic nerve necrosis all have been described in severe methanol intoxication,<sup>2,3</sup>. Optic nerve demyelination secondary to formic acid has been suggested as responsible for optic nerve damage with or without axonal loss.

1. Hsu HH, Chen CY, Chen FH, et al. Optic atrophy and cerebral infarcts caused by methanol intoxication: MRI. *Neuroradiology* 1997;39:192-94
2. Gaul HP, Wallace CJ, Auer RN, et al. MR findings in methanol intoxication. *AJNR Am J Neuroradiol* 1995;16:1783-86
3. Halavaara J, Valanne L, Setälä K. Neuroimaging supports the clinical diagnosis of methanol poisoning *Neuroradiology*, 2002;44:924-28



**Fig.-1:** (a) *Ophthalmoscopy after the treatment*, (b) *MRI showing methanol effect in Brain*

a. Dr. Md. Robed Amin, Associate Professor of Medicine, Dhaka Medical College

b. Dr. Rahat Ara Khan Ruhee, Honorary Medical Officer, Dpt of Medicine, Dhaka Medical College