

Device Closure of Ventricular Septal Defect with Amplatzer Muscular Occluder: A Case Report

NN FATEMA^a, M RAHMAN^b, M HAQUE^c

Summary:

A four year old girl was diagnosed as a case of mid muscular Ventricular Septal Defect (VSD) since early infancy. She had history of failure to thrive (FTT) and recurrent chest infection or pneumonia. As her pulmonary artery pressure was almost normal she was planned for device closure on elective basis once device

and technology would be available in cardiac centre of combined Military Hospital (CMH) Dhaka. Finally it was done on 21st August 2005 and patient was discharged after 72 hours observation period. Echocardiography on next morning showed complete occlusion of defect with no residual shunt.

(J Bangladesh Coll Phys Surg 2007; 25 : 161-163)

Introduction :

Ventricular Septal defect (VSD) is the most commonly encountered lesion reported in most cardiac centres¹. The incidence of VSD in all live birth is approximately 1.5 to 3.5 per 1000 term infants and 4.5 to 7 per thousands premature infants^{2,3}. The lower prevalence in adults with congenital heart disease is in large part due to spontaneous closure of many Defects^{2,3}. Surgical treatment of haemodynamically significant VSD's has long been established. Transcatheter closure of muscular ventricular septal defects was first attempted on a compassionate basis using the larger Rashkind occluding device⁴. Though device closure of Atrial Septal Defect(ASD) and Patents ductus arteriosus(PDA) has wide acceptance, transcatheter closure of VSD remains challenging and controversial⁵. It is being available in a small number of centres world wide. Cardiac centre of combined military hospital is a pioneer for all kinds of intervention in newborn and children and first ever case of VSD device closure in Bangladesh was done here with good result which led writing this report.

Case Report :

Miss T, a seven year old girl was diagnosed as a case of Ventricular Septal Defect (VSD), midmuscular type since early infancy. She had history of recurrent respiratory tract infection with failure to thrive. She had hospital admission with pneumonia several times in the past. She was on medical management and follow up evaluation with CXR, electrocardiography and echocardiography and colour doppler was repeated at 3 monthly interval. Her last follow up reports on July 2005 were as follows : ECG showed sinus rhythm with left ventricular forces, CXR showed mild cardiomegaly and echocardiography showed a 6 mm size midmuscular VSD with normal pulmonary artery pressure. As VSD size was not decreasing and patient was not gaining weight, she was planned for VSD device closure which was performed on 21st August 2005 on elective basis.

Equipments required

1. Muscular VSD device
2. VSD device delivery system with sheath.
3. Terumo exchange wire
4. Arterial and venous sheath
5. JR cathter
6. Pigtail cathter
7. Snare catheter
8. Echocardiography machine with TFE probe.
9. Standard paediatric drape .

Procedure : A 6F sheath was introduced in right Jugular vein, 5F sheath to right femoral vein and 4F sheath to left femoral vein and artery . A pigtail

a. Lt. Colonel Nurun Nahar Fatema, FCPS, Paediatric Cardiologist, Combined Military Hospital, Dhaka

b. Lt Col Mamunur Rahman, Cardiologist, Combined Military Hospital, Dhaka

c. Lt Col Mujubul Haque, Cardiac Anaesthesiologist, Combined Military Hospital, Dhaka

Address of Correspondence: Lt. Colonel Nurun Nahar Fatema , FCPS, Paediatric Cardiologist, Combined Military Hospital, Dhaka.

Received: 8 February, 2006

Accepted: 4 June, 2007

angiogram of left ventricle (LV) was performed to see the size of VSD. A JR 4 catheter was passed from RFA to LV and VSD was crossed with Terumo wire and JR catheter. Terumo wire was then placed to main pulmonary artery (MPA) and snared with a snare catheter passed through right Jugular vein to MPA. Terumo wire was then withdrawn through right Jugular vein with the help of snare. A long trans septal sheath of 7F size was then forwarded over terumo guide to RA to RV to LV. A VSD mid muscular device of 8x6 mm size was then loaded in the loader with the help of delivery cable. The loader was then attached to long sheath and cable forwarded through the sheath to LV. LV disc was released under TFE and fluoroscopy guide. Delivery cable was then withdrawn to RV along with sheath and RV disc was released. A pigtail angiogram of LV was done to confirm complete closure. Sheath and pigtail was then removed. Patient was heparinized during procedure and Inj. Cefuroxime 15 mg/kg body weight IV was given after deployment of device. Cefuroxime was repeated at 8 hourly interval for 24 hours. Echocardiography repeated on next morning showed no residual shunt. Patient was discharged 3 days after the procedure. Follow up appointment was given at 1, 3, 6, 9, 12, 18, 24, months and yearly thereafter.



Fig.-1. Miss T, first ever case of VSD device closure performed in Bangladesh.

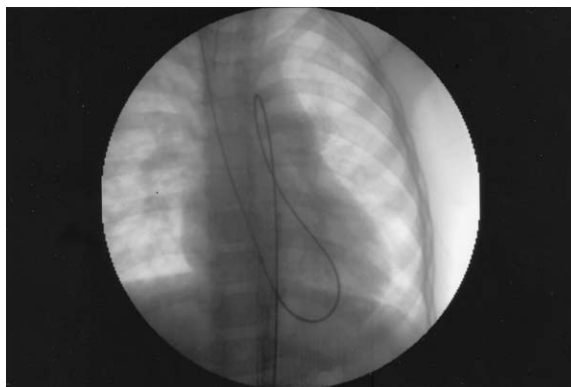


Fig.-2: Showing guide wire and catheter which travelled through the heart from right jugular vein to right femoral artery.

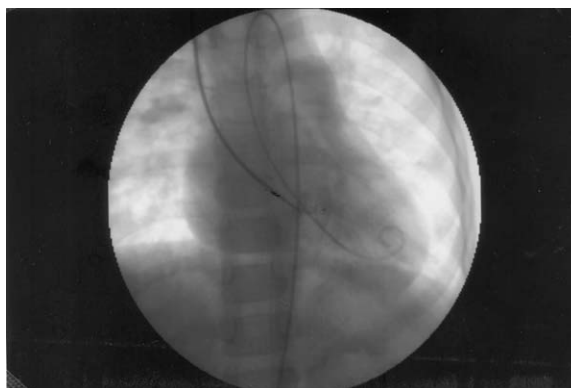


Fig.-3: Showing VSD device attached to delivery cable.

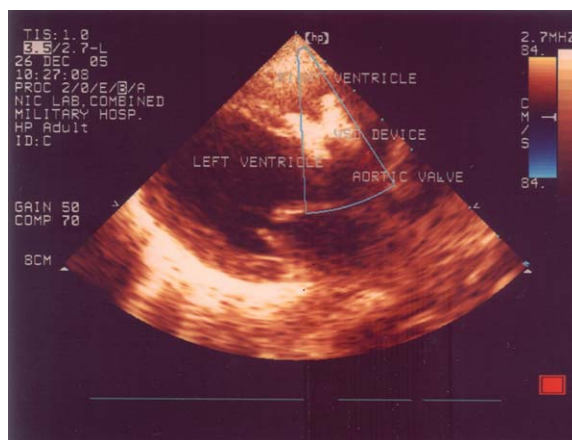


Fig.-4: Chest X-ray showing VSD device in position.

Discussion :

The earliest interventional procedure to be applied in the catheterization laboratory was balloon atrial septostomy⁶. Shortly thereafter, non surgical closure of a PDA was achieved and within ten years ASD had

been closed successfully with catheter device in animals⁷. Non surgical closure of VSD is much less well accepted and can only be regarded as an option for very selected cases, and available only in a few centres worldwide. The procedure for VSD was first attempted by lock et al in 1988 and devices originally designed for the closure of other intracardiac defects (Rashkind umbrella device, lock clamshell, cordioseal, coils, Sideris buttoned devices etc.)⁸ were used with a variable success rate and residual shunt. Recently Amplatzer VSD Occluder and Sideris device are in use. The Amplatzer VSD occluder (muscular) has been undergoing clinical trial since 1988 after the animal experiments had shown 100% occlusion and complete endothelialization at 3 months⁸. In our case we used Amplatzer muscular VSD occluder. No residual shunt was noticed after implantation.

To evaluate the feasibility, safety and efficacy of transcatheter closure of VSD, many studies were conducted. A study conducted on dog in Azabu university, Japan using coils for perimembranous VSD showed minimal residual shunting after implantation⁹. Another study conducted on ten patient with Amplatzer muscular occluder in Sao Paulo, Brazil proved this device feasible, safe and effective¹⁰. Immediate and intermediate term follow up was analyzed in many studies and transcatheter closure of VSD was proved effective in selected cases of VSD'S^{11,12,13,14}.

Now a days intraoperative device closure of muscular VSD'S are practiced by surgeons¹⁵. Infants requiring operative Interventions with muscular VSD'S are difficult to manage and have an increased mortality and morbidity.

In some centres hydride procedures are practiced where the heart is exposed surgically to puncture directly and then intervention is performed. The opening in the ventricular wall then closed surgically¹⁵.

Intraoperative VSD device placement could avoid ventriculotomy, division of intracardiac muscle bands, and is ideal for the neonate or infant.

Reference :

1. Thomas P.G MD, Howerd P.G MD. Ventricular Septal Defects in : GC Emmanouilides, Hugh D Allen, Thomas A. Riemenschneider, Howard P. Gutgesell (editors). Moss and Adams Heart disease in infant children and adolescents, 5th edition. Baltimore : william and wilkins, 1995. PP 724-746.
2. Hoffman JLE, Rudolph AM. The natural history of Ventricular septal defects in infancy. Am J cardiol 1965 ; 16: 634-653.
3. Moe DG, Guntheroth WG. Spontaneous closure of uncomplicated ventricular septal defect. Am J cardiol 1987 ; 60: 674-678.
4. Sommer RJ, Golinko RJ, Ritter SB. Intracardiac shunting in children with ventricular septal defect : evaluation with doppler colour flow mapping. J Am coll cardiol 1990 ; 16 : 1687-1695.
5. Wilkinson JL. Interventional pediatric cardiology : device closures. Indian J pediatri 2000 ; 67 : 507-513.
6. Rashkind WJ, miller WW. Creation of an atrial septal defect without thoracotomy : a palliative approach to complete transposition of the great arteries. J Amer Med Assoc 1966; 196: 991-992.
7. King TD, Mill NI. Nonoperative closure of atrial septal defects. Surgery 1974 ; 75: 383-388.
8. Arora R, Trehan V, thakur AK, Mehta V, Sengupta PP, Nigam M. Transcatheter closure of muscular ventricular Septal defect. J interv cardiol 2004 ;17 109-15.
9. Fujii Y, Fukuda T, Machida N, Xamane T, Wakao Y. Trans catheter closure of congenital ventricular septal defects in 3 dogs with a detachable coil. J vet intern Med 2004 ; 18 : 911-4.
10. Pedra CA, pedra SR, Esteves CA, Pontes SC Jr, Braga SL, Arrieta SR et al. Percutaneous closure of perimembranous ventricular septal defects with the Amplatzer device : technical and morphological considerations. Catheter cardiovasc interv 2004 ; 61 : 403-10.
11. Holzer R, Balzer D, Amin Z, Ruiz CE, Feinstein J, BASS J et al. Transcatheter closure of postinfarction ventricular septal defects using the new Amplatzer muscular VSD Occluder : Results of a US Registry. Catheter cardiovasc interv 2004 ; 61 : 196-201.
12. Holzer R, Belzer D, Cao QL, Lock K, Hijaji ZM. Device closure of muscular ventricular septal defects using the Amplatzer muscular ventricular Septal defect occluder : Immediate and mid-term results of a US registry. J Am col cardiol 2004; 43 : 1257-63.
13. Kalra GS, Verma Pk, Dhall A, Sigh S, Arora R. Transcatheter device closure of ventricular septal defects : Immediate results and intermediate term follow up. Am Heart J 1999 ; 138 : 339-44.
14. Durongpisitkul K, Soongswang J, Laohaprasitiporn D, Nana A, Nutakul T. Transcatheter closure of perimebranous ventricular septal defect with immediate follow-up. J Med Assoc thai 2003 ; 86 : 911-7.
15. Okubr M, Benson LN, Nykanen D, Azakie A, Van Arsdell G, coles J, Willians WG. Outcomes of intraoperative device closure of muscular ventericular septal defects. Ann thoracic surg 2001 ; 72 : 416 – 23.
16. Pewelec WM, Antosik P, wasiatycz G, wojtalik M. Use of muscular VSD Amplatzer occluder for closing right ventricular free wall perforation after hybrid procedure. Eur J cardiothorac surg 2004 ; 26 : 1044 – 6.