

## CASE REPORTS

# Pneumatosis Cystoides Intestinalis - A Case Report

MAK PRAMANIK<sup>a</sup>, SMKN BEGUM<sup>b</sup>, AM RASHID<sup>c</sup>, M KALIMUDDIN<sup>d</sup>,  
M SHAHABUDDIN<sup>e</sup>, MN HASAN<sup>f</sup>

### Summary:

*Pneumatosis Cystoides Intestinalis is a rare condition characterised by gas-filled cysts in the wall of the small-gut and sometimes in its mesentery. When the process is limited to the large intestine, the term pneumatosis coli is used<sup>1</sup>. The exact cause of the condition is unknown but it may develop in diseases like peptic ulcer, ulcerative colitis, regional enteritis, chronic bronchitis etc<sup>2</sup>. The condition is usually diagnosed incidentally during abdominal scanning or investigation for the primary disease. Presentation as a case of gastric outlet obstruction (proximal jejunal obstruction) as happened in this case, is*

### Introduction:

Pneumatosis Cystoides Intestinalis may be primary (Idiopathic) or secondary to conditions like peptic ulcer, ulcerative colitis, regional enteritis, diverticulitis etc<sup>2</sup>. Impaired pulmonary functions (who are less able to excrete excessive hydrogen gas through lungs) can be a contributing factor. It is believed that air enters into the wall of gut through a breach in mucosa, as would occur in the case of a duodenal ulcer and the air is driven onwards by

*rare. A young adult male cultivator presented as a case of gastric outlet obstruction due to suspected chronic duodenal ulcer ( a common complication of Peptic ulcer disease in our country ). Per-operatively, gas filled cysts in proximal jejunum with almost obliteration of the lumen of the intestine was detected and diagnosed as a case of pneumatosis cystoides intestinalis and was treated with resection and anastomosis of the affected portion of gut. The patient is in good health even 5 years after the operation and showed no signs of recurrence of the condition.*

*(J Bangladesh Coll Phys Surg 2009; 27: 45-48)*

peristalsis. The cysts which may be obvious on plain radiograph and are usually symptomless<sup>3</sup>. The patient may seek advice for his primary disease in most cases but may also present with features of sub-acute or chronic intestinal obstruction<sup>4</sup>. At its initial stage, the condition can be treated with hyperbaric O<sub>2</sub> inhalation. If a large number of cysts occlude the lumen of the intestine, resection of the affected portion of intestine is necessary.

### Case Report:

A 35 year old young man with thin body-built from Gopalganj district was brought by a general physician, working in an Non Govt. Organization (NGO).

The patient was a poor cultivator from a remote rural area. He was complaining of pain in the upper abdomen for about 4 years. Initially the pain was mild and was felt in empty stomach and was relieved after taking antacids and H<sub>2</sub>-blockers. The abdominal pain increased in severity since about 2 years and drugs like H<sub>2</sub>-blockers and antacids were of no value. Since about 1 year, he noticed distension of upper abdomen along with pain after food intake and sometimes he used to vomit and get relief. If he fails to vomit voluntarily, he introduces his right index and middle fingers into his throat to induce vomiting, to get relief of the intolerable abdominal pain. He vomits ½ to 1

- Dr. Md. Abul Kasem Pramanik, Associate Professor of Surgery, North Bengal Medical College, Sirajganj.
- Dr. S.M. Khodeza Nahar Begum, Consultant Pathologist, Xylia Medicare, Laxmipur, Rajshahi.
- Dr. Ali Mohammad Rashid, Junior Consultant, Deptt. of Anaesthesia, Rajshahi Medical College Hospital.
- Dr. Md. Kalimuddin, Registrar, surgical unit, North Bengal Medical College, Sirajganj.
- Dr. Md. Shahabuddin, Medical officer, Bangladesh Clinic, Rajshahi.
- Dr. Md. Nazmul Hasan, Medical officer, Bangladesh Clinic, Rajshahi.

**Address of correspondence :** Dr. Md. Abul Kasem Pramanik, Associate Professor of Surgery, North Bengal Medical College, 'Bangladesh Clinic'. 358/2, Housing Estate, Upo-shahar, Rajshahi-6000. Bangladesh, Phone no. : 0721-761559. Cell phone no. : 0171 504 1989.

**Received:** 22 February, 2007 **Accepted:** 23 November, 2008

hour after intake of solid food and sometimes after taking semi-solid or even after liquid meals since last 6 months and gradually became cachectic. The vomited material contained undigested or partially digested food eaten 2 to 3 days earlier, with offensive smell. He never had haematemesis. His bowel habit was once or twice daily with mucous in stools but never had melaena. The patient was a heavy smoker and used to smoke 10 to 15 biri or low priced cigarettes in a day. He used to cough occasionally with white mucus expectoration but never had haemoptysis. He was treated as a case of chronic duodenal ulcer by a physician for the last 6 months but without improvement

On examination, the patient was cachectic. He was not anaemic, not jaundiced and not cyanosed. His vital signs were within normal limit. Chest showed no deformity. Heart and lungs were normal. Liver and spleen were not palpable. Distension of upper abdomen was noticed and was more pronounced after water intake and visible peristalsis from epigastrium to downwards were noticed. On percusso-auscultation, the stomach was enormously dilated. Succussion splash was positive. There was no palpable abdominal mass.

His TcDc, Hb%, Urine examination, x-ray chest and E.C.G. were done from a Medical College Hospital and all were normal. Ba-meal examination was also done from the same institute showed hugely dilated stomach with Barium-streaked food particles inside.

Ultrasonography of whole abdomen, done from a private clinic, reported that his stomach was hugely dilated with shadows of food particles inside (without any mention about the cysts). All other abdominal and pelvic organs were normal.

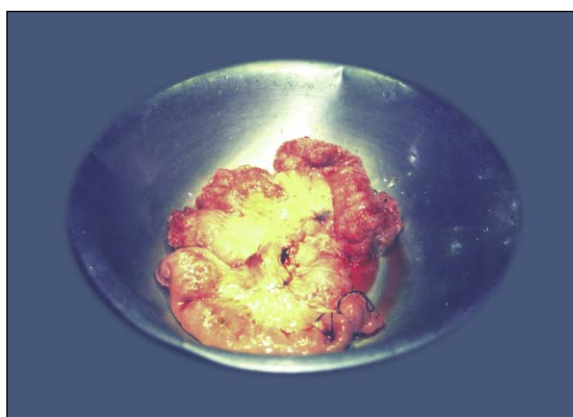The patient was diagnosed as a case of gastric outlet obstruction due to chronic duodenal ulcer. Being a poor man and on the assumption that the diagnosis was already made, endoscopy was not done. Finally, the case was diagnosed as gastric outlet obstruction due to chronic duodenal ulcer and a decision was taken for vagotomy and gastro-jejunostomy after confirmation of fitness for general anaesthesia by the anaesthetist. Laparotomy was done through upper midline incision which was later extended downwards encircling right side of umbilicus.

Neither any ulcer-scar nor any tumour was detected in stomach or duodenum. Pyloric canal was normal. The

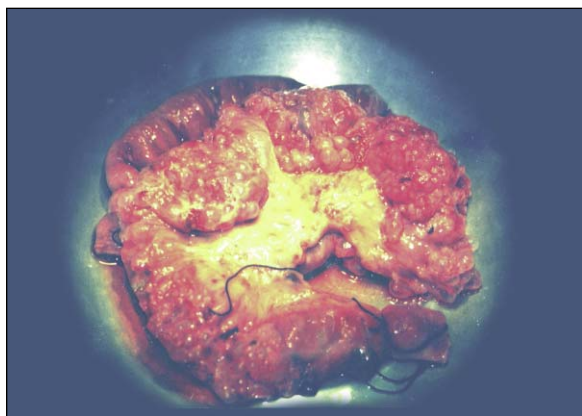stomach was hugely dilated.

Large number of small cysts were found in the wall of proximal jejunum and its mesentery, sparing about 8 inches from duodeno-jejunal flexure and extending distally for about 2 feet from the starting point. The spared portion of jejunum, proximal to the cyst bearing portion was distended. The size of the cysts were ranging from few mm. to some cm. in diameter and were numerous and on pricking no fluid but only air was found inside. The lumen of the gut was almost occluded by cluster of cysts at two sites. All other abdominal and pelvic organs were normal. So, per-operatively, it was diagnosed as a case of sub-acute upper jejunal obstruction due to cluster of cysts and a decision was taken for resection of the affected portion of gut.

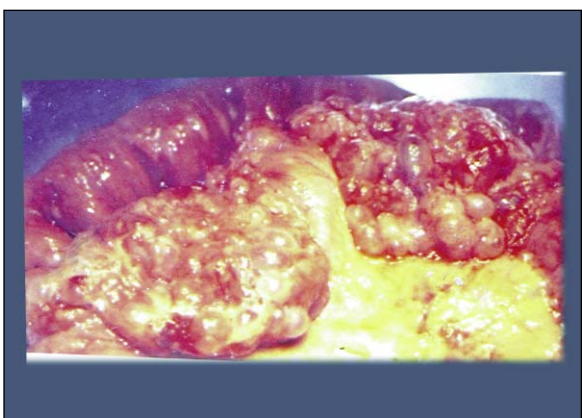
About 2 feet of the involved portion of proximal jejunum was resected and continuity restored with end to end anastomosis. The cysts on the resected portion of gut were not communicating with the intestinal lumen and with each other. A drainage tube was placed at the site of anastomosis and wound closed in layers after proper haemostasis. The drainage tube was removed on 3<sup>rd</sup> post-operative day. The patient was allowed to eat and drink, starting on 4<sup>th</sup> post-operative day, with liquid diet and gradually semi-solid and finally with solid food. There was neither vomiting nor abdominal distension. The wound healed normally and skin sutures were removed on 8<sup>th</sup> post-operative day and the patient was discharged from the clinic on 10<sup>th</sup> post-operative day.



**Fig.-1:** Resected portion of jejunum with pneumatic cysts.



**Fig.-2:** Resected portion of jejunum with pneumatic cysts.



**Fig.-3:** Close view of part of photo 2 showing the cysts clearly.

The histopathology report of the resected portion of jejunum showed sub-serosal as well as sub-mucosal cysts lined by flattened epithelium with granulomatous changes in stroma and infiltration by foreign body giant cells<sup>5</sup>

The patient is in good health even 5 years after the operation with no abdominal complaints. He can perform strenuous works including ploughing and rowing now.

#### Discussion :

Pneumatosis cystoides intestinalis, defined as gas in the bowel wall, is often first identified on abdominal radiographs or CT scans. It is a radiographic finding and not a diagnosis, as the aetiology varies from benign conditions to fulminant gastro-intestinal disease like necrotising enterocolitis in children<sup>6</sup>.

About 15% of cases of intestinal air cysts are primary ( i.e. idiopathic) and about 85% of cases are secondary to conditions like gastric or duodenal ulcers, enterocolitis, respiratory disease like bronchial asthma and chronic bronchitis, connective tissue disorders, coeliac disease, leukaemia, organ transplantation, amyloidosis, steroid therapy and in AIDS. Jejunio-ileal by-pass for obesity was found responsible in one series.

The condition can be explained :

- I. On the mechanical basis in association with -
  - (a) intestinal obstruction with mucosal ulceration .
  - (b) mucosal trauma from biopsy, endoscopy etc.
  - (c) respiratory disease with severe cough which raises intra-abdominal as well as intraluminal pressure of intestines and forces air to enter into the wall of the intestine<sup>7</sup> .
- II. On the basis of increased gas production as occurs in enterocolitis .
- III. On the basis of decreased gas excretion in chronic obstructive pulmonary diseases like Chronic bronchitis, bronchial asthma and pulmonary emphysema. Rupture of the pulmonary blebs may lead to air dissecting through the retroperitoneum into the mesentery and finally to the subserosa and submucosa<sup>8</sup> .
- IV. On the basis of increased mucosal permeability as occurs in steroid and immunosuppressant therapy.

In this case, gastric outlet obstruction was due to proximal jejunal partial obstruction, occurred by the gas filled clusters of cysts. No gastric or duodenal ulcer was detected. The patient was a heavy smoker having chronic cough but showed no signs of chronic obstructive pulmonary disease clinically and radiologically. So, it was a case of primary pneumatosis cystoides intestinalis with partial proximal jejunal obstruction but was wrongly diagnosed as a case of gastric outlet obstruction due to chronic duodenal ulcer. But possibility of secondary pneumatosis cystoides intestinalis due to duodenal ulcer with smoker's cough can not be excluded.

The presence of gaseous cysts was not noticed by the sonologist partly because of unawareness about the

condition and partly due to the presence of hugely dilated stomach with food particles inside <sup>9</sup>. CT-scan was not done considering its cost, lack of its easy availability at that time, and on assumption that a correct diagnosis was already made.

The type of gaseous content of the cysts could not be determined due to lack of facility. The follow-up of the patient could not be done at regular intervals due to lack of understanding its importance by the illiterate patient and inadequate postal service with a remote rural area of our country.

#### Conclusion:

Pneumatosis Cystoides Intestinalis is usually diagnosed incidentally during abdominal scanning for the primary disease or for some other abdominal diseases. In its early stage, the condition can be treated with hyperbaric oxygen inhalation along with treatment of the primary disease. The condition rarely presents as a case of gastric outlet obstruction or intestinal obstruction. If the air-filled cysts cause intestinal obstruction, resection of involved portion of gut and end to end anastomosis gives excellent result. The primary disease also needs adequate treatment.

#### References :

1. Doherty, Gerard M. & Way, Laurence W.. Current Surgical Diagnosis & Treatment. Small Intestine. Gas cysts (Pneumatosis Cystoides Intestinalis) : 2006; 29 : 681.
2. Neil J. McC. Mortensen and Oliver Jones : The small and large intestines. Pneumatosis Cystoides Intestinalis. In : Russel, R.C.G., Williams, N.S. and Bulstrode, C.J.K. Bailey & Loves's Short Practice of Surgery. International Students' edition, 24th.edition : 2004; 68: P-1182.
3. Lumbley, John S.P. Hamilton Bailey's Physical Signs, International Students edition Non acute abdominal conditions. Pneumatosis Intestinalis : 2001; 23: 293.
4. Juan Rossi : Gastro-intestinal tract. Pneumatosis Cystoides Intestinalis. In: Ackerman's Surgical Pathology, 6th. edition, vol-1. C.V. Mosby Company New York :1981; 10: P-542.
5. Robert E. Petras : Non-neoplastic Intestinal diseases. Pneumatosis Cystoides Intestinalis. In: Stephen S. Sternberg. Diagnostic Surgical Pathology.: 1989; 30: P-1004.
6. Robert J.C. Steele: Disorder of colon and rectum. Pneumatosis Coli. In: A Cuschieri, G.R.Giles and A.R. Moosa. Essentials of surgical practice. 4th. edition, Part-1: 2002; 714: P-614.
7. Gerald Fine & Chan K. Ma : Alimentary tract. Pneumatosis Cystoides Intestinalis . In Kissane John M.. Anderson's Pathology, 1990; 24: PP 1155-56.
8. Sameer K Goyal, MD, Post Graduate Instructor, Staff Physician, Department of Radiology, Nassau University Medical Center.
9. P. Kumar & M. Clark: Gastro-enterology. Pneumatosis Cystoides Intestinalis. In: Clinical Medicine. W.B Saunders: 1998; 4: P-271
10. Dvorah Balsam, MD, Chief, Division of Pediatric Radiology, Nassau University Medical Center; Professor, Department of Clinical Radiology, State University of New York at Stony Brook. Updated, Sep 21, 2007.
11. P.Kumar & M.Clark . Clinical Medicine: Pneumatosis Cystoides Intestinalis : 1998: 4: 271.