

## Laryngo-Tracheal Scleroma- A Case Report

BH SIDDIQUEE<sup>a</sup>, PG DATTA<sup>b</sup>, MS ALAM<sup>c</sup>, AK DEY<sup>c</sup>

### Summary:

*Scleroma is a granulomatous condition of the nose and other parts of the respiratory tract, usually primarily affects the nose and the nasopharynx (Rhinoscleroma). But rarely they also occur in the larynx (secondary to rhinoscleroma or primary laryngeal affection). This is endemic in Eastern Europe, North Africa, Southern Asia and Central America. In Bangladesh this is almost*

### Introduction:

Scleroma is a granulomatous condition of the nose, nasopharynx and other parts of the respiratory tract. This is an infectious disease having chronic but slowly progressive clinical course. The disease was first presented by Von Hebra<sup>1</sup>. Johann Von Mikulicz described the histologic features in 1877<sup>2</sup>, and Von Frisch identified the organism in 1882<sup>3</sup>. This is a bacterial disease caused by *K. rhinoscleromatis* (Frisch bacilli), that's why the disease is often called as Mikulicz disease and the culprit bacilli is known as Frisch bacilli. It is endemic in Eastern Europe, Northern Africa, Southern Asia and Central America<sup>4</sup>. Rhinoscleroma spreads in the environment by means of direct inhalation of droplets or contaminated materials. The disease probably begins in areas of epithelial transition such as the vestibule of the nose, the sub glottic area of larynx and the area between the naso and oropharynx. Because of slow progression and low degree of clinical suspicion (because of rarity), proper diagnosis is usually

*clinically unknown but theoretically possible. Presented case of laryngo-tracheal scleroma is possibly the first ever reported one from Bangladesh. The main presentation of this patient was laryngeal obstruction simulating malignancy and finally demanded tracheostomy. Only post surgical histopathology report could reveal the diagnosis.*

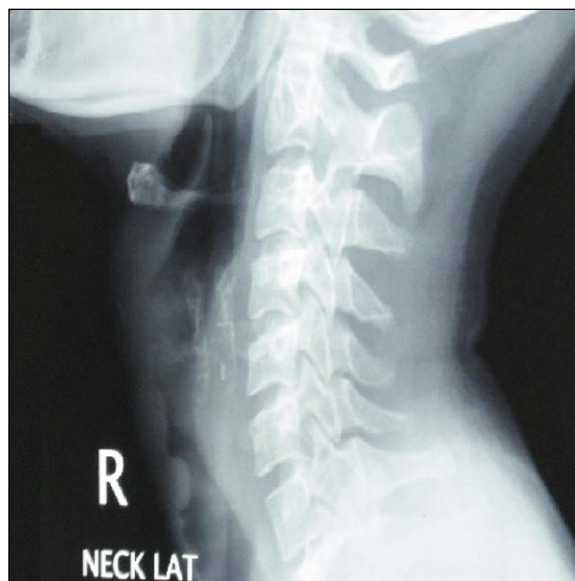
**Key words:** Scleroma, Laryngeal scleroma.

(*J Bangladesh Coll Phys Surg 2009; 27: 49-51*)

delayed. The airway obstruction is usually mild but in neglected and advanced cases may be severe necessitating surgical intervention like tracheostomy. Review of available literature shows that, this case is possibly the first ever identified one of laryngo-tracheal scleroma in Bangladesh.

### Case Report:

A male patient of about 25 years had attended the head & neck clinic of Bangabandhu Sheikh Mujib Medical University Dhaka in early November 2006 with a history of change of voice for 4 months and mild but increasing dyspnoea for 2 months. While he was engaged in doing some investigations in subsequent few days as outdoor patient he suddenly



**Fig.-1:** Preoperative X-ray soft tissue Neck lateral view showing involvement of laryngeal cartilage & upper part of anterior wall of trachea

a. Dr. Belayat Hossain Siddiquee FCPS, Associate Professor, Department of Otolaryngology-Head & Neck Surgery, Bangabandhu Sheikh Mujib Medical University, Dhaka.

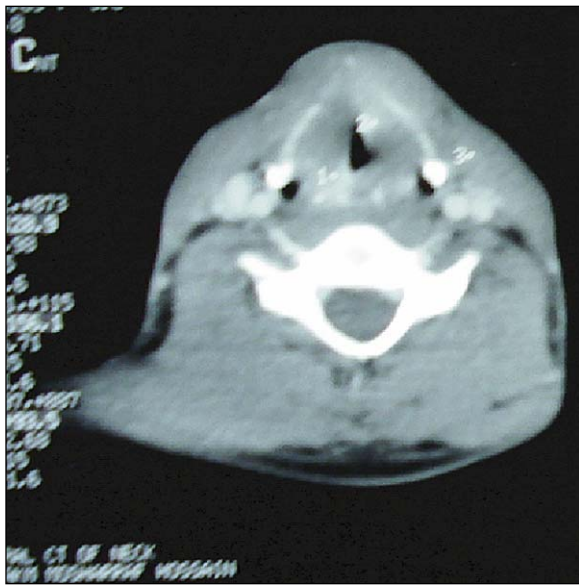b. Dr. Pran Gopal Datta PhD, Professor, Department of Otolaryngology-Head & Neck Surgery, Bangabandhu Sheikh Mujib Medical University, Dhaka.

c. Dr. Md. Sahbub Alam FCPS, Dr. Ashok Kumar Dey MBBS, MS Student, Department of Otolaryngology-Head & Neck Surgery, Bangabandhu Sheikh Mujib Medical University, Dhaka.

**Address of Correspondence:** Dr. Belayat Hossain Siddiquee, Associate Professor, Department of otolaryngology-Head & Neck Surgery, Block-C, 6th Floor, Room No. 704, BSMMU, Shahbag, Dhaka, Phone: 01911356805(M), 8612550-4 Ext. 4304 (Office), Fax: 880-2-9663251, Email: orlsb@bdcom.com

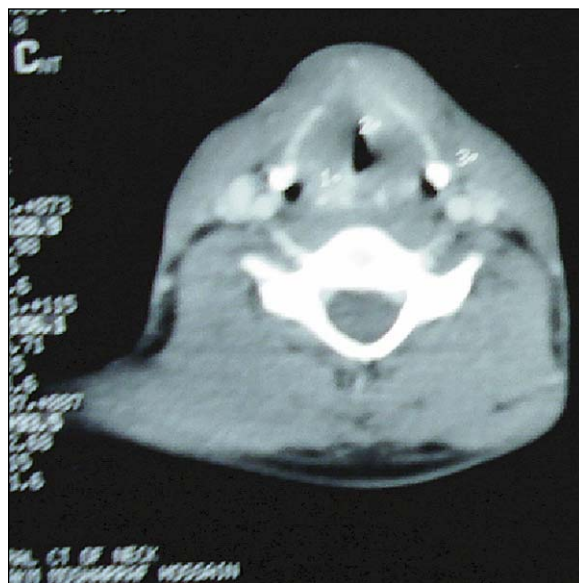
**Received:** 25 March, 2007

**Accepted:** 20 August 2008



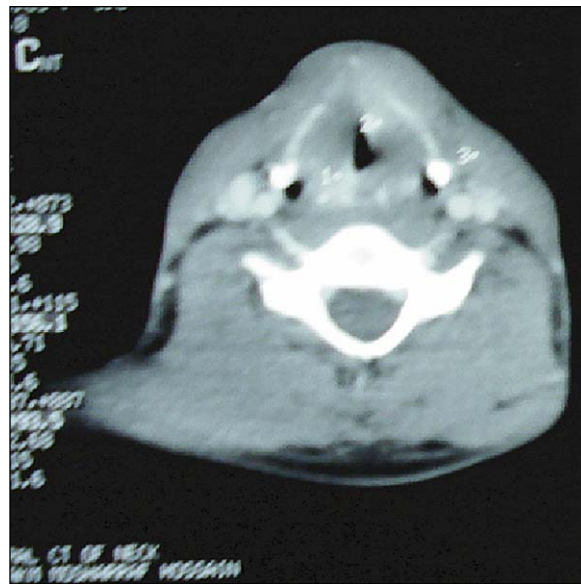
**Fig.-2:** CT Scan of Neck showing abnormal soft tissue in the larynx distorting the Left Vocal Cord.

developed severe respiratory distress and underwent tracheostomy on 10/11/06 in Dhaka Medical College Hospital emergency. In next visit to head and neck clinic his X-ray soft tissue neck lateral view revealed increased pre-vertebral soft tissue shadow distorting the laryngeal frame work and another soft tissue shadow involving the upper anterior tracheal wall. CT scan showed swelling of the arytenoids (left > right)



**Fig.-3:** Photomicrograph showing features of scleroma (Indicator showing Foam Cell).

with distortion and swelling of the glottic region (Left). X-ray chest was normal. The nose and nasopharynx were absolutely normal revealed by traditional and fiber optic endoscopic examination. Direct laryngoscopy revealed moderate swelling of both the arytenoids region and slight inward bulging with distortion of the left glottic area. Inner mucosa was intact. The swelling of the anterior wall of the trachea was hardly visualized because of the narrowing of the glottic chink and this was also smooth lined. As the prevertebral soft tissue shadow was prominent and persistent, the neck was explored on 20/11/06 by a transverse neck incision and approached the prevertebral region from left side crossing the mid line but nothing abnormal could be detected in the bony and soft tissue structures. By a longitudinal incision we entered the hypopharynx (Pharyngotomy) but this was also frustrating i.e. no abnormality could be detected. After elevating the skin flap over the larynx the cartilages were found to be thickened and irregular, finally decided to do the laryngofissure. On incision over the laryngeal cartilage by a surgical blade this was found brittle, unhealthy, has lost its normal texture. Some changes were also evident in the cricoid cartilage. The upper tracheal swelling was removed by lucas forceps and pieces of tissue were also taken from the cartilaginous and sub mucosal region of the thyroid cartilage. Both



**Fig.-4:** Post-operative X-ray soft tissue Neck Lateral view showing Laryngeal stent & tracheostomy tube in situ.

the specimens were sent for histopathological examination. Larynx was closed keeping a stent inside for 6 weeks.

### Discussion:

Scleroma of larynx and/or trachea although mentioned in the literature, it is almost unknown in our clinical practice. Although his symptoms were simulating malignancy, multiple areas of involvement (pre vertebral soft tissue, laryngeal and tracheal) directed us to shift our attention to inflammatory disease of the larynx and trachea. But the diagnosis was not evident till the histopathology reports were available.

The disease process usually starts as rhinoscleroma and progress downwards to involve the larynx and trachea <sup>5, 6</sup>. Interestingly in our case nose and nasopharynx were healthy.

Primary laryngeal Scleroma is extremely rare <sup>7</sup>. As the nose and nasopharynx were totally symptom free and no crust or atrophic change were present, our case can be categorized as primary laryngeal Scleroma. The incidence of laryngeal Scleroma varies from 12% to 14% <sup>8</sup>. In presented patient both the larynx and upper trachea were involved. The lesion occurs most often in the subglottic region where the character of the mucosa changes from squamous epithelium to columnar epithelium.

There are numerous methods of diagnosing scleroma, such as the examination of a culture from the affected area, histopathologic study with special stains from the biopsy specimen, and serologic and immunochemical studies. Culture studies are diagnostic, but the limitation is that only 60% of the biopsy proven cases were positive for *K. rhinoscleromatis*<sup>13</sup>. Complement fixation tests and agglutination tests can be used, but they are diagnostic only when the Warthin-Starry stain displays numerous bacilli in the cytoplasm. The electron micrograph of the Mikulicz cells shows several vacuoles and *Klebsiella rhinoscleromatis*<sup>14</sup>.

Histopathologic determination of the scleroma is by far the most accurate and the most widely used method of diagnosis. The presence of Mikulicz cells, Russell bodies, plasma cells, lymphocytes, and gram-negative bacilli showing slimy mucopolysaccharide coating are not pathognomonic, but characteristic of the scleroma.

Treatment for scleroma must be intense and prolonged. Bactericidal antibiotics specially Rifampicin, Streptomycin and Tetracyclin are useful.

Some times local application of 2% solution of acriflavine produced a complete cure of disease in all its stages after 8 weeks.

Chemotherapy may be combined with surgery to re-establish the airway without causing further atrophic changes. In late cases where the disease has been eradicated plastic reconstructive surgery may be required<sup>15</sup>.

### Conclusion:

Scleroma, although very rare, is a known clinical entity affecting nose and other part of the respiratory tract. Manifestation of laryngeal scleroma may simulate malignancy. High degree of suspicion on the part of the histopathologist and clinician may help to establish the diagnosis of laryngeal scleroma.

### References:

1. Von Hebra F. Ueber Ein Eigen Thuemliches Neugebiule An der Nase. Wien Med Wochnschr 1870; 20: 1 (Cited from Ref. 14).
2. Mikulicz J. Ueber das Rhinoscleroma. Arch F Klin Chir 1877; 10: 485-534 (Cited from Ref. 14).
3. Von Frisch A. Zur aetiologic des Rhinosclerom. Wien Med Wochneschr 1882; 32: 969-72 (Cited from Ref. 14).
4. Han JH, Kim JM, Kim IS, Paik SY. Rhinosleroma -A case report-. Korean J Pathol 1990; 24: 166-70.
5. Shum TK, Whitker CW, Meyer PR. Clinical update on rhinoscleoma. Laryngoscope 1982; 92: 1149-55.
6. Amoils CP, Shindo ML. Laryngotracheal manifestations of rhinoscleroma. Ann Otol Rhinol Laryngol 1996; 105: 336-40.
7. Barr JG. Klebsiella. Taxonomy, and communication. J Clin Pathol 1977; 30: 943-4.
8. Amoils CP, Shindo ML. Laryngotracheal manifestations of rhinoscleroma. Ann Otol Rhinol Laryngol 1996; 105: 336-40.
9. Afaro-Monge JM, Fernandez-Espinosa J. Scleroma of lower respiratory tract: case report and review of the literature. J Laryngol Otol 1994; 108: 161-3.
10. Soni NK. Scleroma of the larynx. J Laryngol Otol 1997; 438-40.
11. Kamal AAEH. Scleroma of the larynx and associated squamous cell carcinoma. Ann Otol Rhinol Laryngol 2000; 109: 306-10.
12. Hara AJ. Scleroma. Laryngoscope 1957; 67: 695-708.
13. Ssali CLK. The Management of Rhinoscleroma. J Laryngol Otol 1975; 89: 91-9.
14. Hun – Soo kim, Seok-won Park, Jin-Man kim. Scleroma of larynx – A case report, the Korean journal of pathology. 2003; 37: 287-90.
15. W.N. Weir and D G Golding-wood, Infective rhinitis and sinusitis, Scott Brown's Otolaryngology 6th ed. Ian S. Machy and T R Bull, Butter worth-Heinmann 1997, p- 4/8/35.