

Laparoscopic Management of Benign Adnexal Masses

F BEGUM^a, JH BHUIYAN^b, JALI^c

Abstract:

Introduction: Laparoscopy has now become the gold standard method for management of a wide range of gynecological ailments including adnexal masses. Laparoscopic surgery has been associated with shorter operating time, shorter duration of hospital-stay, early recovery and significant patient satisfaction. Using most modern image system like 3D-4K & advanced bipolar system like Ligasure, handling difficult procedure becomes easier & operating time becomes further shorter. The present study is conducted to evaluate the effectiveness & safety of laparoscopy in the management of adnexal masses & to find out the superiority of 3D-4K image technology over 2D-4K regarding operating time & handling difficult procedures.

Method: The study period was of 36 months, from January 2017 to December 2019 in a laparoscopy surgery based private hospital, Cumilla, Bangladesh. During this period, 42

patients underwent laparoscopy for various benign adnexal masses. Cases were critically analyzed & results are presented.

Results: Most of the patients were from the age group of 20 to 30 years. Most common indication was serous cyst adenoma (48%). Most common surgical procedure performed was ovarian cystectomy (43%). Average operating time was less in 3D-4K image technology than 2D-4K. Conversion rate was nil in this study. No major complication observed. Minor port site infection found only in 2 cases.

Conclusion: Laparoscopic surgery reduces hospital stay, there is less adverse effect, early recovery and better quality of life on surgical treatment of benign adnexal masses.

Keywords: Adnexal mass, Ovarian cystectomy, Laparoscopy, 2D (Two dimensional), 3D (Three dimensional).

(J Bangladesh Coll Phys Surg 2022; 40: 111-115)
DOI: <https://doi.org/10.3329/jbcps.v40i2.58693>

Introduction:

Most ovarian abnormalities can be managed laparoscopically. First laparoscopic salpingo-oophorectomy was performed by Semm in 1984.¹ Over years, laparoscopy has evolved from a limited gynecologic surgical procedure used for diagnosis & tubal ligation to a major surgical tool used for management of a variety of gynecological conditions. Laparoscopy has now become the gold standard method for the management of a wide range of gynecological ailments, including adnexal masses.² Due to its well-known advantages such as the

perioperative morbidity, hospital stay & recovery time, laparoscopy has been used with increasing frequency in the management of benign adnexal masses over the last 10 years.^{3,4,5} The few prospective studies comparing this technique with the classical laparotomy have shown that it should replace open surgery in the treatment of benign adnexal masses.⁶ Laparoscopic surgery has been associated with shorter operating time, shorter duration of hospital stay, early recovery and significant patient satisfaction. Using most modern image system like 3D(TIPCAM®1 S 3D KARL STORZ-ENDOSKOPE)& advanced bipolar system like Ligasure, handling difficult procedure becomes easier & operating time becomes further shorter. The present study was conducted to evaluate the effectiveness & safety of laparoscopy in the management of adnexal masses & to find out the superiority of 3D-4K image technology over 2D-4K regarding operating time & handling difficult procedures.

Methods:

This prospective study took place in a laparoscopy surgery based private hospital, Cumilla, Bangladesh between January 2017 to December 2019. During this

- Dr. Farhana Begum, Senior Consultant, Gynae, Cumilla Medical College Hospital, Cumilla
- Dr. Md. Jahangir Hossan Bhuiyan, Associate Professor, Department of Surgery, Cumilla Medical College, Cumilla
- Dr. Dr. Md. Jamshad Ali, Jr. Consultant, Dept. Of Anaesthesia, General Hospital, Cumilla

Address of Correspondence: Dr. Farhana Begum, Senior Consultant, Gynae, Surgicare Hospital (Laparoscopy Hospital), Tahsin Garden, 396/2, Shishumongol Road, Kandirpar, Cumilla, Bangladesh. Mobile: +8801718548567

e-mail: farhanarpmc21@gmail.com

Received: 04 June 2020

Accepted: 08 March 2022

period 42 patients underwent laparoscopy for various types of adnexal masses. All patients were operated on elective basis. Detailed history, a thorough general physical examination was done in all patients. Inclusion criteria were per abdominal & trans vaginal ultrasound findings suggesting benign ovarian masses, gynecological examination without findings which would suggest malignancy & preoperative normal tumor marker CA-125(normal range 0-35 mU/ml) in some cases. The cyst with maximum diameter more than 12 cm measured by ultrasonography, obese patients & patients having H/O laparotomy also included. Exclusion criteria were known contraindications for laparoscopy such as ultrasonographic evidence of malignancy, medical reason & high preoperative CA-125 level. The patients were prepared for laparoscopic surgery under general anesthesia. Proper counseling & informed written was taken. Preoperative findings were noted. Patient were placed in supine position & general anesthesia given. Catheterization was done. Pneumoperitoneum was created through supraumbilical 10 mm port. First of all diagnostic laparoscopy done after introduction of 10 mm telescope. Two other 5 mm ports placed under direct laparoscopic visualization at the right & left lower quadrant following baseball diamond concept. The patients were repositioned &

maintained in a 30⁰ trendelenburg position. 2D image system used in 30 patients & 3D image system used in 12 patients. Reduction of the cysts size done by aspiration of contents. Dissection was carried out with hook, scissors & ligasure advanced bipolar system. Difficult procedures like residual tumor, chocolate cysts etc were well managed using three dimensional(3D) image system & ligasure advanced bipolar system. Associated recurrent appendicitis were present 12 cases & cholelithiasis with chronic cholecystitis were present in 4 cases. Laparoscopic appendectomy performed using same ports & for laparoscopic cholecystectomy 2 extra 5mm ports were needed. Operating time for these associated procedures were not included in this study. Specimen were placed in endobag, divided into pieces with scissors where necessary & removed through supraumbilical 10 mm port using 5 mm laparoscope in the right 5mm ancillary port. Most of the specimen sent for histopathological examination. 10 mm port closed using port closure technique. Assessment of indications, intraoperative findings & various interventions done during the procedure were carefully analyzed. The patients were kept nil by mouth for 12 to 24 hours depending on the condition & discharged on 3rd postoperative day. All the cases were followed up after 1wk, 4wk & 8wk.

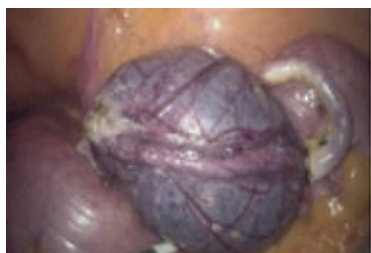

Fig.-1: Paraovarian cyst & appendix

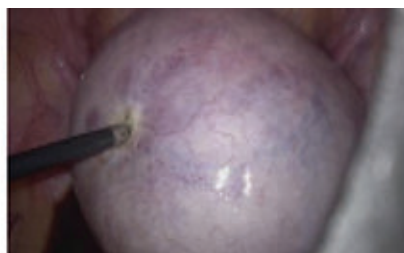


Fig.-2: Dermoid cyst

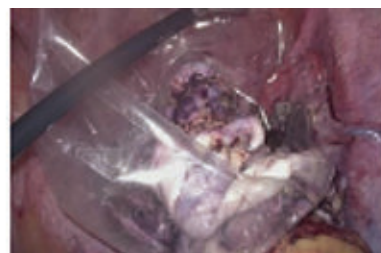

Fig.-3: Endobag containing dermoid cyst

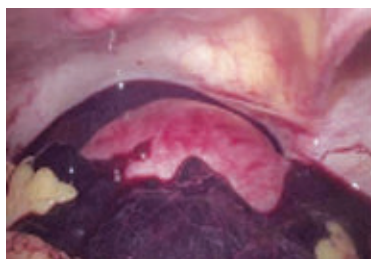


Fig.-4: Ectopic pregnancy

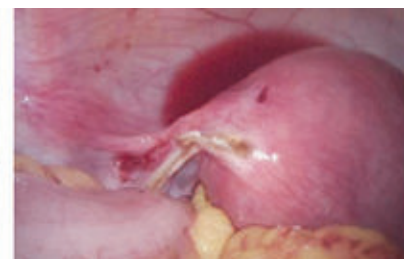

Fig.-5: After salpingectomy



Fig.-6: 3D & 2D camera(Personal set-up)

Results:

42 patients were enrolled in this study who met the inclusion criteria. Age distribution of the study was 14-70 years. Maximum patients were from the age group 21-30 years. The average operating time using 2D-4K image technology was 60 mints & 3D-4K technology was 50 mints. Intraoperative blood loss was almost nil in maximum cases except in residual cyst & chocolate cyst where average blood loss was 100 ml. The average hospital stay was 2 days. Conversion rate was nil in our study.

Table-I

<i>Indication of operations</i>		
Types of adnexal masses	No. of cases	Percentage
Serous cyst adenoma	20	48
Chocolate cyst	06	14
Functional cyst (Follicular/ Corpus luteal)	03	07
Dermoid cyst	03	07
Ruptured ectopic pregnancy	03	07
Twisted ovarian tumor	02	05
Benign giant ovarian tumor	02	05
Residual ovarian tumor	02	05
Paraovarian tumor	01	02
Associated pathology		
Recurrent appendicitis	12	
Cholelithiasis with chronic cholecystitis	04	

The most common indication in this study was serous cyst adenoma (48%) followed by chocolate cyst (14%). Functional cyst, dermoid cyst & ruptured ectopic pregnancy were 07% respectively. 05% cases were twisted ovarian with signs of gangrene, 05% benign giant ovarian tumor & 05% residual ovarian tumor with dense adhesions. There was only one case of paraovarian cyst (Table 1). Associated pathology was recurrent appendicitis 12(29%) & cholelithiasis with chronic cholecystitis were 04(10%) (Table 1).

The most common surgery carried out in this series was ovarian cystectomy (39%) followed by salpingo oophorectomy (22%). We were able to do excision of 4 cases of chocolate cyst (09%) & deroofting with fulgeration of 2 cases (4%) with our latest technology 3D-4K image system & advanced bipolar ligasure system. Dense adhesions were found in endometriotic & residual ovarian tumor. Adhesiolysis (17%) done using latest technology & that is why no conversion were needed. Excision of ectopic pregnancy (Salpingectomy) done in 03(07%) cases & excision of paraovarian cyst done in 1(02%) case.

30(71%) cases were performed using 2D-4K image system & 12(29%) cases using 3D-4K image system in our series (Chart 1). Average time consumed using 2D-4K image system was 60 mints & 3D-4K image system 50 mints. We experienced less mental work load,

Table-II

<i>Type of operation performed</i>		
Procedure proper	No. of procedure	Percentage
Ovarian cystectomy	18	39
Salpingo-oophorectomy	10	22
Adhesiolysis	08	17
Excision of chocolate cysts	04	09
Aspiration,deroofting & fulgeration of endometriotic(chocolate) lesion	02	04
Excision of ectopic pregnancy (Salpingectomy) with abdominal toileting	03	07
Excision paraovarian cyst	01	02
Associated procedures		
Laparoscopic appendicectomy	12	
Laparoscopic cholecystectomy	04	

Table-III

<i>Postoperative complications</i>		
Types of complications	No. of cases	Outcomes
Minor port site infection	02(5%)	Dressing on OPD basis & antibiotics
Recurrence of the chocolate cyst	01(2%)	Revision laparoscopic procedure

increased personal felt safety & task efficiency during procedures using 3D-4K image system.

There were no major complications observed in the study. Minor port site infection was found in 02(5%) cases managed by regular dressing & recurrence of the chocolate cyst found in 1(2%) case that led revision laparoscopy.

Discussion:

Benign adnexal masses consist of common issues which the gynecologist has to treat. Laparotomy considered to be the indicated treatment method until endoscopic methods has been developed years ago. Since this time the continual development of laparoscopy allowed us today to accept endoscopy as a safe & effective alternative to laparotomy. In our study maximum patients were between age 21-30 yrs & mean age was 31 yrs. In a comparable

study of Bhattacharjee S et al, the age range was 26-30 yrs.⁷ Another comparable study of Duggal BS et al, the mean age was 33 yrs.⁸ Thus it is concluded that maximum study dealt with benign adnexal masses in younger age group.

The average operating time in our study was 60 mints using 2D-4K image technology & 50 mints using 3D-4K technology. In a study conducted by Bhattacharjee S et al, the operating time was 75 mints.⁷ Another study conducted by Duggal BS et al, the operating time was 70 mints.⁸ This is to be mentioned here that with the use of latest image technology & advanced bipolar system the operating time further reduced in our study. The intraoperative blood loss was almost nil in maximum cases except chocolate cyst & residual ovarian tumor where it was average 100 ml in the present study. The average intraoperative blood loss was 130 ml in a study done by Bhattacharjee S et al⁷ & 155 ml in a study done by Duggal BS et al.⁸ Uses of ligasure vessel sealer in our study

causes significant reduction the intraoperative blood loss. Conversion rate was nil in our study. 3.1% of cases needed conversion in the study done by Bhattacharjee S et al.⁷ This was significantly high (19%) in the study of Serur E et al⁹ & 8% in the study of Grammatikakis I et al.⁸ Conversion rate was nil in our study because of stringent selection of cases, exclusion of malignant cases & use of latest image technology & advanced bipolar system.

The most common indications in our study was serous cyst adenoma (48%) followed by chocolate cyst(14%). It is comparable to the study of Duggal BS et al.⁸ Serur E et al also found most common pathology serous cyst adenoma.⁹ This is due to the fact that serous cyst adenoma is the most common benign tumor of the ovaries. The most common surgical procedure performed in our series was ovarian cystectomy (43%) followed by salpingo oophorectomy(24%), excision of chocolate cyst (10%), excision of ectopic pregnancy (Salpingectomy)(7%), excision of paraovarian cyst (2%), Adhesiolysis (19%) & ovarian drilling (10%). Most common procedure was ovarian cystectomy (41.2%) in the study of Duggal BS et al.⁸ Ovarian cystectomy is the method of choice in young patients to preserve fertility. Present study conducted mostly on young females & that is why this procedure was preferentially done in most of the patients. Associated operative procedures in our study were laparoscopic appendicectomy in 12 cases & cholecystectomy in 4 (10%). It was possible because of advanced laparoscopic surgeon in the team & advanced technological support like 3D-4K image system available in our hospital. No major complications observed in our study. Minor port site infection found in 5% cases, treated by dressing & antibiotics on OPD basis. Recurrence of chocolate cyst found in 1 case for which revision laparoscopic procedure done. 5% complication

was seen in the study of BhattacharjeeSetal⁷, 10% in the study of Serur E et al.⁹Complications rate was minimum in our series because of careful selection of cases, strict maintenance of sterilization protocol & laparoscopic surgery based single center study.

Since January 2017 3D/2D-4K image laparoscopy is the primary modality in our center. 3D-4K image system has got 4 times resolution of full HD, superior depth perception, greater image definition & more realistic & life like view. 29% cases performed using 3D-4K image system & 71 % using 2D-4K image system in this series. Average time consumed using 2D-4K image system was 60 mints & 3D-4K image system 50 mints. Mental work load also less using 3D-4K system in our series. Gomez-Gomez E et al also experienced less time & mental work load using 3D-4K technology in their study of laparoscopic surgery.¹¹ We also experienced increased personal felt safety& task efficiency using most modern image technology which is correlate with the study done by Buia A et al.¹²Due to superior depth perception, greater image definition & improved task efficiency in 3D-4K image system in our study operating time was less & conversion rate was nil.

Conclusion:

The laparoscopic approach is effective & safe in managing patients with adnexal masses of varied pathology. Laparoscopy has to be considered the first choice for benign adnexal masses due to its better panoramic vision, shorter operating time, shorter stay in hospital, minimum postoperative complications, early recovery & significant patient satisfaction. Proper selection of cases, laparoscopic surgery-based hospital, good quality image system, advanced bipolar system & expert laparoscopic surgical team are imperative for good patient outcome.

Acknowledgement:

The author would like to thank the patients, hospital authority & ot staff for their continuous active support & co operation during the study period.

Conflict of interest: Nothing to declare

References:

1. Mishra RK. Textbook of Practical Laparoscopic Surgery. 3rd edition. Jaypee. 2013. chapter 29, P-359.
2. Zaman S, Majid S, Hussain M, Chughtai O, Mahboob J, Chughtai S. A retrospective study of ovarian tumors & tumor like lesions. J Ayub Med Coll Abbottabad 2010 Jan-Mar;22(1):104-8.
3. Canis M, Pouly JL, Wattiez A, Mage G, Namhes H, Bruhat MA. Laparoscopic management of adnexal masses suspicious at ultrasound. Obstet Gynecol1997;89:679-683.
4. Hidlebaugh DA, Vulgaropulos S, Orr RK. Treating adnexal masses. J Reprod Med 1997;42:551-558. 5. Canis M, Rabischong B et al. Laparoscopic management of adnexal masses: a gold standard? Curr Opin Obstet Gynecol 2002; 14:423-428.
6. Yuen PM, Yu KM, Yip SK, Lau WC, Rogers MS, and Chang A. A randomized prospective study of laparoscopy and laparotomy in the management of benign ovarian masses. Am J Obstet Gynecol 1997; 177:109-114. 7. Bhattacharjee S, Sharma S. Laparoscopic management of adnexal masses: a hospital-based study. Int J Reprod Contracept Obstet Gynecol2018; 7:1427-1430.
8. Duggal BS, Tarneja P, Sharma RK, Rath SK, Wadhwa RD. Laparoscopic management of adnexal masses. Med J Armed Forces India2004 Jan; 60(1):28-30.
9. Serur E, Emeny PL, Byrne DW. Laparoscopic management of adnexal masses. JSLS 2001 April. 5(2);143-151. 10. Grammatikakis I, Trompoukis P, Zervoudis S, Mavrelis C, Economides P, Tziortzioti V et al. Laparoscopic treatment of 1522 adnexal masses: An 8-year experience. Diagnos Therapeu Endosc 2015;2015. 11. Gomez-Gomez E, Corrasco-Valiente J et al. Impact of 3D vision on mental workload and laparoscopic performance in inexperienced subjects. Actas Urol Esp 2015 May; 39(4):229-35.
12. Buia A, Stockhausen F. 2D vs 3D imaging in laparoscopic surgery-results of a prospective randomized trial. Langenbechs Arch Surg 2017 Dec; 402(8);1241-1253.