

# Aicardi-Goutieres Syndrome-A Case Report

NOOR-A-SABAH LIZA<sup>a</sup>, SK SERJINA ANWAR<sup>b</sup>, GOPEN KUMAR KUNDU<sup>c</sup>

## Abstract:

*Aicardi Goutieres Syndrome is an early-onset leukoencephalopathy with a presumed immune pathogenesis caused by inherited defects in nucleic acid metabolism. It is an inflammatory disorder resulting from mutation of multiple genes. Majority of the affected individuals experience physical as well as intellectual disability. Here we discuss a case of A 2-year old girl of consanguineous marriage*

*diagnosed as Aicardi Goutieres Syndrome who was presented with the sudden loss of motor and cognitive skills after an acute febrile illness. This syndrome was diagnosed by clinical exome sequencing and RNAEH 2A mutant gene identification.*

*(J Bangladesh Coll Phys Surg 2022; 40: 132-135)*

*DOI: <https://doi.org/10.3329/jbcps.v40i2.58697>*

## Introduction:

Aicardi-Goutieres Syndrome (AGS) is an early onset neurodevelopmental disorder.<sup>1</sup> It has an autosomal-recessive Mendelian inheritance pattern and its origin is derived from the mutations that undergo the different genes encoding the RNAses, in charge of degrading intracellular RNA chains<sup>2</sup>. Mutations in these genes result in the cytoplasmic accumulation of nucleic acids, which acts as an error signal of ongoing viral infection and initiates type I IFN production and that is responsible for AGS. This condition generally suffer from progressive microcephaly associated with severe neurological symptoms, such as hypotonia, dystonia, seizures, severe developmental delay and spastic quadriplegia<sup>3,4</sup>.

Aicardi-Goutieres Syndrome can be of two types on the basis of onset: early and late onset form. Early onset is very severe and affects 20 percent of the infants. These infants are born with liver (elevated liver enzymes and enlargement of the liver and spleen) and neurological abnormalities. But infant with later-onset, begin their symptoms after first few weeks or months of normal

development, which projects as muscle spasticity, decline in head growth, developmental and cognitive delays. The risk to siblings are only less than 1%<sup>5</sup>.

Diagnosis of AGS minimally suggested by intracranial calcifications with abnormal CNS white matter and no infectious explanations and /or CSF findings of leukocytes, pterins or interferon alpha. Molecular confirmation of mutations in TREX1, SAMHD1, and RNaseH2A,B and C gene is helpful. Effective treatment have not yet been developed. Supportive and symptomatic treatment should be given<sup>6</sup>.

## Case Report:

A 2-year old female child of consanguineous marriage parents was presented with loss of her acquired developmental milestone for last 1 year. She was developmentally normal up to 1 year of age, then she developed regression of all milestone of development after acute febrile illness. Now she could stand by holding objects and could speak 10 to 12 words. Mother also noticed that her child cried excessively following this events. There was history of fever prior to this illness which was high grade continuous in nature. The child was delivered by normal vaginal delivery with no perinatal and postnatal complication. There was no history of convulsion, unconsciousness, breathing problem, vomiting, abnormal body and urine odour, hearing and visual problem. On examination she was conscious, oriented and vitally stable. Nervous system examination reveals increased tone in all four limbs, exaggerated deep tendon reflexes (Biceps, knee, ankle) and bilateral planter extensor. There was no sign of meningeal irritation. Her biochemical report shows serum amonia-57 micro mole / L, Lactic acid 4.74 mg/dl. EEG report was normal. Brain MRI T1 weighted image showed

a. Noor-A-Sabah Liza, Department of Paediatric Neurology, Bangabandhu Sheikh Mujib Medical University.

b. Sk Serjina Anwar, .....

c. Gopen Kumar Kundu .....

**Address of Correspondence:** Dr Noor-A-Sabah liza, Consultant (Paediatrics), FCPS-II (Pediatric Neurology and Development) Department of Paediatric Neurology, Bangabandhu Sheikh Mujib Medical University. Mobile: +8801911418558 . Email-dr.sabah10@gmail.com

**Received:** 06 July, 2021

**Accepted:** 15 October, 2021

hypointense signal and T2 weighted image showed hyper intense signal around the periventricular region which resembled to leukodystrophy. Gene analysis (Clinical exome sequencing) was done and found in location Exom 3, variant c.322C>T, classification likely

pathogenic and homozygous mutation of RNASEH2A gene and diagnosed as a case of AGS.

This child was treated with Levodopa/ carbidopa, multiminerals and with physiotherapy. Now she is on regular follow up.

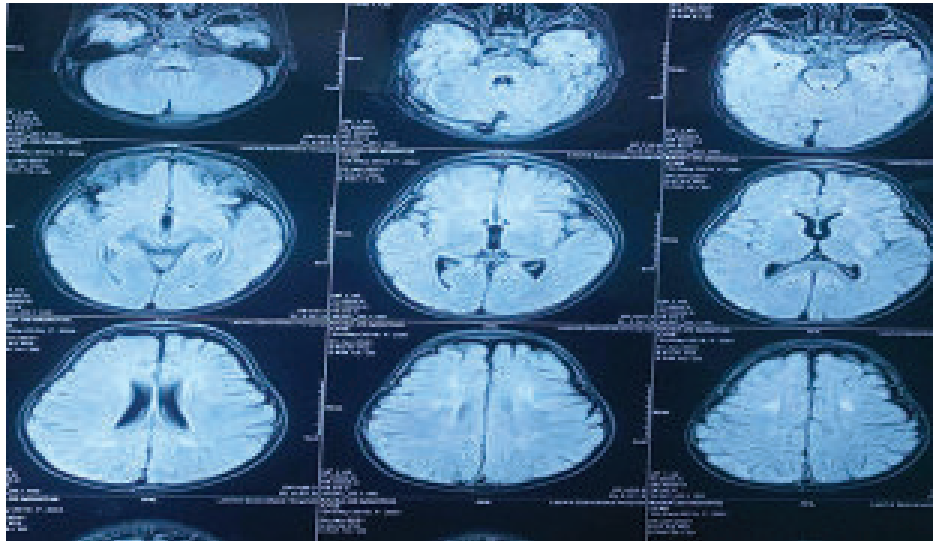


Fig-1: MRI of Brain, T1 with Flare image axial section showing periventricular white matter hyper intensity.

**Neuberg** **ORION**

**Parent and Sample Details**

Name:	RAMA	Sex:	FEMALE	Age:	11 years
Ref By:	PROF DR GOPINATHAN RAJAGOPAL	Ref Lab:	Dr. Laxmi	Lab Address:	Medical Services, Bangalore
Test Name:	ORION (WES)	Ref. Lab:	Dr. Laxmi	Lab Address:	Medical Services, Bangalore

Registration Date & Time: 2023-09-06 16:56:14    Sample Type: Whole Blood EDTA    Ph # 01  
 Sample Date & Time: 2023-09-12 16:34:53    Sample Col. By:    Ref # 1  
 Report Date & Time: 2023-09-12 16:34:53    App. Reason:    Ref # 2

**Clinical History Available:**

2 years old female presented with regression of developmental milestone. On examination she has increased eye and increased jerking. MRI brain- (a) bilateral demyelinating white matter changes in both periventricular and deep white matter. Lactic acid- 3.99mmol/L and ammonia blood- 156.

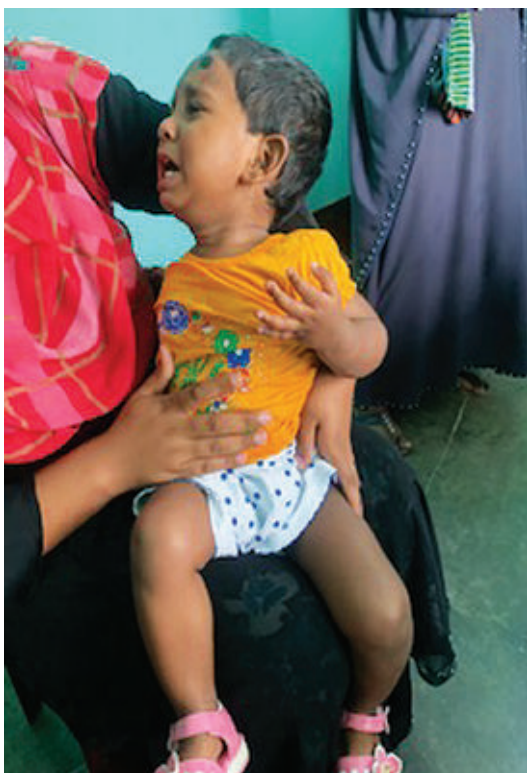**Test Results and Interpretation**

**HOMOZYGOUS LIKELY PATHOGENIC VARIANT DETECTED: CLINICAL CORRELATION RECOMMENDED**

**SUMMARY OF FINDINGS**

Gene and Transcript	Location	Variant	Zygosity	Classification	Disease	Inheritance
RNASEH2A (NM_003377)	Exon 3	c.322C>T (p.Arg107Trp)	Homozygous	Likely Pathogenic	Aicardi-Goutieres Syndrome 4	Autosomal Recessive

Fig.-2 : Report of clinical exome sequencing



**Fig.-3** A 2 year old baby of Aicardi-Goutieres Syndrome, patient is irritable, no microcephaly, upper motor neuron lesion present in both upper and lower limb

#### Discussion:

Aicardi-Goutieres syndrome is a rare, early onset, predominantly autosomal recessive neurodegenerative disorder<sup>7</sup>. The combined findings of early-onset encephalopathy, dystonia, seizures, spasticity and progressive microcephaly, psychomotor retardation associated with basal ganglia calcification, cerebral atrophy, white matter abnormalities and cerebrospinal fluid lymphocytosis as well as elevated interferon alfa are characteristics for AGS with neonatal onset<sup>8</sup>. Feeding difficulties, vomiting, ocular jerks and lack of progress in motor and social skills are the main symptoms<sup>9</sup>. Our patient presented with sudden loss of motor and cognitive skills and seizures after febrile episode.

Cutaneous findings are the most prominent extra-neurologic features of AGS. They include characteristics Chilblain-like lesions (pernio), associated acrocyanosis and nail abnormalities with erythematous periungual skin<sup>10-13</sup>. Puffy hands and feet, and distal tapering of

digits, have also been described<sup>14</sup>. Congenital glaucoma and brain stem atrophy by radiography describe by Crow et al<sup>15</sup>.

MRI of brain show high T2 signal intensity and low T1 signal intensity in the white matter, most prominently in frontal and temporal lobe, and atrophy may be significant<sup>16</sup>. Brain MRI of our patient shows hypointense signal in T1 and hyper intense signal around the periventricular region T2 image which was resemble to leukodystrophy.

Although AGS is a monogenic disorder, it is genetically heterogeneous, with seven genes implicated to date, encoding several nucleic acid processing enzymes and a cytosolic nucleic acid sensor. These comprise the RNASEH2A, RNASEH2B and RNASEH2C proteins of the RNase H2 endonuclease complex<sup>17</sup> as well as TREX1, SAMHD1, ADAR and IFIH1<sup>18,19</sup>. Heterozygous mutations in the three RNase H2 genes and TREX1 are also associated with systemic lupus erythematosus<sup>20</sup>. Our patient shows RNASEH2A gene mutation by clinical exome sequencing.

Partial loss-of-function biallelic mutations in the RNase H2 genes are the major cause of AGS, accounting for over half of all cases. RNase H2 is ubiquitously expressed and functions alongside RNase H1 to degrade cellular RNA: DNA heteroduplexes.

As there is currently no recommended treatment for AGS, Our patient was treated with Levodopa, multimineral and physiotherapy<sup>21,22</sup>.

#### Conclusion:

There are no direct treatment options for Aicardi-Goutieres Syndrome. Instead, we treat the associated symptoms. Physical and occupational therapies can also improve the conditions. Aicardi-Goutieres syndrome can cause endocrine (hypothyroidism) as well as vision problems (glaucoma). So periodic check-up is very essential.

#### References:

1. Aicardi J, Goutieres F. A progressive familial encephalopathy in infancy with calcifications of the basal ganglia and chronic cerebrospinal fluid lymphocytosis. *Annals of Neurology: Official Journal of the American Neurological Association and the Child Neurology Society.* 1984 Jan;15(1):49-54.
2. Rice GI, Kasher PR, Forte GM, Mannion NM, Greenwood SM, Szykiewicz M, Dickerson JE, Bhaskar SS, Zampini

- M, Briggs TA, Jenkinson EM. Mutations in ADAR1 cause Aicardi-Goutieres syndrome associated with a type I interferon signature. *Nature genetics*. 2012 Nov;44(11):1243-8.
3. Crow YJ. Aicardi-Goutières syndrome. *Handbook of clinical neurology*. 2013 Jan 1;113:1629-35.
  4. Goutières F. Aicardi-Goutières syndrome. *Brain Dev*. 2005 Apr;27(3):201-6. Review. Citation on PubMed (<https://pubmed.ncbi.nlm.nih.gov/15737701>)
  5. Harper J, Oranje AP. Harper's Textbook of pediatric dermatology. John Wiley & Sons; 2019 Dec
  6. Lanzi G, Fazzi E, D'ARRIGO ST. Aicardi-Goutieres syndrome: a description of 21 new cases and a comparison with the literature. *European Journal of Paediatric Neurology*. 2002 May 1;6:A9-22.
  7. Juern A, Robbins A, Galbraith S, Drolet B. Aicardi Goutières syndrome: cutaneous, laboratory, and radiologic findings: a case report. *Pediatric dermatology*. 2010 Jan;27(1):82-5.
  8. Ramantani G, Häusler M, Niggemann P, Wessling B, Guttman H, Mull M, Tenbrock K, Lee-Kirsch MA. Aicardi-Goutieres syndrome and systemic lupus erythematosus (SLE) in a 12-year-old boy with SAMHD1 mutations. *Journal of Child Neurology*. 2011 Nov;26(11):1425-8.
  9. Goutières F. Aicardi-Goutières syndrome. *Brain Dev*. 2005 Apr;27(3):201-6. doi: 10.1016/j.braindev.2003.12.011. PMID: 15737701.
  10. Aicardi J. Aicardi-Goutières syndrome: special type early-onset encephalopathy. *European Journal of Paediatric Neurology*. 2002 May 1;6:A1-7.
  11. Goutières F, Aicardi J, Barth PG, Lebon P. Aicardi Goutières syndrome: an update and results of interferon  $\alpha$  studies. *Annals of Neurology: Official Journal of the American Neurological Association and the Child Neurology Society*. 1998 Dec;44(6):900-7.
  12. Crow YJ, Massey RF, Innes JR, Pairaudeau PW, Rowland Hill CA, Woods CG, Ali M, Livingston JH, Lebon P, Nischall K, McEntagart M. Congenital glaucoma and brain stem atrophy as features of Aicardi-Goutières syndrome. *American Journal of Medical Genetics Part A*. 2004 Sep 1;129(3):303-7.
  13. Stephenson JB. Aicardi-Goutie' res syndrome – observations of the Glasgow school. *Eur J PaediatrNeurol* 2002;6(Suppl. A):A67–A70.
  14. Lanzi G, Fazzi E, D'arrigo S, Orcesi S, Maraucci I, Uggetti C, Bertini E, Lebon P. The natural history of Aicardi-Goutieres syndrome: follow-up of 11 Italian patients. *Neurology*. 2005 May 10;64(9):1621-4.
  15. Crow YJ, Leitch A, Hayward BE, Garner A, Parmar R, Griffith E, Ali M, Semple C, Aicardi J, Babul-Hirji R, Baumann C. Mutations in genes encoding ribonuclease H2 subunits cause Aicardi-Goutieres syndrome and mimic congenital viral brain infection. *Nature genetics*. 2006 Aug;38(8):910-6.
  16. Goutières F, Aicardi J, Barth PG, Lebon P. Aicardi Goutières syndrome: an update and results of interferon  $\alpha$  studies. *Annals of Neurology: Official Journal of the American Neurological Association and the Child Neurology Society*. 1998 Dec;44(6):900-7.
  17. Crow YJ, Leitch A, Hayward BE, Garner A, Parmar R, Griffith E, Ali M, Semple C, Aicardi J, Babul-Hirji R, Baumann C. Mutations in genes encoding ribonuclease H2 subunits cause Aicardi-Goutieres syndrome and mimic congenital viral brain infection. *Nature genetics*. 2006 Aug;38(8):910-6.
  18. Crow YJ, Hayward BE, Parmar R, Robins P, Leitch A, Ali M, Black DN, Van Bokhoven H, Brunner HG, Hamel BC, Corry PC. Mutations in the gene encoding the 32 -52 DNA exonuclease TREX1 cause Aicardi-Goutieres syndrome at the AGS1 locus. *Nature genetics*. 2006 Aug;38(8):917-20.
  19. Rice GI, Bond J, Asipu A, Brunette RL, Manfield IW, Carr IMFuller JC, Jackson RM, Lamb T, Briggs TA, Ali M, Gornall H, Couthard LR, Aeby A, Attard-Montalto SP, Bertini E, Bodemer C, Brockmann K, Brueton LA, Corry PC, et al (2009) Mutations involved in Aicardi-Goutieres syndrome implicate SAMHD1 as regulator of the innate immune response. *Nat Genet* 41: 829 – 832
  20. Günther C, Kind B, Reijns MA, Berndt N, Martinez-Bueno M, Wolf C, Tungler V, Chara O, Lee YA, Hubner N, Bicknell L, Blum S, Krug C, Schmidt F, Kretschmer S, Koss S, Astell KR, Ramantani G, Bauerfeind A, Morris DL, et al (2015) Defective removal of ribonucleotides from DNA promotes systemic autoimmunity. *J Clin Invest* 125: 413 – 424
  21. Lee-Kirsch MA, Gong M, Chowdhury D, Senenko L, Engel K, Lee YA, de Silva U, Bailey SL, Witte T, Vyse TJ, Kere J, Pfeiffer C, Harvey S, Wong A, Koskenmies S, Hummel O, Rohde K, Schmidt RE, Dominiczak AF, Gahr M, et al (2007) Mutations in the gene encoding the 30-50 DNA exonuclease TREX1 are associated with systemic lupus erythematosus. *Nat Genet* 39: 1065 – 1067
  22. Crow YJ, Manel N (2015) Aicardi-Goutieres syndrome and the *type I interferonopathies*. *Nat Rev Immunol* 15: 429 – 440