

First Dorsal Metacarpal Artery Flap : A Reliable Option for Reconstruction of Extensive Pulp Defects of the Thumb

MA CHOWDHURY^a, MSJ KHAN^b, ASARKER^c, MA HOSSAIN^d

Abstract:

Background: Thumb pulp defects are commonly due to avulsion injuries. The choice of reconstructive procedure for thumb depends on the amount and type of tissue lost. The First Dorsal Metacarpal Artery (FDMA) flap is a versatile method with minimum donor site morbidity which provides protective sensation, adequate length, stability and good mobility.

Method: This study was done over a period of 2 years and involved 15 consecutive cases of thumb pulp defects treated at our institution. The patient included 13 men and 2 women ranging in age from 16 to 60 years. The defects were ranged from 2cm x 1.5cm to 5cm x 3cm.

Results: All flaps survived completely except one had marginal flap necrosis healed without the need for a secondary procedure. Donor site was covered with full thickness skin graft that healed spontaneously.

Conclusion: First dorsal metacarpal artery flap offers a sensate, pliable and versatile coverage for soft tissue defects of the thumb. It provides good functional results with minimum donor site morbidity.

Key words: first dorsal metacarpal artery flap, avulsion injuries, thumb reconstruction, sensate flap.

(J Bangladesh Coll Phys Surg 2023; 41: 53-57)

DOI: <https://doi.org/10.3329/jbcps.v41i1.61886>

Introduction

Thumb pulp defects are commonly due to avulsion injuries. While superficial defects can be treated with skin grafts, deeper defects with exposure of tendon or bone are more difficult to reconstruct¹, because of the lack of locally available tissue². The goals of correction of traumatic deformities of the distal thumb are to maintain adequate length and sensation along with giving a supple and stable soft tissue cover.³

The choice of reconstructive procedure for thumb depends on the amount and type of tissue lost⁴. The options vary from secondary intention healing, free skin grafts, lateral triangular advancement flap, V-Y advancement flap to palmar advancement flap, volar neurovascular advancement flap (Moberg flap), FDMA

flap, cross finger flap, Littler's neurovascular island flap, pulp tissue transfer of toe and other small free flaps.^{5, 6} The first dorsal metacarpal artery flap was first described by Foucher and Braun who demonstrate that a sensate skin island flap created from the dorsum of the index finger could be raised based upon the first dorsal metacarpal artery and sensory branch of radial nerve.³

The first dorsal metacarpal artery arises from the radial artery in the first intermetacarpal space, just distal to the tendon of the extensor pollicis longus. The artery divides into the radial branch of the thumb, intermediate branch to the first web space and the ulnar branch to the index finger.⁷ The ulnar branch usually courses distally within the musculo-osseous groove, between the ulnar head of the first dorsal interosseous muscle and the radial shaft of the second metacarpal bone, until it reaches the metacarpophalangeal (MP) joint.⁸ The FDMA is in a superfascial (57%) or subfascial (43%) location. The outer diameter of the artery at the widest point is 1.0 ± 1.5 mm. Flap pedicle is about 5-9 cm. The length of the flap varies from 2-4 cm.

The aim of this study is to see the versatility of the FDMA flap through donor site morbidity, protective sensation, stability and the mobility following covering the extensive pulp defect of the thumb.

- Dr. Maruf Alam Chowdhury, Associate Professor and Head, Department of Plastic Surgery, NITOR.
- Dr. Mohammad Saneat Jahan Khan, Assistant Professor, Department of Plastic Surgery, Faridpur Medical College.
- Dr. Avijit Sarker, Junior Consultant, Department of Plastic Surgery, NITOR.
- Dr. Mohammad Abul Hossain, Assistant Registrar, Department of Plastic Surgery, NITOR.

Address of Correspondence: Dr. Maruf Alam Chowdhury, Associate Professor and Head, Department of Plastic Surgery, NITOR. Mobile: 01711675985, 01929766297,

E-mail: maruf.alam.chowdhury@gmail.com

Received: 25 Nov., 2021

Accepted: 15 January, 2022

Materials and Methods

The study was conducted at Department of Plastic Surgery, National Institute of Traumatology and Orthopedic Rehabilitation (NITOR) from January 2018 to December 2020 in fifteen patients. Patients included 13 men and 2 women, ranging in age from 16 to 60 years. In all cases the cause of injury was work related. They all had avulsion injury or painful scar needing reconstruction.

The defects were ranged from 2cm × 1.5cm to 5cm × 3cm. The pedicular length ranged between 5 and 8 cm. All defects were reconstructed by island first dorsal metacarpal artery flap as a delayed procedure. All the flaps were studied for sensory return in the form of fine touch and two point discrimination.

Surgical technique

The patient is placed in supine position and arm is positioned on the arm table. The operation is done in

plexus block or under general anesthesia. After excision of the thumb defect, the skin flap is outlined. The flap is harvested from the dorsum of the index finger, including the first dorsal metacarpal artery and branch of the superficial radial nerve as a pedicled flap. The first DMCA is identified at the emerge point between the two head of the first dorsal interosseous muscle in the index finger.

The fascia is cut and the periosteum is then stripped off the second metacarpal bone on the radial side. The nutrient branch to the metacarpal head is identified and tied up. The flap is elevated, leaving the paratenon intact. The pedicle includes the fascia of the first dorsal interosseous muscle, the dorsal veins and the sensory branch of radial nerve. Then the flap is placed over the defect. The donor area is covered by FTSG. A lot of attention should be taken to the pedicle positioning in order to prevent strangulation.

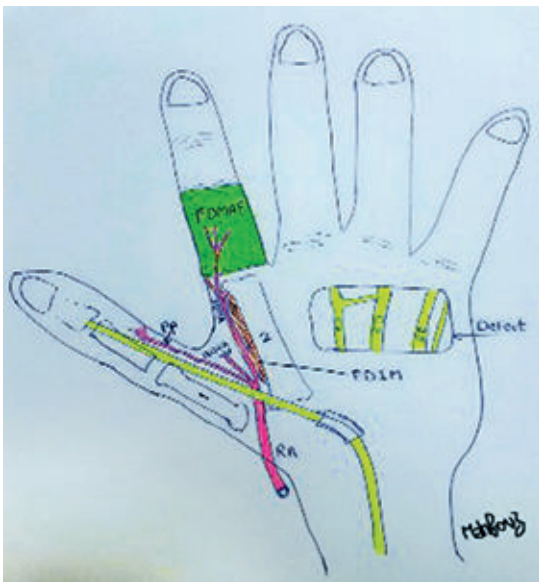

Fig.-1: Diagrammatic Anatomy

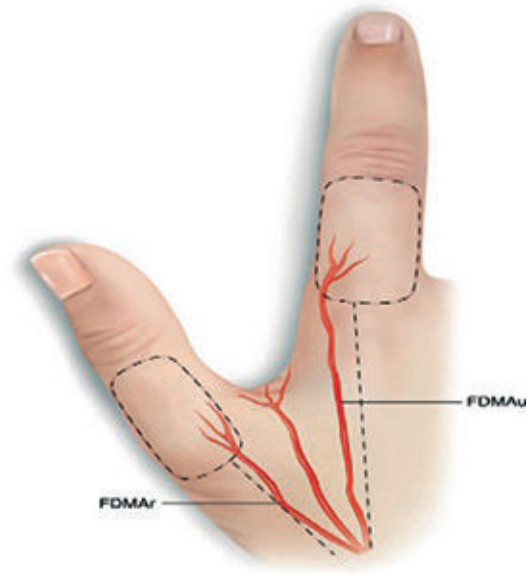


Fig.-2: Branches of FDMA

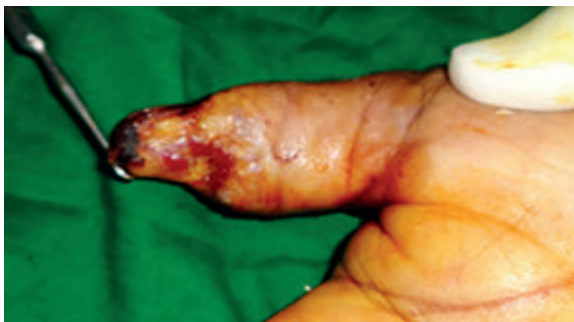

Fig.-3: Initial soft tissue defect

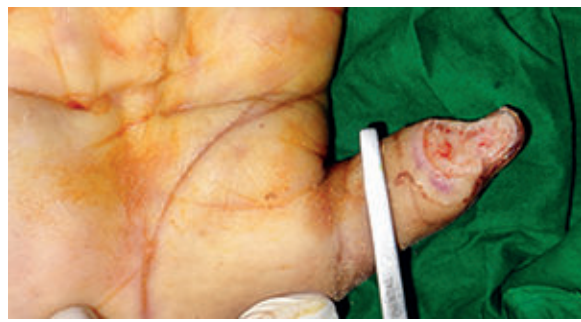

Fig.-4: Acquired volar defect of thumb

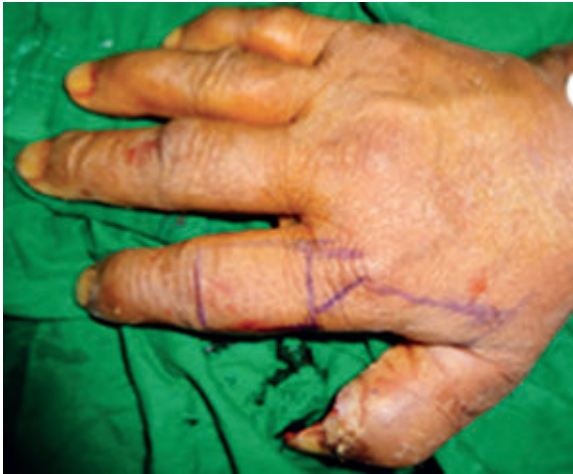

Fig.-5: *FDMA flap design*

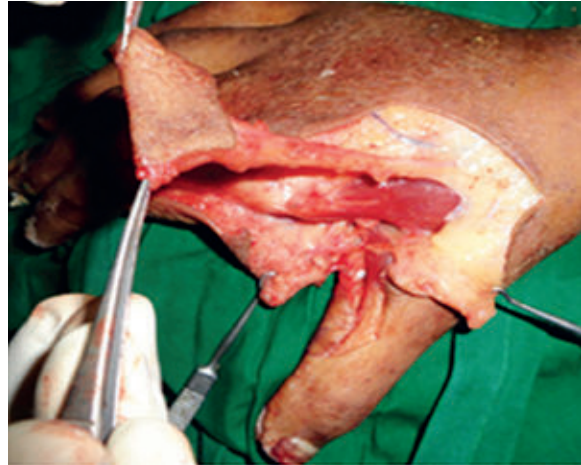

Fig.-6: *FDMA flap harvesting*

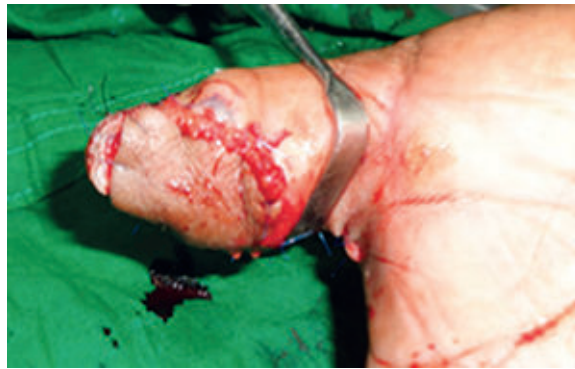

Fig.-7: *Flap insetting*

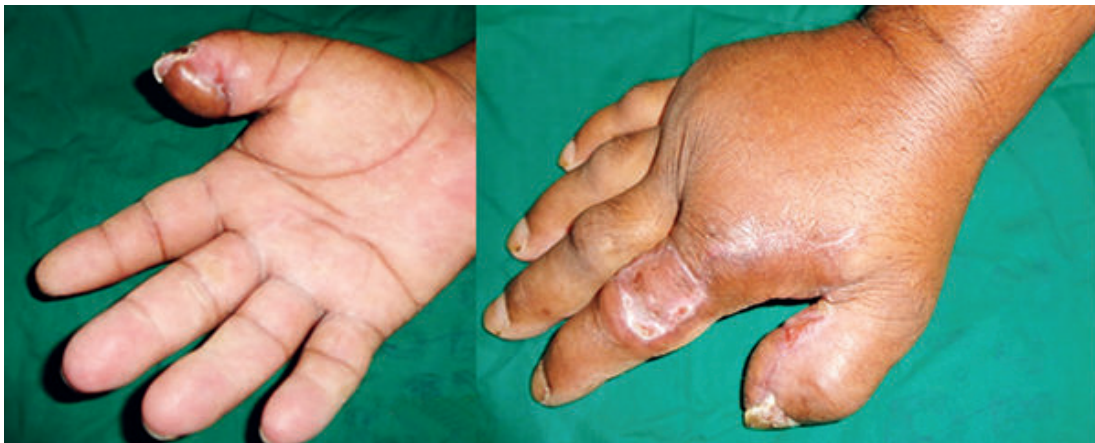

Fig 8: *Follow up at 6 months*

Results

Clinical data was summarized on Table 1. The flap sizes ranged from 2×1.5cm to 5×3cm. All flaps survived

completely except one had marginal flap necrosis which healed without the need for a secondary procedure. All our cases were done under regional anesthesia with

Table 1

patient	Age/sex	cause	Flap size in cm	Complications	Static 2PD in mm
1.	22/M	Avulsion	3.5 × 3	Nil	6
2.	21/M	Avulsion	4 × 2.5	Nil	6
3.	24/M	Avulsion	3 × 1.5	Nil	6
4.	30/F	Scar contracture	3 × 1.5	Nil	7
5.	24/M	Avulsion	4 × 2	Nil	8
6.	32/M	Avulsion	3.5 × 2.5	Nil	6
7.	18/M	Avulsion	4.5 × 3	Nil	9
8.	36/F	Avulsion	3 × 1.5	Nil	6
9.	58/M	Avulsion	3.5 × 2	Marginal necrosis	7
10.	47/M	Avulsion	4 × 3	Nil	7
11.	25/M	Avulsion	5 × 3	Nil	6
12.	28/M	Avulsion	4 × 2.5	Nil	7
13.	60/M	Avulsion	3.5 × 1.5	Nil	6
14.	37/M	Avulsion	4.5 × 3	Nil	8
15.	16/M	Avulsion	3.5 × 1.5	Nil	8

tourniquet control. The average duration of surgery was 1 hour. The mean follow up of the patient was 18 months. All the patients had good fine touch and average two point discriminations of 7.5mm, which was satisfactory. The skin grafts applied to the donor area were satisfactory and full recovery of flexion and extension of the index finger was also obtained.

Discussion

Complex soft tissue defects of the thumb with exposure of tendons, joints or bones have always been a challenging reconstructive task.¹ the choice of reconstructive procedure for thumb depends on the amount and type of tissue lost and it includes secondary intension healing, free skin grafts, lateral triangular advancement flaps, V-Y advancement flaps, palmar advancement flaps, FDMA flaps, cross finger flaps and neurovascular island or radial sensory innervated cross finger flaps.⁶ Nevertheless, each therapeutic modality has its own advantages and limitations.

Skin grafting is an easy technique but it is only limited to defects without exposed bone or tendons.⁹ Local flaps offer superior aesthetic results due to replacement 'like with like' tissue. However limited arc of rotation and limited amount of soft tissue availability are major drawbacks.¹ Moberg flap is indicated for defects not exceeding 1.5cm in diameter, whereas may be

complicated by flexion contracture or joint stiffness.¹⁰ Although, the cross finger flap is frequently used as a salvage procedure, it is a staged one with the risk of finger joint stiffness and first web contracture.¹¹

Littler's neurovascular island flap harvested from the distal ulnar aspects of the middle or ring finger. However the incorporation of the digital vessel is a major disadvantage.¹² The other disadvantages are cold intolerance, poor cortical reorientation and loss of two point discrimination.¹²

Distant flaps are less commonly used, the remain a useful tool for complex soft tissue defects of the thumb.¹³ They are limited by the need for additional procedure for separation and debulking to optimize hand functions. Micro vascular transfer of free flap from foot was described to remedy such problem. However, the needs for microsurgical experience and facilities, long operating time and moderate to poor sensory outcome are major handicaps.¹⁴

FDMA island flap is harvested from the dorsal aspect of the index finger including the first dorsal metacarpal artery with its concomitants veins and a branch of the superficial radial nerve as a pedicle neurovascular flap.¹⁵ It was first described by Hilgenfeldt, refined by Holveich and modified as a pure island flap by Foucher and Braun. It has a wide arc of rotation, the possible size of the flap is big and donor side morbidity is low.¹⁵

Contraindications of the FDMA flap are circular defects at the proximal or distal phalynx and previous injury at the second metacarpal level.¹⁵

In our study, mean flap size was 37.6×22.7 mm and we had only one marginal flap necrosis that was managed conservatively. In a similar study Samir¹ used 15 FDMA flaps to cover post traumatic thumb defects and found that mean flap size was 33.3×17.7 mm only one flap had distal flap necrosis that healed without secondary procedure.¹ Chetan reported a study of 9 cases with FDMA flaps to cover post traumatic thumb defects and found that ranged from 2×1.5 cm to 5×3 cm and had only 1 complication in the form of partial flap necrosis, which fortunately healed following debridement without need for a secondary procedure.²

Its advantage includes the ease to harvest, does not require much expertise, sensate and minimum donor site morbidity. Its disadvantages are the size limitation of the flap, which can extend distally to the PIP joint and proximally to the MP joint and violation of the normal digit for reconstruction of the thumb.¹⁶

Conclusion

FDMA flap offers a sensate, pliable and versatile coverage for small to moderate sized defects for both dorsal and volar aspects of the thumb. It provides good stable & functional coverage and protective sensory recovery with minimum donor site morbidity.

Conflicts Interests: None

Ethical Issues: Informed written consent was obtained from each of the participants and ethical clearance was taken.

References:

- Ghoraba SM, Mahmoud WH. Outcome of thumb reconstruction using the first dorsal metacarpal artery island flap. *World J PlastSurg* 2018; 7(2):151-58.
- Satish C, Nema S. First dorsal metacarpal artery island flap: A useful flap for reconstruction of thumb pulp defects. *Indian J PlastSurg* 2009; 42(1):32-5. <https://doi.org/10.4103/0970-0358.53003> PMID:19881017 PMCID:PMC2772290
- Chang S-C, Chen S-L, Chen T-M, Chuang C-J, Cheng T-Y, Wang H-J. Sensate first dorsal metacarpal artery flap for resurfacing extensive pulp defects of the thumb. *Ann Plast Surg*.2004 Nov;53(5):449-54. <https://doi.org/10.1097/01.sap.0000137134.15728.dd> PMID:15502460
- Toomayuo IAD. An evaluation of first dorsal metacarpal artery flap finished by consultants and residents and guiding principle for improving result for beginners. *IJMSIR*.2016 Sept-Oct;1(3):10-4
- Guelmi K, Barbata B, Maladry D, Mitz V, Lamerle JP. Reconstruction of digital pulp by pulp tissue transfer of the toe. *Rev Chir Ortho ReparatriceAppar Mot*. 1996;82:446-52.
- Sulhyan SR, Prabhu M, Power R. FDMA flap: A versatile technique to reconstruct the thumb. *Ind J Pharm Med & Bio Sc* 2013Oct;2(4):8-14.
- Kola N. Thumb reconstruction using Foucher's flap. *O A Maced J Med Sci* 2016Jan;17:1-4. <https://doi.org/10.3889/oamjms.2016.017> PMID:27275333 PMCID:PMC4884256
- Sherif MM. First dorsal metacarpal artery flap in hand reconstruction, I anatomy surgery study. *J Hand Surg*.1994;19A:32-38. [https://doi.org/10.1016/0363-5023\(94\)90221-6](https://doi.org/10.1016/0363-5023(94)90221-6) PMID:8169366
- Arafa AL. Dorsal metacarpal artery flap. *Egypt. J. Plast. Reconstr. Surg*. 2016 Jan;40(1):73-9.
- Rodriguez JIS, Brown DRDR, Lopaz RCP. First dorsal metacarpal artery flap for thumb reconstruction. *M J Surg*.2018Jul;2(1):010.
- Woon CY, Lee JY, Teoh LC. Resurfacing hemipulp losses of the thumb: The cross finger flap revisited: Indications, technical refinements, outcome and long-term neurosensory recovery. *Ann PlastSurg* 2008;61: 385-91. <https://doi.org/10.1097/SAP.0b013e3181640873> PMID:18812707
- Xarchas KC, Tikeridis KE, PelikasSI ,KazakosKj, KakagiaDD,Verettas DA. Litle's flap revisited: An anatomic study, literature review, and clinical experience in the reconstruction of large thumb pulp defects. *Med Sci Mont* 2008;14:568-73.
- Biswas D, Wysocki RW, Fernandez JJ, cohen MS. Local and regional flaps for hand coverage. *J Hand Surg Am* 2014;39:992-1004. <https://doi.org/10.1016/j.jhsa.2013.09.027> PMID:24766831
- Adani R, Cardon LJ, Castagnetti C, Pinelli M. Distal thumb reconstruction using a mini wrap-around flap from the great toe. *J Hand Surg* 1999;24:437-42. <https://doi.org/10.1054/JHSB.1999.0161> PMID:10473152
- Muylderman T, Hiener R. First dorsal metasarpal artery flap for thumb reconstruction: a retrospective clinical study. *StratTraum Limb Recon* 2009 April;4:27-33. <https://doi.org/10.1007/s11751-009-0056-1> PMID:19340522 PMCID:PMC2666828
- Trankle M, Sauerbier M, Heitmann C and Germann G. Restoration of thumb sensitivity with the innervated first dorsal metacarpal artery island flap. *J. Hand S*