

# Case Report - Fibrosarcoma of Ovary

JA NIRA

### Abstract

*Fibrosarcoma of ovary, a tumour arising do novo or secondary to malignant transformation of benign fibromatous tumours, is an extremely rare malignant sex cord stromal tumour of ovary. As on today, the total number of reported cases throughout the world is not more than hundred, There is no clearcut diagnostic criteria, prognostic factor and treatment modalities. Usually it presents as unilateral solid tumour. It can occur at any age though postmenopausal diagnosis is more frequent. Majority of the patients present with vague abdominal pain and a lump in lower abdomen arising from ovary. Ultrasonographic findings usually reveals unilateral solid homogenous tumour in ovary with uneven echo enhancement and increased vascularity. Serum tumor markers and sex hormones such as CA-125 usually found within normal levels. Peroperative frozen section study often concludes into wrong diagnosis, postoperative histopathological diagnosis usually reveals spindle cells with high mitotic activity with background of fibrous tissue. Depending on mitotic activity, cellular atypia associated with haemorrhage and necrosis, it is differentiated from*

*benign fibroma with mitotic activity. Immunohistochemistry findings may be positive for vimentin,  $\alpha$ -inhibin, SMA, estrogen receptor, progesterone receptor. Ki-67 positive rate is associated with degree of severity of malignancy i.e, grading and prognosis. Our case was having the above features and was confirmed postoperatively by histological and later by histochemistry with positive Vimentin and Ki-67. As there were not enough cases to conclude a final treatment protocol, so far treated cases revealed total cytoreductive surgery followed by postoperative chemotherapy has the better prognosis. A round, solid unilateral heterogenous ovarian tumor should be taken in differential diagnosis of ovarian fibrosarcoma. As this is an extremely rare tumour of the ovary, there is usually no rise of specific tumour marker, no conclusive diagnostic criteria available at present, clinical studies involving multicentered approach associated with studies at molecular level is a prime requirement for the gynaecologist to diagnose and treat in a better way in future.*

*(J Bangladesh Coll Phys Surg 2023; 41: 89-92)*

DOI: <https://doi.org/10.3329/jbcps.v41i1.63264>

### Introduction:

Fibromas are ovarian sex cord stromal tumors which depending on their mitotic activity can be classified from fibromas to fibrosarcomas.<sup>1</sup> Primary ovarian fibrosarcoma are rare tumour that is considered to arise de novo or secondary to benign fibromatous tumours and comprises less than 1% of ovarian malignancies.<sup>2</sup> Criteria for diagnosis of fibrosarcoma of ovary were established by Pratt and Scully.<sup>3</sup> Number of mitoses is considered as the most important features of diagnosis. Mitotic count up to 3 per 10 HPF are called cellular fibromatous lesion. When mitotic figures  $\geq 4$  per 10 HPF but do not have nuclear atypia. They are defined

as mitotically active cellular fibroma. When higher mitotic activity and nuclear atypia having aggressive pattern, it is considered as malignant fibrosarcoma.<sup>4</sup> Most of the fibrosarcoma develops around menopause but it can occur at any age. Among the published studies, the 2- years survival rate was found approximately 55.9%.<sup>5</sup> Per operative frozen section biopsy is inconclusive and often misleading, the final diagnosis depends on immunohistochemistry as histopathological examination cannot distinguish properly from benign mitotically active fibroma.<sup>6</sup> As the incidence is too rare, reported cases are too few and are sporadic. Here, we present one case of ovarian fibrosarcoma that presented at Combined Military Hospital (CMH), Cumilla, where no previous reported case of ovarian fibrosarcoma was known. To get a diagnostic protocol and a universally accepted guideline for treatment, accumulated reports from different centers is very much necessary.

**Address of Correspondence:** Lt Col (Dr) Julia Akhter Nira, Head of the Department, Dept of Gynae and Obstetrics, CMH and Army Medical College, Cumilla Cantonment, 183/4, officers quarter, Mess-A area, Cumilla cantonment

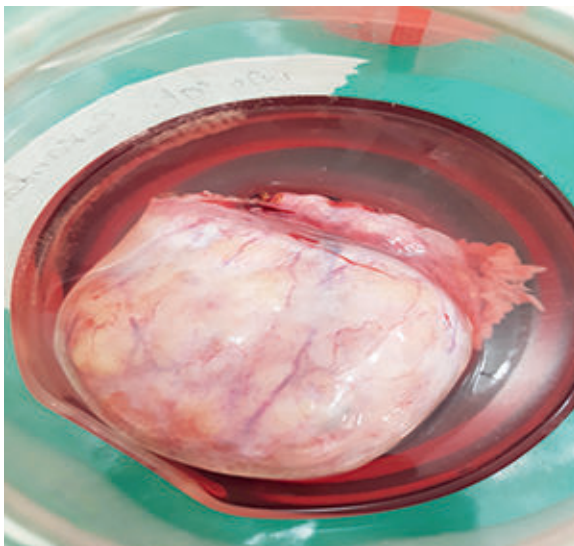
Mobile: 01715786896, E-mail: [sharif936@yahoo.com](mailto:sharif936@yahoo.com)

[nira.dmc.k49@gmail.com](mailto:nira.dmc.k49@gmail.com)

**Received:** 23 January, 2022      **Accepted:** 18 October, 2022

**Case report:**

A-37-year-old woman, para 3+0, presented with the complaints of vague lower abdominal pain for one and half months and a USG finding of pelvic mass, most probably right ovarian origin, about 10x7x6 cm, left ovary was unremarkable and there was no ascites. The tumor had mixed echogenicity containing both solid and cystic components. CA-125 was found mildly raised 58.5 IU/ml, other tumor markers like CA-19-9, CEA, LDH, beta HCG levels were within normal limits. As the patient was young and there was unilateral ovarian tumor, no symptoms or signs of malignancy, tumor markers were not raised, no ascites on USG, frozen section facility was not kept. Patient underwent diagnostic laparoscopy followed by laparotomy in the same sitting. Following opening of abdomen an apparently solid tumor measuring about 10x8 cm was seen in right ovary. The tumor had yellowish fat like tissue inside, no papillary projection or breach in the capsule was seen. The left ovary was found apparently normal in size and shape. There was no collection in the pelvic cavity and POD had no deposit. considering her age, tumor marker reports and per operative findings, right sided salpingo-oophorectomy was done. The postoperative period was uneventful. The patient was discharged on 8th post operative day. Gross appearance of the tumor in histopathology report revealed a single ovarian mass 10x7x6 cm, solid and homogeneous with Fallopian tube 70 mm overlying it. (figure-1)



Microscopic findings revealed highly cellular stromal tumor composed of fascicles of pleomorphic spindle cells, arranged in interlacing pattern, embedded in scanty fibrotic stroma. Mitosis was seen frequently. Focal area of necrosis was seen.

Immunohistochemistry (741/21)- the tumor cells showed the following immunophenotype: Vimentin positive; SMA, inhibin, cytokeratin, calretinin- negative. About 5% cell had

positive Ki-67. After getting the histopathology report the patient was reevaluated by oncologist and placed in tumor board. CT Scan done revealed prominent left ovary 4x3.5x3 cm with multiple small cysts, mildly enhanced solid portions of ovary, no secondary deposits were seen in any part of abdomen and pelvis. Tumor board was held on 19.4.2021 and board recommended review of the slide for grading of the tumor and adjuvant chemotherapy using EP schedule. Patient got chemotherapy as per schedule and was on regular follow up. Till now there is no feature of recurrence or metastasis.

**Discussion:**

Primary ovarian fibrosarcoma is an extremely rare malignant sex cord stromal tumour.<sup>7,8</sup> They are considered to have originated directly from stromal cells around the sex cord of ovarian follicles or from malignant transformation of a benign fibroma.<sup>1,9</sup> Although most of them appear in menopausal and postmenopausal women, this tumour can occur at any age. Patients usually present with pain and swelling of abdomen due to presence of rapidly progressing pelvic mass. Normally the tumour is unilateral and adherent with the adjacent pelvic organs due to breakage of capsule and presence of infiltrative margins. Fortunately, our patient's tumor was moderate in size without having broken capsule and adhesions. Microscopically there is presence of mitotic figure 4 or more per 10 HPF with nuclear atypia with presence of necrosis and haemorrhage.<sup>8</sup> In some cases, trisomy 12 or 18 has been reported in these neoplasms.<sup>5</sup> Due to early distant metastasis and resistance to some adjuvant chemotherapy, the survival rate is around 2 years and prognosis is poor.<sup>6</sup> Recently several cases with long posttreatment survival have been reported. Our patient, after getting chemotherapy, showed no symptoms of recurrence or metastasis for 2 years.

Primary ovarian fibrosarcoma has many diagnostic dilemmas. First of all, there is no specific immunohistochemical staining or molecular type for this tumour. All the stromal cell tumours including tumours containing muscles are spindle shaped. In addition the mitotic activity is variable in different specimens of same type of tumour.<sup>7,8,9</sup> Some Krukenberg tumour, epithelial tumour and sarcomatoid tumour have similar spindle shaped cells as that of fibrosarcoma which should be differentiated from it by extensive sampling. Primary ovarian leiomyosarcoma and ovarian invasion from uterine origin have histology like fibrous tumour but can be separated by the presence of higher grade of pleomorphism and specific immunohistochemical stain for smooth muscle. Ovarian fibrosarcoma is differentiated from other sex cord stromal tumour by doing stain for inhibin though some stromal cells may be positive.<sup>1</sup> According to some reports, the immunohistochemistry for Ki-67 is indicative of its proliferative activity, degree of malignancy and prognosis. Our patient's tumour had mitotic activity to 4, positive for Ki-67, suggestive of primary ovarian fibrosarcoma. In addition, vimentin, SMA, estrogen receptor, progesterone receptor may also be positive. Our patient's tumour was positive for Vimentin. In the differential diagnosis of these spindle-shaped lesions, we should also consider the possibility of gastrointestinal stromal tumours involving the ovary; in these cases, immunostain for CD117 or molecular studies, evaluating c-kit mutations, would be essential.<sup>1,9</sup> Endometrial stromal sarcomas gradually invade ovary, so it should be kept as differential diagnosis specially those contain spindle shaped cell pattern. They are positive for CD10 in immunohistochemistry.<sup>10,11</sup> Rare tumours like dendritic cell neoplasm and melanoma have occasional spindle shaped cells or sarcomatoid pattern. As ovarian fibrosarcoma is an extremely rare tumour, there is no universally accepted guidelines for treatment. Among the previously diagnosed cases, treatment varied from unilateral adnexectomy to complete cytoreductive surgery (hysterectomy+ bilateral adnexectomy+ omentectomy+ appendicectomy+ pelvic and/or abdominal lymphadenectomy).<sup>12,13,14</sup> but early and thorough surgery is preferred in all cases. Surgical staging is necessary in every case and cytoreduction should be performed as completely as possible. Fertility preservation surgery in young patient is still debatable. Postsurgical adjuvant radiotherapy and chemotherapy

should be selected on individual basis. As it was stage I tumour, following unilateral salpingo-oophorectomy, our patient received postoperative chemotherapy with EP schedule.

Ovarian fibrosarcoma is an extremely rare but aggressive tumour so the survival rate is 1 year and it usually depends on the modality of treatment given. Patient undergoing complete cytoreductive surgery followed by adjuvant chemoradiotherapy has better prognosis than patient with unilateral adnexectomy or surgery plus radiotherapy (100% vs 27.9%, p-value 0.002).<sup>12,14</sup> In multivariate analysis, the FIGO staging and treatment have independent prognostic factor but age, tumour size, mitotic activity and other prognostic factor were not statistically significant.<sup>8,15</sup> Though in our patient unilateral adnexectomy followed by adjuvant chemotherapy given, still after 2 years of treatment there is no sign of recurrence or metastasis. Though small in number of patients for making a comment, there was recommendation for total cytoreductive surgery with staging followed by adjuvant chemoradiotherapy in maximum cases.<sup>16</sup>

#### Conclusion:

Primary ovarian fibrosarcoma is an extremely rare malignant sex cord stromal tumour. So whenever a unilateral, heterogeneous, largely round solid lesion is detected at the preoperative examination, it should be kept in differential diagnosis. The diagnostic dilemma and its resemblance with other stromal tumour and metastatic tumour containing spindle shaped cell makes it difficult to detect its treatment and prognosis. For this reason, multicentered approach is needed for establishing an universally accepted diagnostic and treatment protocol.

#### References

1. Irving JA, Alkushi A, Young RH, Clement PB. Cellular fibromas of the ovary: a study of 75 cases including 40 mitotically active tumors emphasizing their distinction from fibrosarcoma. *Am J Surg Pathol.* 2006;30:929-38. <https://doi.org/10.1097/0000478-200608000-00001> PMID:16861962
2. Sun, TT., Cheng, NH., Cao, DY. et al. Ovarian fibrosarcoma: A single-institution experience and a review of the literature. *J Ovarian Res* 13, 142 (2020). <https://doi.org/10.1186/s13048-020-00749-x> PMID:33292402 PMCID:PMC7724700

3. Prat J, Scully RE. Cellular fibromas and fibrosarcomas of the ovary: a comparative clinicopathologic analysis of seventeen cases. *Cancer*. 1981;47(11):2663-70. [https://doi.org/10.1002/1097-0142\(19810601\)47:11<2663::AID-CNCR2820471124>3.0.CO;2-V](https://doi.org/10.1002/1097-0142(19810601)47:11<2663::AID-CNCR2820471124>3.0.CO;2-V) PMID:7260859
4. Shakfeh SM, Woodruff JD. Primary ovarian sarcomas: report of 46 cases and review of the literature. *Obstet Gynecol Surv*. 1987;42(6):331-49. <https://doi.org/10.1097/00006254-198742060-00001>
5. Huang L, Liao L-M, Wang H-Y, Zheng M. Clinicopathologic characteristics and prognostic factors of ovarian fibrosarcoma: the results of a multi-center retrospective study. *BMC Cancer*. 2010;10:585. <https://doi.org/10.1186/1471-2407-10-585> PMID:20979607 PMCID:PMC2984427
6. Tsuji T, Kawauchi S, Utsunomiya T, Nagata Y, Tsuneyoshi M. Fibrosarcoma versus cellular fibroma of the ovary: a comparative study of their proliferative activity and chromosome aberrations using MIB-1 immunostaining, DNA flow cytometry, and fluorescence in situ hybridization. *Am J Surg Pathol*. 1997;21(1):52-9. <https://doi.org/10.1097/00000478-199701000-00006> PMID:8990141
7. Celýk C, Güngör S, Görkemly H, Bala A, Capar M, Colakodlu M, et al. Ovarian fibrosarcomas. *Acta Obstet Gynecol Scand*. 2002;81(4):375-6. <https://doi.org/10.1080/j.1600-0412.2002.810420.x> PMID:11952474
8. Lee H-Y, Ahmed Q. Fibrosarcoma of the ovary arising in a fibrothecomatous tumor with minor sex cord elements. A Case report and review of the literature. *Arch Pathol Lab Med*. 2003;127(1):81-4. <https://doi.org/10.5858/2003-127-81-FOTOAI> PMID:12521373
9. Testa AC, Gaurilcik A, Licameli A, Mancari R, Di Legge A, Malaggesse M, et al. Sonographic features of primary ovarian fibrosarcoma: a report of two cases. *Ultrasound Obstet Gynecol*. 2009;33(1):112-5. <https://doi.org/10.1002/uog.6291> PMID:19072774
10. Kaku S, Takeshima N, Akiyama F, Furuta R, Hirai Y, Takizawa K. A unique fibrous tumor of the ovary: fibrosarcoma or mitotically active cellular fibroma? *Anticancer Res*. 2007;27:4365-9.
11. Bi R, Zhao Y, Yang WT. Mitotically active cellular fibroma of ovary: a clinicopathologic analysis. *Zhonghua Bing Li Xue Za Zhi*. 2013;42:660-4.
12. Zong L, Lin M, Fan X. Mitotically active cellular fibroma of ovary should be differentiated from fibrosarcoma: a case report and review of literature. *Int J Clin Exp Pathol*. 2014;7(11):7578-82.
13. García Jiménez A, Castellví J, Pérez Benavente A, Díaz de Corcuera Frutos I, Ramón Y, Cajal S. (2009). Ovarian Fibrosarcoma: Clinicopathologic Considerations about the Intraoperative and Post-Surgical Procedures. <https://doi.org/10.1155/2009/802817> PMID:20168988 PMCID:PMC2820290
14. Grauso F, Messalli EM, Salzillo ME, Di Martino L, Falcone F, Orabona P, et al. Ovarian fibrosarcoma: case report and latest trends in diagnostic and therapeutic management. *Eur J Gynaecol Oncol*. 2015;36(6):742-5.
15. Gultekin M, Dursun P, Ozyuncu O, Usbutun A, Yuce K, Ayhan A. Primary ovarian fibrosarcoma: a case report and review of the literature. *Int J Gynecol Cancer*. 2005;15(6):1142-7. <https://doi.org/10.1111/j.1525-1438.2005.00327.x> PMID:16343198
16. Choi W-J, Ha M-T, Shin J-K, Lee J-H. Primary ovarian fibrosarcoma with long-term survival: a report of two cases. *J Obstet Gynaecol Res*. 2006;32(5):524-8. <https://doi.org/10.1111/j.1447-0756.2006.00448.x> PMID:16984523