

# Surgical Correction of Aortic Coarctation with Left Subclavian Artery and Proximal Descending Thoracic Aorta Aneurysm with moderate Left Ventricular Dysfunction in an adult Female- a case report

SD GUPTA<sup>a</sup>, MHAQUE<sup>b</sup>, J ROY<sup>c</sup>, BC MANDOL<sup>d</sup>, MUDDIN<sup>e</sup>, PK CHANDA<sup>f</sup>

## Abstract:

*In its simplest form, coarctation of the aorta (CoA) refers to congenital narrowing of the thoracic aorta. Usually, a significant pressure gradient between the arms and legs is suggestive of the diagnosis. With the advancement of aortic imaging in our country many CoA patients are diagnosed at an adult age, but the management still carries a challenge.*

*We reported a case of 30-year-old lady with CoA with an aortic aneurysm involving proximal left subclavian artery with proximal DTA and LV dysfunction.*

**Keywords:** Coarctation of Aorta (CoA), Aortic Surgery, Cardiac surgery, Aortic aneurysm, Proximal DTA aneurysm;

(*J Bangladesh Coll Phys Surg 2023; 41: 93-97*)

DOI: <https://doi.org/10.3329/jbcps.v41i1.63265>

## Introduction:

‘Coarctation’ is derived from the Latin word ‘coarctatio’, which means a drawing together to make tight.<sup>1</sup>Coarctation of the aorta (CoA) is a congenital narrowing of the aorta, usually occurring just beyond the left subclavian artery.<sup>2</sup>Nevertheless, it can occur in many other locations of the thoracic and abdominal aorta.<sup>3</sup> CoA was first described by Giovanni Morgagni, an Italian anatomist, in the 18th century.<sup>4</sup>Coarctation is found in 6-8% of patients with congenital heart disease.<sup>2</sup> Males are predominantly affected in CoA than females.<sup>5</sup>Karyotype screening is recommended for females with the diagnosis of coarctation.<sup>2</sup> Patients with

genetic syndromes like Turner syndrome and William syndrome are frequently associated with CoA.<sup>6</sup> Offspring and other first-degree relatives diagnosed with an obstructive left heart lesion are at ten times the risk of coarctation and other cardiac lesions others.<sup>7</sup> It is commonly associated with cardiac and extra-cardiac anomalies like a bicuspid aortic valve, ventricular septal defect, patent ductus arteriosus, transposition of great arteries, etc.<sup>8</sup>

Upper extremity hypertension is the most common presenting symptom among adults with CoA.<sup>9</sup> Frequent headaches or claudication of the lower extremities with exertion are also common in this group.<sup>10</sup> The commonest findings suggestive of coarctation are diminished and/or delayed lower extremity pulses and a systolic pressure gradient between the upper and lower extremities.<sup>11</sup> Over the time, compensatory collaterals are formed around the coarctation segment.<sup>12</sup> Usually, a systolic murmur with diastolic continuation is heard in the left infrascapular region. The ECG, as well as Echocardiogram, usually demonstrate left ventricular hypertrophy. Echocardiogram also reveals mitral regurgitation, left atrial (LA) dilation with elevated LA pressures, and the narrowing in the aortic arch at isthmus level with hypoplastic arch. CT scanning and MRI usually provide detailed anatomy of the aortic arch before and after treatment.<sup>13</sup> We herein present a case of a young lady with CoA with aortic aneurysm, treated by interposition tube graft with LSA debranching.

- a. Dr. Saikat Das Gupta, Junior Consultant, Department of Cardiac Surgery, Square Hospital Limited, Dhaka.
- b. Brig. Gen. (Rtd) Professor Mozibul Haque, Senior Consultant, Department of Cardiac Anesthesia, Square Hospital Limited, Dhaka.
- c. Dr. Jagodananda Roy, Associate Consultant, Dept. of Cardiac Anaesthesia, Senior Consultant, Department of Cardiac Anesthesia, Square Hospital Limited, Dhaka
- d. Dr. Bhabesh C Mandol, Consultant, Department of Cardiac Anesthesia, Square Hospital Limited, Dhaka.
- e. Dr. Mesbah Uddin, Junior Consultant, Department of Cardiac Surgery, Square Hospital Limited, Dhaka.
- f. Dr. PK Chanda, Senior Consultant, Department of Cardiac Surgery, Square Hospital Limited, Dhaka.

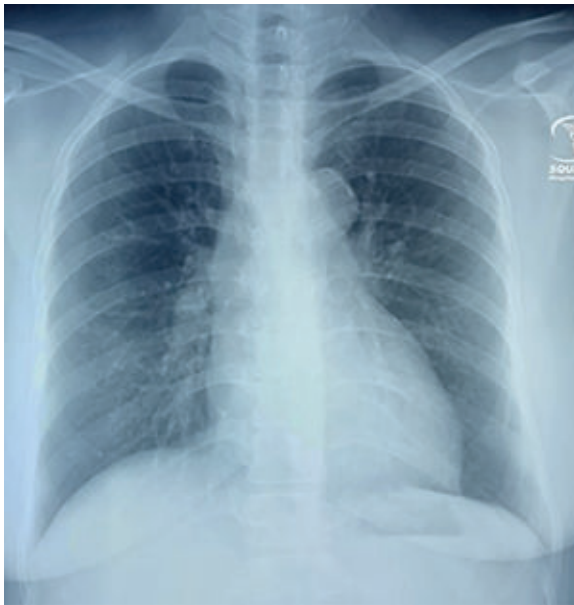**Address of Correspondence:** Dr. Saikat Das Gupta, Junior Consultant, Department of Cardiac Surgery, Square Hospital Limited, Dhaka

Mobile: 01715-739487, E-mail: [saikatdasgupta@ymail.com](mailto:saikatdasgupta@ymail.com)

**Received:** 10 January, 2021      **Accepted:** 24 Nov., 2022

**Case report:**

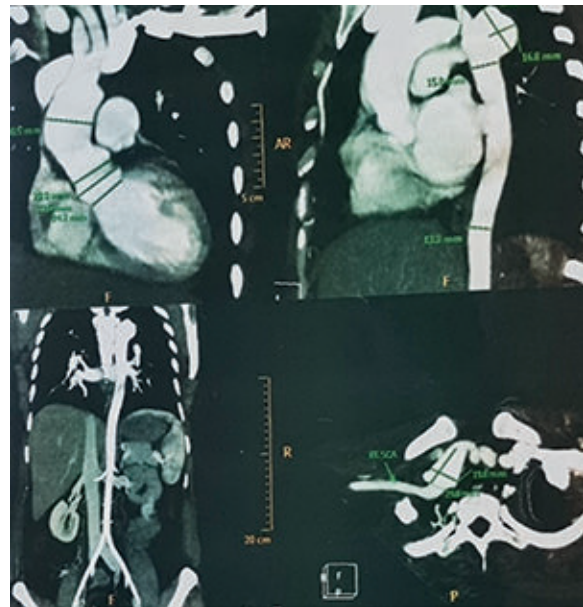
A 30-year-old hypertensive, non-diabetic, lady presented to the emergency department with the complaints of discomfort and heaviness in the chest and right upper limb for the last 2/3 months. The presenting symptoms aggravated over the last few days. Her pain was non-radiating and did not subside by rest, drugs, and a change of posture. She was on beta-blocker and ARB (angiotensin receptor blocking agent) over the past few years for hypertension. She had no past history of cerebrovascular accident (CVA), chronic kidney disease (CKD), chronic obstructive pulmonary disease (COPD), bronchial asthma, or any major surgery. She had a healthy kid of 10 years old.



**Fig.-1:** Pre-operative X-ray chest PA

On physical examination, her pulse rate was 76 beats/min, and regular, radial blood pressure was 170/70 mm of Hg. Peripheral pulses on the left side were absent in both the upper and lower limbs. She had a right radio-femoral delay and radio-femoral systolic blood pressure gradient of > 40mm of Hg. Her biochemical investigations revealed no abnormality except her CRP was 28.9 mg/L, and ESR was 102 at the end of the 1st hour. Her serum creatinine was 1.4mg/ dl and eGFR calculated was 51 ml/min with NT-proBNP1230 pg/ml. Doppler echocardiography revealed coarctation of the aorta; a 3.5 mm thick ridge presented distal to SCA with pressure gradient across the coarctation 70/20 mm of

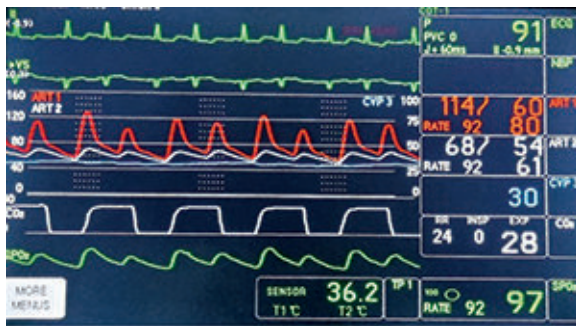Hg and an aneurysmal dilatation of the post stenotic DTA. Global LV hypokinesia with moderate LV systolic dysfunction (LVEF-35%). Mild concentric LVH. Mild to moderate MR. Trace TR (PASP-30 mm of Hg). She underwent an ECG-gated computed tomography (CT) scan of the heart and aorta, showing CoA extending from the origin of the left common carotid (LCC) artery to the origin of the left subclavian (LSA) artery. A small aneurysm at the proximal part of the descending thoracic aorta with calcification was also present, and post-coarctation aorta with branches showing no abnormality. Her predicted EUROScore II for in-hospital mortality was 1.79%.



**Fig.-2:** Pre-operative CT scan showing CoA and aneurysm at different dimensions

She was prescribed oral Bisoprolol 5 mg 12 hourly and Losartan potassium 50 mg once daily along with oral nitrates to control her blood pressure. After optimization of the patient's present condition, general anesthesia was administered on March 2021. Central venous line (Right, jugular), right radial and left femoral arterial lines, rectal and nasopharyngeal temperature probes along with NIRS (near-infrared spectroscopy) were established to monitor the patient during surgery. She was operated upon with right-sided single lung ventilation at the right lateral position. Aorta was approached through left postero-lateral thoracotomy at 3rd intercostal space. After careful dissection, the aorta was found grossly

narrowed distal to the left common carotid artery. A small aneurysmal bulging of the aorta was seen distal to the narrowed segment from where LSA arises. Controls were taken around distal arch (between LCC/LSA), distal aorta, left subclavian artery. Aorta was clamped at distal and proximal control sites after heparinization, and bulldog clamps were applied to LSA. Aorta was transected and was replaced by an interposition tube graft using a 20 mm dacron tube sutured with running polypropylene. Left subclavian artery debranching was done with a 10 mm tube graft sutured with running polypropylene. On completion of correction, protamine was administered to reverse the effect of heparin. After proper hemostasis thoracotomy wound was closed in layers leaving two drain tubes in situ. She was then shifted to ICU without any inotropes and was extubated on the subsequent morning.



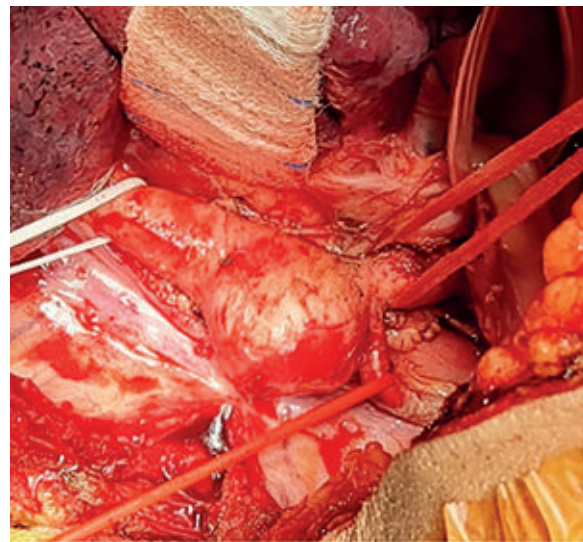
**Fig.-3:** Gross blood pressure differences between femoral (white) and radial (red) arteries before correction of CoA.

Post-operative color Doppler echocardiography revealed normal flow in DTA with normal LV systolic function (LVEF-55%). and good RV function. No pericardial effusion or intracardiac thrombus was seen. She was discharged home on the 7th post-operative day. During discharge from the hospital, her INR was 1.13 without Warfarin. She was advised to continue beta-blocker and anti-platelets.

#### Discussion:

Crafoord (1944), was performed the first therapeutic, surgical intervention of COA.<sup>4</sup> Generally accepted indications for invasive treatment of native coarctation are non-invasive systolic blood pressure gradient of >20 mmHg between upper and lower limbs, the peak-to-peak trans-catheter gradient of  $\geq$  20 mmHg across the coarctation site, significant left ventricular hypertrophy,

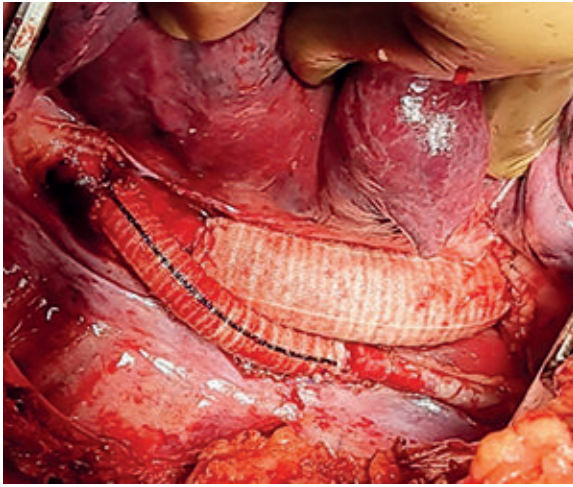
left ventricular systolic dysfunction and uncontrolled systemic hypertension in the background of coarctation of the aorta.<sup>8,9</sup> In our patient, the right radio-femoral systolic pressure gradient was >40 mm of Hg. By the 3rd-4th decade of life, patients with CoA, if not treated, usually tends to develop premature coronary artery disease, ventricular dysfunction, aortic aneurysm/dissection, and cerebral vascular disease.<sup>3</sup> Our patient had an aortic aneurysm in the descending thoracic aorta just distal to the CoA segment, which was resected and replaced with interposition tube graft. She also had moderate left ventricular (LVEF-35%) dysfunction that improved utterly (LVEF-55%) after repair.



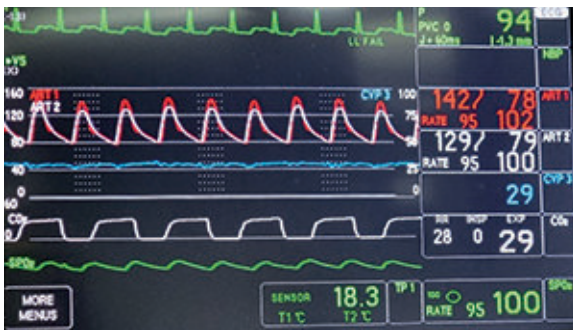**Fig.-4:** Intra operative picture showing coarctation segment with aneurysm and controls applied on different arteries.

The corrective surgery includes end-to-end anastomosis, extended end-to-end anastomosis, subclavian flap repair, interposition graft, coarctation resection, prosthetic patch augmentation, and extra-anatomic bypass.<sup>14</sup> Surgical techniques depend on CoA anatomy, site of coarctation, and patient's age. Neonates and children are most benefited by end-to-end and extended end-to-end anastomosis.<sup>15</sup> Gross<sup>16</sup> described resection of coarctation and replacement with an interposition graft in 1951, which was an appropriate technique for adult patients, especially those with aneurysm or re-coarctation after primary repair.<sup>17</sup> We replaced the diseased unhealthy portion of the aorta with dacron graft and de-branched the LSA as proximal LSA arose from the aneurysmal part of the aorta.





**Fig.-5:** Interposition tube graft replacing distal arch of the aorta and proximal DTA with debranching of the LSA.



**Fig.-6:** Approximation of femoral (white) with radial (red) arterial blood pressure after surgical correction of CoA.

Overall surgical mortality after CoA repair is very low.<sup>18</sup> After repair of coarctation, stroke, paradoxical hypertension, recurrent laryngeal nerve injury, bleeding, subclavian steal, and residual coarctation are the immediate complications. Long-term complications after the repair include recurrent CoA, formation of an aneurysm, persistent hypertension, and infrequently spinal cord ischemia are notable.<sup>19</sup> Any of the complications mentioned did not happen to our patient so far. Months after surgery our patient is doing normal physical activities without any difficulty.

#### **Conclusion:**

Coarctation of the aorta cannot be prevented, but timely referral to a cardiologist / cardiac surgeon is

recommended. Successful and timely repair reverted the patient to normal healthy life with normal LV function. In the postoperative period patient should perform regular physical exercise to maintain a healthy life and must continue a regime of prophylactic antibiotics to guard against endocarditis. Lifelong follow-up is vital once the coarctation is repaired.

#### **Acknowledgments:**

The authors would like to acknowledge Dr. Taurat Tamalika Hoque, Dr. Sawanthee Joarder, Dr. Farzana Nowshin, Dr. Iftekhar Ratul, Mr. Mohammad Kamal Uddin, Mr. Tanvir Ahmed for their relentless effort during surgery, data collection, and Md. Rana Masud for his tenacious radiological support.

#### **Disclosure:** None

#### **References:**

1. Ho SY, Anderson RH. Coarctation, tubular hypoplasia, and the ductus arteriosus. Histological study of 35 specimens. *Br Heart J.* 1979;41(3):268-274. <https://doi.org/10.1136/hrt.41.3.268> PMID:426975 PMCID:PMC482025
2. Law MA, Tivakaran VS. Coarctation of the Aorta. [Updated 2021 Aug 11]. In: StatPearls [Internet]. Treasure Island (FL): StatPearls Publishing; 2022 Jan-. Available from: <https://www.ncbi.nlm.nih.gov/books/NBK430913/>
3. Beckmann E, Jassar AS. Coarctation repair-redo challenges in the adults: what to do?. *J Vis Surg.* 2018;4:76. Published 2018 Apr 23. <https://doi.org/10.21037/jovs.2018.04.07> PMID:29780722 PMCID:PMC5945897
4. Kvitting JP, Olin CL: Clarence Crafoord: a giant in cardiothoracic surgery, the first to repair aortic coarctation. *Ann Thorac Surg.* 2009, 87:342-346. <https://doi.org/10.1016/j.athoracsur.2008.08.072> PMID:19101336
5. Report of the New England Regional Infant Cardiac Program. *Pediatrics.* 1980;65(2):377-461. <https://doi.org/10.1542/peds.65.2.377>
6. Cramer JW, Bartz PJ, Simpson PM, Zangwill SD: The spectrum of congenital heart disease and outcomes after surgical repair among children with Turner syndrome: a single-center review. *PediatrCardiol.* 2014, 35:253-260. <https://doi.org/10.1007/s00246-013-0766-5> PMID:23933717

7. Yetman A T, Starr L, Sanmann J, Wilde M, Murray M, Cramer JW, Clinical and Echocardiographic Prevalence and Detection of Congenital and Acquired Cardiac Abnormalities in Girls and Women with the Turner Syndrome. *The American journal of cardiology*. 2018 Jul 15.  
<https://doi.org/10.1016/j.amjcard.2018.03.357>  
PMid:29731120
8. Nguyen L, Cook SC. Coarctation of the Aorta: Strategies for Improving Outcomes. *CardiolClin*. 2015;33(4): 521-vii.  
<https://doi.org/10.1016/j.ccl.2015.07.011>  
PMid:26471817
9. Feltes TF, Bacha E, Beekman RH, et al.: Indications for cardiac catheterization and intervention in pediatric cardiac disease: a scientific statement from the American Heart Association. *Circulation*. 2011, 123:2607-2652.  
<https://doi.org/10.1161/CIR.0b013e31821b1f10>  
PMid:21536996
10. Torok RD, Campbell MJ, Fleming GA, Hill KD. Coarctation of the aorta: Management from infancy to adulthood. *World J Cardiol*. 2015;7(11):765-775.  
<https://doi.org/10.4330/wjc.v7.i11.765>  
PMid:26635924 PMCID:PMC4660471
11. Strafford MA, Griffiths SP, Gersony WM. Coarctation of the aorta: a study in delayed detection. *Pediatrics*. 1982;69(2):159-163.  
<https://doi.org/10.1542/peds.69.2.159>  
PMid:7058089
12. Hanneman K, Newman B, Chan F, Congenital Variants and Anomalies of the Aortic Arch. *Radiographics: a review publication of the Radiological Society of North America, Inc*. 2017 Jan-Feb [PubMed PMID: 27860551]  
<https://doi.org/10.1148/rg.2017160033>
13. Kaya U, Colak A, Becit N, Ceviz M, Kocak H, Surgical Management of Aortic Coarctation from Infant to Adult. *The Eurasian journal of medicine*. 2018 Feb [PubMed PMID: 29531485]  
<https://doi.org/10.5152/eurasianjmed.2017.17273>  
PMCID:PMC5843446
14. Doshi AR, Chikkabyrappa S. Coarctation of Aorta in Children. *Cureus*. 2018;10(12):e3690. Published 2018 Dec 5.  
<https://doi.org/10.7759/cureus.3690>
15. Yin K, Zhang Z, Lin Y, et al.: Surgical management of aortic coarctation in adolescents and adults. *Interact Cardiovasc Thorac Surg*. 2017, 24:430-435.  
10.1093/icvts/ivw353
16. Gross RE. Treatment of certain aortic coarctations by homologous grafts; a report of nineteen cases. *Ann Surg* 1951; 134: 753-768  
<https://doi.org/10.1097/00000658-195110000-00020>  
PMid:14878385 PMCID:PMC1802983
17. Charlton-Ouw KM, Codreanu ME, Leake SS, Sandhu HK, Calderon D, Azizzadeh A, Estrera AL, Safi HJ. Open repair of adult aortic coarctation mostly by a resection and graft replacement technique. *J Vasc Surg* 2015; 61: 66-72  
<https://doi.org/10.1016/j.jvs.2014.06.010>  
PMid:25041987
18. Zussman ME, Hirsch R, Herbert C, Stapleton GE: Transcatheter intervention for coarctation of the aorta. *Cardiol Young*. 2016, 26:1563-1567.  
<https://doi.org/10.1017/S1047951116001694>  
PMid:28148313
19. Cardoso G, Abecasis M, Anjos R, Marques M, Koukoulis G, Aguiar C, Neves JP: Aortic coarctation repair in the adult. *J Card Surg*. 2014, 29:512-518.  
<https://doi.org/10.1111/jocs.12367>  
PMid:24894975