

COVID-19 Presenting as Acute Abdomen- A Study of 3 Cases

S PAUL^a, MK ISLAM^b, FUH CHOWDHURY^c, FR CHOWDHURY^d

Abstract:

COVID-19 is a multisystem disease and sometimes patient can present with life threatening extra-pulmonary manifestations. Amongst GI symptoms nausea, vomiting, abdominal pain and diarrhoea are common. Severe hepatobiliary manifestations like acute pancreatitis, acute hepatitis and cholecystitis are rare in SARS-CoV-2 infection. In this case series we described three cases presented with hepatobiliary manifestations. All of them had acute abdominal pain and finally proven to be the case of acute pancreatitis and acalculous cholecystitis in addition to classical COVID-19 symptoms. Two of them had severe symptoms and required

high volume of oxygen, while one case (acalculous cholecystitis) had mild symptom only. All of them recovered successfully. High degree of clinical suspicion is required while managing atypical presentation of COVID-19 cases. This is also vital to refer the cases to advance care hospitals in time to ensure multidisciplinary care.

Key words: COVID-19, Hepato-biliary, Acute pancreatitis, Acalculous cholecystitis, ACE2 receptor

(J Bangladesh Coll Phys Surg 2023; 41: 320-324)

DOI: <https://doi.org/10.3329/jbcps.v41i4.68949>

Case Description

Emerging data from different parts of the world revealed that SARS-CoV-2 virus can invade any organ of the body where angiotensin-converting enzyme 2 (ACE2) receptors are abundant, as the virus uses this receptor for entry in the cell. The epithelium of the gastrointestinal (GI) tract and hepato-biliary system is rich in ACE2 receptor. Thus, GI manifestations like anorexia, nausea, abdominal pain, vomiting, and diarrhoea are also common. There has been report of the presence of the virus in stool and ano-rectal swab.^{1,2} ACE2 receptors are also abundant in hepatobiliary and pancreatic

epithelium. However, involvement of hepatobiliary system and pancreas by COVID-19 is rarely reported.³ Here we described a series of COVID-19 cases presented with acute abdomen and subsequently confirmed to develop acute pancreatitis and acalculous cholecystitis.

Case 1

A 57-year-old non-diabetic, normotensive, non-obese man presented to the COVID emergency of Bangabandhu Sheikh Mujib Medical University (BSMMU) with acute severe upper abdominal pain radiating to back and vomiting for 24 hours. He was suffering from an episode of fever, cough, malaise and anorexia for last five days for which he was on symptomatic treatment. He gives no history of alcoholism, smoking and similar symptoms in the past. On admission he was dehydrated, febrile (temp 101 !) with severe tenderness in the epigastrium. There was no organomegaly or ascites. Chest examination was unremarkable including vitals. He was given conservative treatment with IV fluids, analgesics, and antibiotics (ceftriaxone). Nasal swab for RT-PCR for COVID-19 came positive. His routine laboratory investigations showed high serum amylase (>4 times) and high serum lipase (>2 times) (Table 1). CT abdomen revealed swollen and oedematous pancreas with mildly dilated main pancreatic duct (Fig 1A). Liver, gall bladder and biliary channels were normal. Fasting triglyceride level were also normal. Three days after admission

- a. Dr. Shrehash Paul, Senior Resident, Department of Internal Medicine, Bangabandhu Sheikh Mujib Medical University, Dhaka, Bangladesh
- b. Dr. Md. Khairul Islam, Junior Consultant, Department of Medicine, Dhaka Medical College Hospital, Dhaka, Bangladesh
- c. Dr. Forhad Uddin Hasan Chowdhury, Registrar, Department of Medicine, Dhaka Medical College Hospital, Dhaka, Bangladesh
- d. Dr. Fazle Rabbi Chowdhury, Associate Professor, Department of Internal Medicine, Bangabandhu Sheikh Mujib Medical University, Dhaka, Bangladesh & Visiting Research Affiliate, Mahidol-Oxford Tropical Medicine Research Unit (MORU), Bangkok, Thailand

Address of Correspondence: Dr. Shrehash Paul, Medical Officer, Infectious Disease Hospital, Mohakhali, Dhaka-1212, dr.shrehash@gmail.com, +8801714867673.

Received: 11 April, 2023

Accepted: 18 July 2023

patient developed breathlessness with fall of oxygen saturation. He was put on oxygen through nasal cannula along with other ongoing management. HRCT of chest showed multiple, bilateral ground glass opacities, >50% lung involvement (Fig 1B). He was labelled as a case of severe COVID-19 infection with acute pancreatitis. His breathlessness worsens rapidly and was put on non-re-breather (NRB) mask with 15 li/min oxygen along with high doses of I/V dexamethasone (15 mg/day) and low molecular weight heparin. His oxygen requirements gradually declined over the next few days with gradual resolution of his pulmonary and GI symptoms. Laboratory parameters also became normal and he experienced an uneventful recovery. The patient visited BSMMU post-COVID follow up clinic two months after discharge with new onset diabetes mellitus.

Case 2

A 58-year-old hypertensive, non-diabetic, non-obese businessman presented to surgery outpatient department with the complaints of upper abdominal pain and several episodes of vomiting for last four days. Abdominal pain was colicky in nature, moderate in severity with radiation to tip of the right shoulder. He denied any history of fever, cough, bowel disturbances and respiratory distress. He was advised for admission under department of surgery. A routine RT-PCR for COVID-19, USG of whole abdomen and routine laboratory tests were sent. He was shifted to red zone (COVID unit) when the RT-PCR result came positive. On examination his pulse rate was 92 beats per min, BP-100/60 mm of hg, respiratory rates 20 breaths per min. On abdomen there was tenderness in the right hypochondriac region with positive murphy's sign. There was no organomegaly including gall bladder and no ascites. Conservative management of acute abdomen was started including 0.9% normal saline, intravenous antibiotics (ceftriaxone), analgesics and anti-emetics. His routine laboratory test revealed neutrophilic leucocytosis with high amylase (Table 1). USG showed distended and inflamed gall bladder without any calculus and normal pancreas. CT scan of abdomen was performed, and it revealed features of acalculous cholecystitis (hugely distended gall bladder with sludge within it) with normal pancreas (Fig 1C). Patient's

abdominal symptoms was improved with medical management but subsequently he developed mild respiratory symptoms (cough and sore throat) without desaturation of oxygen. After 10 days of hospital admission, he became asymptomatic and was discharged in a stable condition.

Case 3

A 63-year-old diabetic, hypertensive, hypothyroid, non-obese man presented to the triage of COVID unit of BSMMU with respiratory distress for two days which was preceded by fever, cough, myalgia, anosmia of five days. Patient received symptomatic treatment including antipyretics at home. On admission he was dyspnoeic with SPO₂ of 88% on room air. His respiratory rate was 34 breaths per min, pulse 98 beats per min, Blood pressure 125/70 mm of hg. Chest examination revealed crepitation over the base of the lungs. Patient was admitted in the yellow zone of the COVID unit. The next day, nasal swab for RT-PCR for COVID-19 came positive. Routine laboratory test along with HRCT chest was done. Laboratory investigations showed high neutrophil lymphocyte ration, high CRP and D-dimer, very high LDH and ferritin. Serum amylase was also found elevated (Table 1). In HRCT of chest, there were bilateral ground glass opacities with crazy paving appearance in periphery (sub-pleural) and basal zone (Fig 1D). He was immediately treated with high flow oxygen (15 L/min), antibiotics, antiviral-Remdesivir, dexamethasone (6 mg/day for 10 days) and low molecular weight heparin. Next day patient developed severe upper abdominal pain and vomiting for several times. On examination there was diffuse tenderness over the right hypochondriac region. CT abdomen was done which revealed distended gall bladder with features of cholecystitis. Pancreas and other parts of hepato-biliary system was un-remarkable (Fig 1E). Abdominal pain was managed conservatively, and symptoms improved within three days but his pulmonary condition deteriorated with increasing need for oxygen. Ultimately patient was put on high flow nasal cannula (HFNC) in a flow of up to 50L/min. After a week patients oxygen requirement started to decrease and weaning of oxygen therapy was done. Patient was discharged a week after in a sound condition. On two months follow up, he was doing fine.

Table-I

<i>Biochemical and haematological findings of the cases at the time of admission</i>			
Investigations	Case 1	Case 2	Case 3
Haemoglobin (gm/dl)	11.3	12.5	11.8
WBC (per mm ³)	12,000	10,800	13,000
Differential count	Neutrophil- 82% Lymphocyte- 11%	Neutrophil-78% Lymphocyte-15%	Neutrophil-80% Lymphocyte-9%
Platelets (per mm ³)	240,000	280,000	252,000
SGPT (U/L)	24	21	34
SGOT (U/L)	36	26	32
S. Bilirubin (mg/l)	0.57	0.8	0.76
S. LDH (U/L)	578	264	963
S. Ferritin (ng/ml)	1596.5	376	2856
D-Dimer (µg/ml)	4.40	2.5	4.37
CRP (mg/l)	177	34.5	41.8
S. Creatinine (mg/dl)	0.85	0.9	1.1
HbA1C	6.8%	5.6	6.9
S. Amylase (U/L) (normal-up to 220)	940.4	624	514
S. Lipase (U/L) (normal up to 60)	141	184	194
S. Triglyceride (mg/dl)	205		

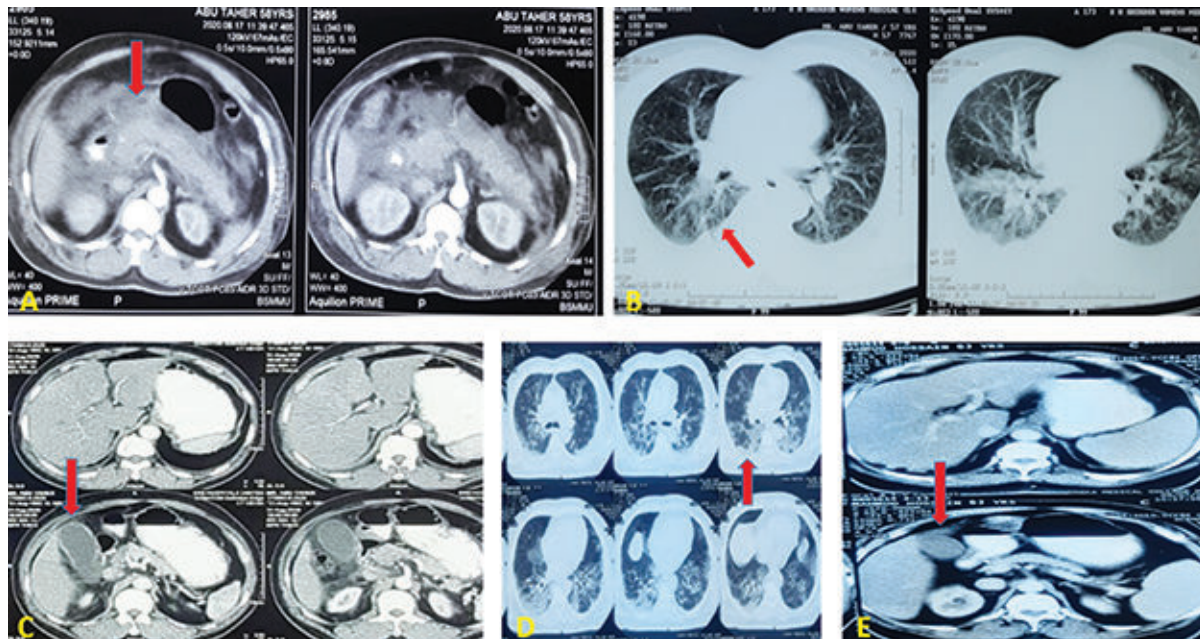


Fig.-1: Imaging of the different system of the cases. 1 (A): CT abdomen showing swollen and oedematous pancreas (Red arrow), 1 (B): HRCT chest revealed bilateral ground glass opacities in both basal and peripheral region (Red arrow), 1 (C): CT abdomen showing hugely distended gall bladder with normal liver and pancreas (Red arrow), 1 (D): HRCT of chest showing bilateral ground glass opacities with crazy paving appearance in periphery (sub-pleural) and basal zone (Red arrow) and 1 (E): CT abdomen showing distended gall bladder with normal liver and pancreas (Red arrow).

Discussion

ACE2 receptor is the route of entry to cell for SARS-Cov-2 virus. These receptors are abundant in the lungs. But it is found all over the body especially intestine, liver, kidneys etc.⁴ Though pulmonary symptoms are the commonest mode, COVID-19 can have a varied presentation.. There are few meta-analysis showed pattern of common GI symptoms includes loss of taste sensation, anorexia, nausea, vomiting, abdominal pain and diarrhea.¹

Severe GI and hepato-biliary involvement like acute pancreatitis and cholecystitis are rare.^{3,5-7} Acute pancreatitis due to other viruses are well reported. A number of viruses can cause acute pancreatitis. Out of them Mumps, Coxsackie, Measles, Epstein bar virus, Hepatitis A virus, Cytomegalovirus are common.⁵ Novel SARS-CoV-2 is a RNA virus with high infectivity. In the first case there was a striking temporal relationship with COVID-19 and development of pancreatitis. However, other possible causes of acute pancreatitis were excluded (drugs, hypertriglyceridemia, gall stone, recent surgery). It is already established that COVID-19 pathogenesis is mediated by ACE2 receptor which is abundant in the pancreas.^{2,6} Though the exact mechanism of pancreatic injury is still unclear, but there are few underlying possible mechanism. First, direct cytopathic effect of the virus and second mechanism is immune inflammatory effect due to different cytokines released during moderate to severe COVID-19.³

Reports regarding acalculous cholecystitis due to COVID-19 are extremely rare.⁷⁻⁹ ACE2 receptors are also abundantly distributed in the gall bladder epithelium.¹⁰ This explain the viral entry to gall bladder. In the second case which was a mild COVID case, presented with a typical feature of acute cholecystitis. This case was supposed to be managed in the surgery ward. However, on routine testing the patient was found COVID-19 positive. In the last case, patient presented with severe COVID-19 infection and later developed severe upper abdominal pain with high amylase. Keeping pancreatitis in mind urgent CT abdomen was done, however, pancreas was found normal. The CT revealed it as a case of acalculous cholecystitis. In both the cases, there

was no other risk factors of developing cholecystitis and temporal relationship with COVID-19 was clear.

High index of clinical suspicion is important for prompt diagnosis of such conditions. These extra-pulmonary complicated cases often required multi-disciplinary approach. Therefore, every COVID-19 unit should have multi-care facilities including surgery. Some patients may develop acute emergency and require surgical intervention. A dedicated surgical team should also be present so that timely intervention can made to save lives.

Authors' contributions

FRC and SP wrote the primary draft. FRC, SP, MKI and FUHC was directly involved in the diagnosis and management of the cases. All the authors have gone through the manuscript.

Funding

No funding or grant was received from any source for this publication.

Availability of data and materials

Data sharing is not applicable to this article as no data sets were generated or analysed during the current study.

Declarations

None declared

Ethical approval

Not applicable as this article contains information of only one patient

Consent

Written informed consent was taken from the patient for publication of this case report and accompanying images.

Conflict of interest

The authors declared that there is no conflict of interest.

References:

1. Rokkas T. Gastrointestinal involvement in COVID-19: a systematic review and meta-analysis. *Ann Gastroenterol* 2020;33(4):355–65.
2. Wang W, Xu Y, Gao R, Lu R, Han K, Wu G, et al. Detection of SARS-CoV-2 in Different Types of Clinical Specimens. *JAMA* 2020;323(18):1843–4.
3. Aloysius MM, Thatti A, Gupta A, Sharma N, Bansal P, Goyal H. COVID-19 presenting as acute pancreatitis.

- Pancreatol Off J Int Assoc Pancreatol 2020; 20(5): 1026–7.
4. Bhalla V, Blish CA, South AM. A historical perspective on ACE2 in the COVID-19 era. *J Hum Hypertens* 2020; 1-5. doi: 10.1038/s41371-020-00459-3.
 5. Kottanattu L, Lava SAG, Helbling R, Simonetti GD, Bianchetti MG, Milani GP. Pancreatitis and cholecystitis in primary acute symptomatic Epstein-Barr virus infection - Systematic review of the literature. *J Clin Virol* 2016; 82:51–5.
 6. Wang F, Wang H, Fan J, Zhang Y, Wang H, Zhao Q. Pancreatic Injury Patterns in Patients With Coronavirus Disease 19 Pneumonia. *Gastroenterology* 2020 ;159(1):367–70.
 7. Ying M, Lu B, Pan J, Lu G, Zhou S, Wang D, et al. COVID-19 with acute cholecystitis: a case report. *BMC Infect Dis* 2020;20(1):437.
 8. Barabino M, Piccolo G, Trizzino A, Fedele V, Ferrari C, Nicastro V, et al. COVID-19 outbreak and acute cholecystitis in a Hub Hospital in Milan: wider indications for percutaneous cholecystostomy. *BMC Surg* 2021;21(1):180.
 9. Famularo G, Spada PL. COVID-19-related cholecystitis. *Clin Res Hepatol Gastroenterol* 2021;45(2):101635.
 10. Zong H, Yin B, Zhou H, Cai D, Ma B, Xiang Y. Loss of angiotensin-converting enzyme 2 promotes growth of gallbladder cancer. *Tumour Biol J Int Soc Oncodevelopmental Biol Med* 2015 ;36(7):5171–7.