

Idiopathic Intracranial Hypertension Developing After Levothyroxine Replacement in a Patient with Acquired Primary Hypothyroidism- A Case Report

MA HAQUE¹, LS SHARMIN², QT ISLAM³

Summary:

Idiopathic intracranial hypertension (IIH) is the persistent increase in intracranial pressure in the absence of any intracranial lesions. Though termed idiopathic IIH is known to be associated with a wide variety of disease conditions and drugs i.e. SLE, adrenal insufficiency, Cushing disease, hypoparathyroidism, hypothyroidism, iron deficiency, vitamin A, tetracycline, nalidixic acid, steroid withdrawal

Introduction:

Idiopathic Intracranial Hypertension (IIH) is the persistent increase in intracranial pressure in the absence of any intracranial lesions: intracranial tumor, hydrocephalus, intracranial infections, dural sinus thrombosis or hypertensive encephalopathy¹

Idiopathic intracranial hypertension corresponds partially to the old term of pseudotumor cerebri; the term benign intracranial hypertension is not used anymore because the

development of the disease can cause complications that are not benign at all. It was first described in the works of Quincke in the 19th century and later by Nonne in 1904, who used the term Pseudotumor Cerebri².

The term of "benign intracranial hypertension" was introduced by Foley in 1955 who defined the disease as "prolonged intracranial hypertension without ventricular abnormality, focal neurological signs, or disturbance of awareness or intellect, the most important symptoms

and many others. IIH is a rare disease, but IIH developing after replacement of levothyroxine is even rarer. Only a handful of cases of IIH associated with levothyroxine therapy have been mentioned in the literature. We are reporting a case of IIH developing after starting levothyroxine replacement and then the literature is reviewed.

(J Bangladesh Coll Phys Surg 2011; 29: 49-51)

being headache of moderate degree, obscurations of vision, diplopia and sometimes tinnitus; marked papilloedema and abducens palsies are the only signs." In 1955 Foley advanced IIH as a diagnosis by exclusion, while in Dandy's diagnosis

criteria, modified by Wall, one of the elements of the diagnosis is the lack of a cause for the increase in intracranial pressure^{3,4}.

The IIH diagnosis is made only after measuring intracranial pressure and full neuroimaging exploration. The diagnosis criteria for IIH are⁵

- CSF pressure is greater than 25 cm H₂O
- Normal CSF
- There are symptoms of increased intracranial pressure: papilloedema, headache, without any signs of neurological localization
- CT scanning or magnetic resonance imaging show a normal cranial-cerebral state, without any clinical or neuroimaging suspicion of venous sinus thrombosis

Because of chance association and to prevent biased reporting, Radhakrishnan et al insisted that, to be included in the list of causally related associations, the following criteria should be met⁶

- At least 2 cases should have been described.
- The reported cases should have met all the criteria for the diagnosis of IIH.
- Intracranial dural sinus thrombosis should have been ruled out with reasonable certainty.

1. Dr. Md. Azizul Haque, Assistant Professor, Department of Medicine, Rajshahi Medical College, Rajshahi
2. Dr. Laila Shamima Sharmin, Medical Officer, Department of Paediatrics, Rajshahi Medical College Hospital, Rajshahi
3. Prof. Quazi Tarikul Islam, Professor, Department of Medicine, Dhaka Medical College, Dhaka

Address of Correspondence: Dr. Md. Azizul Haque, Assistant Professor, Department of Medicine, Rajshahi Medical College, Rajshahi.

Received: 5 September, 2009 **Accepted:** 24 December, 2010

Case report:

A 23 year old non-obese lady presented to department of Medicine, Rajshahi medical College Hospital with the complaints of headache, and blurred vision for two months. The headache was diffuse, non-pulsatile, not associated with nausea or vomiting and only partially relieved by paracetamol. Her headache was persistent throughout the day and night. At first visit, fundus was found to be normal, so her headache was thought to be tension-type headache and amitriptyline was prescribed in a dose of 25 mg at night. She did not respond after 1 month of amitriptyline therapy. Moreover, she developed persistent blurred vision in both eyes. In the next visit, fundoscopy was done again and florid papilloedema was noted. She was not on oral contraceptives, nor did she give history of taking tetracycline, vitamin A, nalidixic acid, steroid or other drugs. MRI of brain with Magnetic Resonance Venography (MRV) was done, which was reported to be normal. CSF study was done which demonstrated increased CSF flow rate, but biochemical and microbiological examination was normal. Because of lack of facility, manometry of CSF to document exact CSF pressure could not be done. She was diagnosed as a case of primary hypothyroidism on the basis of serum T4 level 16.28 (normal 66-181 nmol/L), and TSH level > 100 (normal 0.27-4.2 micro IU/ml) 3 months back. Thyroxine replacement was started at a dose 50 mg per day and then gradually increased to 150 microgram per day. Her thyroid function test became normal after 2 months of thyroxine replacement. She had noted that her headache had started about one month after starting thyroxine replacement therapy. Idiopathic intracranial hypertension was diagnosed on the basis of diagnostic criteria and search for temporal association with thyroxine therapy was started. Hypothyroidism is a recognized association of IIH, but development of IIH after starting thyroxine therapy is documented in a few case reports. To avoid bias and chance association, we have followed the standard procedure advocated by Radhakrishnan et al⁶ for linking IIH with other disease conditions. We found that; though very rare, there are more than 2 cases of IIH associated with thyroxine therapy have been described in the literature.

She was treated with acetazolamide 250 mg twice daily, prednisolone 60 mg for 2 weeks, and repeated therapeutic lumbar puncture. Her headache subsided, and vision improved. She was discharged with acetazolamide and was asked to come to hospital for 2 weekly follow up. She was doing well when last seen.

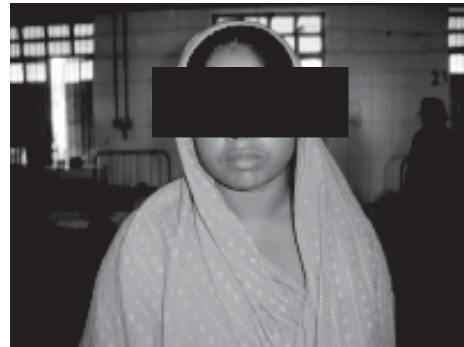

Fig.-1: Patient (Printed with permission)

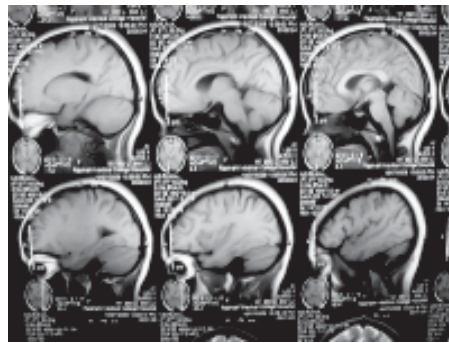


Fig.-2: Normal MRI of brain

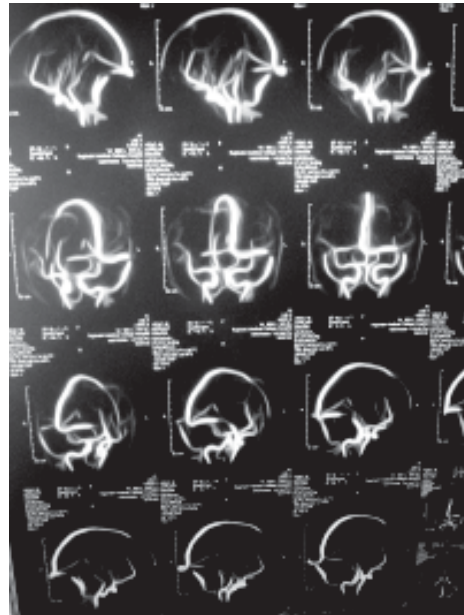


Fig.-3: Normal MRV of brain

Discussion:

The syndrome of increased intracranial pressure (ICP) without ventriculomegaly or mass lesion, and with normal cerebrospinal fluid (CSF) composition, was first

described more than a century ago, yet we still know little about its pathogenesis. It was once labeled as "Pseudotumor Cerebri" but now it is more appropriately called "Idiopathic Intracranial Hypertension" (IIH). It is a relatively common disorder that is commonly missed. In young overweight women, the annual incidence is as high as 20 per 100,000 persons⁷. Current theories include increased resistance to cerebrospinal fluid (CSF) outflow at the arachnoid granulations that line the dural venous sinuses and through which CSF reabsorption is thought to occur by bulk flow. Alternatively, occult cerebral venous outflow abnormalities may produce IIH. Farb and colleagues⁸ have demonstrated that, in a series of 29 patients with IIH, narrowing of the transverse dural venous sinus was demonstrable on MR venography, while none of the 59 control subjects had this finding. These authors suggest that the narrowing is a consequence of elevated intracranial pressure, and, when the narrowing develops, it exacerbates the pressure elevation by increasing venous pressure in the superior sagittal sinus. Bateman has shown that some patients with IIH with normal dural venous drainage have increased arterial inflow suggesting that collateral venous drainage occurs in addition to that provided by the superior sagittal sinus and transverse sinuses⁹. The same investigator measured MR venography and MR flow quantification in cerebral arteries and veins in a series of 40 patients with IIH, of which 21 patients had venous stenosis. The arterial inflow was 21% higher than normal and superior sagittal sinus outflow was normal, resulting in reduced percentage of venous outflow compared to inflow. The remainder of arterial inflow volume is presumed to have drained via collateral venous channels. With clinical remission of symptoms, the arterial inflow volumes returned to normal¹⁰.

IIH developing after starting levothyroxine therapy has been reported by several authors. Patients who are euthyroid while taking thyroxine occasionally develop pseudotumor cerebri shortly after starting hormone replacement for hypothyroidism^{11,12,13,14,15,16}.

Interestingly, most of the patients who developed IIH after starting levothyroxine therapy were from paediatric age group. Our patient and another patient reported by Jacques S et al were adults. Number of total cases reported so far is still too few to comment whether this difference is significant.

It is not clear at all how starting thyroxine therapy might derange the CSF inflow or outflow and requires a lot more research. But, because of repeatedly reported cases over last few decades, it seems possible that the association has a genuine cause-effect basis, not merely

a chance association. However, more questions remain unanswered than answered regarding association of IIH with levothyroxine therapy.

Conclusion:

IIH is a rare cause of headache, IIH developing after starting levothyroxine therapy is even rarer. But, because it is a treatable and potentially dangerous condition, patients with hypothyroidism should be closely monitored regarding development of IIH after starting levothyroxine therapy.

References:

1. Binder DK, Horton JC, Lawton MT, McDermott MW. Idiopathic intracranial hypertension. *Neurosurgery*. 2004; 54(3): 538-51
2. Johnston, I. The historical development of the pseudotumor concept. *Neurosurg Focus*. 2001; 11 (2): Article 2
3. Digre KB, Idiopathic Intracranial Hypertension. *Curr. Treat Options Neurol*. 1999; 1: 74-81.
4. Friedman DI, Jacobson DM. Idiopathic intracranial hypertension. *J Neuroophthalmol*. 24(2): 138-45.
5. Friedman D I, Rausch E A. Headache diagnoses in patients with treated idiopathic intracranial hypertension. *Neurology*. 2002; 58 (10): 1551- 3.
6. Radhakrishnan K, Ahlskog JE, Garrity JA, Kurland LT. Idiopathic intracranial hypertension. *Mayo Clin Proc*. Feb 1994; 69(2):169-80.
7. Durcan FJ, Corbett JJ, Wall M. The incidence of pseudotumor cerebri. Population studies in Iowa and Louisiana. *Arch Neurol* 1988; 45:757-7
8. Farb RI, Vanek I, Scott JN, et al. Idiopathic intracranial hypertension: the prevalence and morphology of sinovenous stenosis. *Neurology*. May 13 2003;60(9):1418-24
9. Bateman GA. Association between arterial inflow and venous outflow in idiopathic and secondary intracranial hypertension. *J Clin Neurosci*. Jun 2006;13(5):550-6
10. Bateman GA. Arterial inflow and venous outflow in idiopathic intracranial Hypertension associated with venous outflow stenoses. *J Clin Neurosci*. Apr 2008; 15(4):402-8
11. Van Dop C, Conte FA, Koch TK, Clark SJ, Wilson-Davis SL, Grumbach MM. Pseudotumor cerebri associated with initiation of levothyroxine therapy for juvenile hypothyroidism. *N Engl J Med*. 1983 May 5;308(18):1076-80.
12. Huseman CA, Torkelson RD. Pseudotumor Cerebri Following Treatment of Hypothalamic and Primary Hypothyroidism. *Am J Dis Child*. 1984; 138(10):927-931
13. Campos SP, Olitsky S. Idiopathic intracranial hypertension after L-thyroxine therapy for acquired primary hypothyroidism. *Clin Pediatr (Phila)*. Jun 1995; 34(6):334-7
14. Williams JB. Adverse effects of thyroid hormones. *Drugs Aging*. 1997 Dec; 11(6):460-9.
15. Raghavan S, DiMartino-Nardi J, Saenger P, Linder B. Pseudotumor cerebri in an infant after L-thyroxine therapy for transient neonatal hypothyroidism. *J Pediatr*. Mar 1997; 130(3):478-80
16. Jacques S, Brigitte G, John C. Benign intracranial hypertension and TSH suppression hormone therapy. *American journal of ophthalmology*. 2002; vol. 134, n 6, pp. 910-911.