

Frequency of Second Mesiobuccal Canal in Permanent Maxillary Molars: An Observational Study

MAH SHEIKH^a, TB BADSHA^b, MMR HOWLADER^c, MMA RAHMAN^d

Abstract:

Background: The success of root canal therapy in endodontics is heavily dependent on identifying a second mesiobuccal canal (MB2) in permanent maxillary molars. A comprehensive understanding of internal anatomy, particularly the recognition of MB2, is crucial for the effective treatment of this commonly encountered tooth. This study aimed to investigate the prevalence and occurrence of the second mesiobuccal canal in permanent maxillary first and second molars.

Methods: This cross-sectional study that was conducted at the Department of Conservative Dentistry & Endodontics, Military Dental Centre Dhaka, Bangladesh from January 2018 to December 2018. The analysis involved a total of 200 maxillary first molars and 200 maxillary second molars. In the initial phase for both groups, teeth were examined with the naked eye followed by microscopic assessment. Data analysis was conducted with MS Office tools.

Introduction:

The maxillary molar, characterized by its substantial volume and intricate root canal anatomy, stands out as the posterior tooth most frequently treated and yet least comprehensively understood.¹ Successful endodontic therapy hinges on the meticulous identification and location of all root canal spaces, coupled with thorough chemo-mechanical preparation and the attainment of a secure seal using inert obturating material at the portal of exit². Post-treatment complications can be traced back

Results: In naked eye observation, the frequency of MB2 canals in the first molar teeth was found 64%, and in the second molar teeth it was found 56%. On the other hand, by microscopic assessment, the frequency of MB2 canals in the first molar teeth was found 96%, and in the second molar teeth, it was found 84%.

Conclusion: The occurrence of the second mesiobuccal canal (MB2) in permanent maxillary first molars is more common than in the second molars. Microscopic assessment proves to be more effective than naked eye assessment for detecting the presence of MB2 in both maxillary first and second molars.

Keywords: Second mesiobuccal canal, MB2, Permanent maxillary molars, Root canal

(J Bangladesh Coll Phys Surg 2024; 42: 133-138)

DOI: <https://doi.org/10.3329/jbcps.v42i2.72351>

- Lt Col Dr Md Abdul Hannan Sheikh, Classified Endodontist & Restorative Dentist, Military Dental Centre Dhaka, Dhaka Cantonment, Bangladesh.
- Dr. Taib Bin Badsha, Private Practitioner, Dhaka, Bangladesh.
- Prof. Md Mujibur Rahman Howlader, Prof. Conservative Dentistry & Endodontics, BSMMU, Dhaka, Bangladesh.
- Prof. Mirza Md Arifur Rahman, Prof. Conservative Dentistry & Endodontics, Holy Family Red Crescent Hospital, Dhaka.

Address of Correspondence: Lt Col Dr. Md Abdul Hannan Sheikh, FCPS, MCPS, D. Conservative, Classified Endodontist & Restorative Dentist, Military Dental Centre Dhaka, Dhaka Cantonment, Bangladesh. Cellphone number: +8801712202400, E-mail address: drhannan65@gmail.com

Received: 23 Dec, 2023

Accepted: 05 March, 2024

to the presence of undetected and subsequently unfilled anatomical spaces within the root canal system, serving as potential sources of infection and contributing to treatment failure.³ Among the enigmatic aspects of endodontics, the elusive “second mesiobuccal” (MB2) canal poses one of the most significant mysteries. Research indicates that teeth undergoing endodontic retreatment tend to harbor more undetected second mesiobuccal (MB2) canals compared to teeth undergoing initial treatment. This observation suggests that the failure to locate, clean, and fill existing MB2 canals contributes to a less favorable prognosis.⁴ The orifice of the second mesiobuccal canal in maxillary molars is typically positioned either mesial to or within the pulpal groove connecting the main mesiobuccal canal and palatal canals, falling within a range of 3.5 mm palatal and 2 mm mesial from the main mesiobuccal canal.^{5,6} Root canal therapy’s primary objective is to establish well-defined access, thoroughly clean and disinfect, and achieve three-dimensional obturation.⁷ Numerous studies have delved into the impact of genetic and ethnic factors on variations in root canal anatomy. Specifically, the morphology of maxillary permanent molars has been a focal point, with a particular emphasis on the presence of a second mesiobuccal root canal in the mesial root.

Investigations conducted by Pecora et al. (1992) [8] and Cleghorn et al. (2006) [9] have reported diverse prevalence rates of the second mesiobuccal canal (MB2) in both maxillaries first and second molars. The intricate morphology of maxillary molars, characterized by most first molars possessing three roots and four canals, has been underscored in studies such as that conducted by Silva et al. (2014) [10]. The cumulative findings from various investigations suggest a consensus that over 50% of maxillary first molars exhibit a second canal (MB2) in the mesiobuccal (MB) root.

Methodology:

This was a cross-sectional study conducted at the Department of Conservative Dentistry & Endodontics, Military Dental Centre Dhaka, Bangladesh from Jan 2018 to Dec 2018. The study encompassed a total of 200 maxillary first molars and 200 maxillary second molars. In the initial phase, the examination of teeth in both groups involved a naked-eye assessment, followed by a subsequent microscopic evaluation. To assess the effectiveness of different detection procedures, we ensured both the naked eye as well as microscopic evaluation for all the participants. The study exclusively included cases aged ≥ 18 years, and prior informed consent was secured from all participating patients. Sample selection followed a purposive sampling technique, following the principles outlined in the Declaration of Helsinki. Exclusion criteria comprised retreatment cases, teeth associated with swelling, those with open apices, calcifications, and resorptions. Comprehensive demographic and clinical information for all participants was meticulously recorded, and data processing, analysis, and dissemination were conducted using MS Office tools. Ethical clearance was obtained from the institutional ethical committee of Military Dental Centre Dhaka, Dhaka Cantonment.

Technique for detecting second mesiobuccal canal

Upon achieving adequate anesthesia and rubber dam isolation, a straight-line access cavity was prepared following standard protocol. The tooth was accessed using a sterile Endo access bur, creating an initial triangular-shaped access cavity. Utilizing an endodontic explorer (DG16, Hu-Friedy), the orifices of the mesiobuccal (MB1), distobuccal, and palatal (P) canals was located, and canal negotiation was performed using 10 or 15 K-files. Hand instruments, in conjunction with copious irrigation using 5.25% sodium hypochlorite, was employed to remove the contents of the pulp chamber and root canal space. The coronal portion of each canal orifice was enlarged using Gates Glidden

drills #1–#3. Subsequently, the triangular shape of the access cavity was modified to a rhomboidal shape to enhance the visibility of any additional canal orifices. Coronal necrosed pulp or restoration was excavated using a sharp excavator and/or a large round bur in a low-speed handpiece. The floor of the pulp chamber was then explored to locate the MB2 canal through two approaches:

Direct Vision:

- Procedure: Access cavities were prepared in a total of 200 cases of maxillary first molars and 200 cases of maxillary second molars using conventional visual aids.
- Record keeping: The number of canals in each root was systematically recorded.
- MB2 canal location: Initially, the orifice of the MB2 canal was identified using an endodontic explorer under direct vision. The explorer was directed from the main mesiobuccal canal toward the palatal canal, with a deviation of 1–2 mm mesially.

Under Surgical Operating Microscope (SOM):

- Procedure: Subsequently, the canal orifices of the 200 maxillary first molars and 200 maxillary second molars underwent a thorough examination using a DOM with x8-x13 magnification.
- Assistance: An endodontic explorer was employed in conjunction with the microscope to precisely locate the MB2 canal.

Dentin within the pulp chamber was meticulously removed within 3 mm from the MB1 canal toward the palatal canal and 1–2 mm mesially, reaching a depth of 2 mm. A small round bur, operated at low speed under magnification ($\times 8$ – $\times 13$), was employed to facilitate the identification of the MB2 canal. Throughout this process, copious irrigation was carried out using a 5.25% sodium hypochlorite solution, with intermittent use of normal saline. Following the identification of the canal orifice, the MB2 canal was negotiated using 06, 08, and 10 K-files. Verification of the presence of the MB2 canal was achieved through working length (WL) determination radiographs. For the MB2 to be considered a separate second mesiobuccal canal, it was only counted when distinct from the MB1 or within 5 mm of the apex if it joined the MB1 during WL determination.

Once the desirable canal orifice was identified with an endodontic explorer, the subsequent steps of the root canal treatment procedure were carried out following standard protocols (see Figure 1).

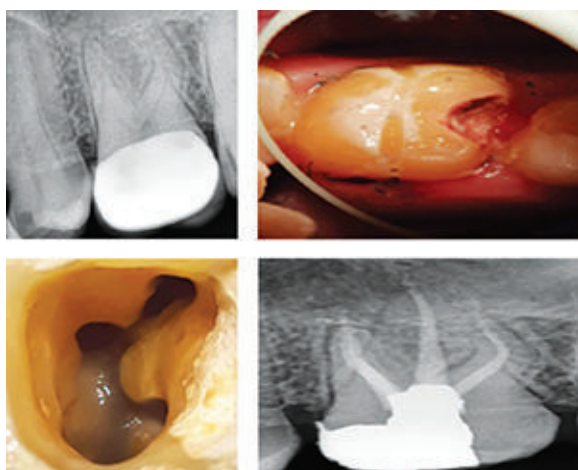


Figure 1: Management of the second mesiobuccal (MB2) canal by root canal treatment

Result:

This current study involved a collective analysis of 200 maxillary first molars and 200 maxillary second molars. The mean age of the total participants was 34.65 ± 12.47 years. Among our total participants, 63% were male whereas the rest 37% were female. In naked eye observation, among 200 permanent maxillary first molar teeth, 128-second mesiobuccal canals were found; so, the frequency of MB2 canals in the first molar teeth was 64%. Through the same manner of observation, among 200 permanent maxillary second molar teeth, 112-second mesiobuccal canals were found; so, the frequency of MB2 canals in the second molar teeth was 56%. By microscopic assessment, among 200 permanent maxillary first molar teeth, 192-second mesiobuccal canals were found; so, the frequency of MB2 canals in the first molar teeth was 96%. Through the same manner of observation, among 200 permanent maxillary second molar teeth, 168-second mesiobuccal canals were found; so, the frequency of MB2 canals in the second molar teeth was 84%. In the comparison of MB2 detection procedures in permanent maxillary molars, both naked-eye examination and microscopic examination showed significant associations with the presence of MB2. For the first procedure, naked-eye examination resulted in 128 teeth with MB2 present, while microscopic examination identified 192 teeth with MB2 present. The odds ratio was 0.074 for the naked-eye examination and 0.242 for the microscopic examination, both with p-values less than 0.001. Similarly, in the second procedure,

naked-eye examination revealed 112 teeth with MB2 present, while microscopic examination detected 168 teeth with MB2 present, also showing significant associations with odds ratios of 0.242 and p-values less than 0.001.

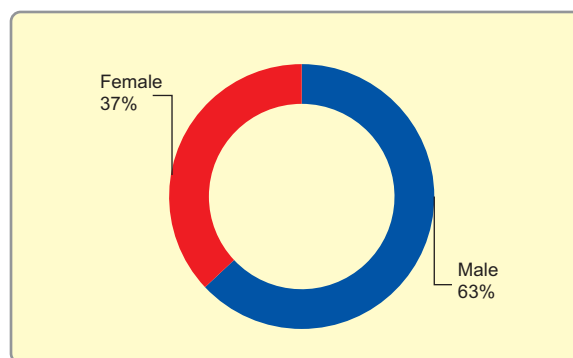


Figure 2: Gender distribution of participants

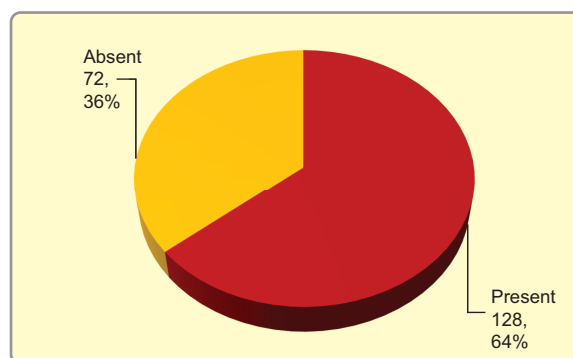


Figure 3: Frequency of MB2 canals in first molars by naked eye observation (n=200)

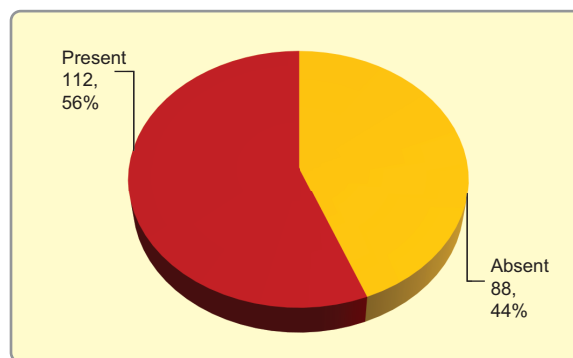


Figure 4: Frequency of MB2 canals in second molars by naked eye observation (n=200)

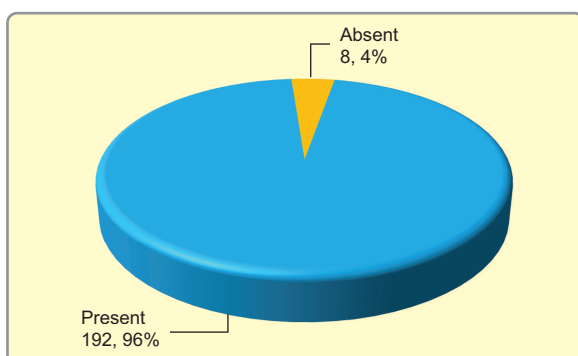


Figure 5: Frequency of MB2 canals in first molars by microscopic assessment (n=200)

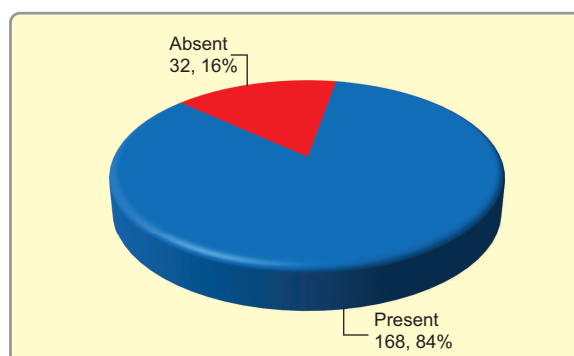


Figure 6: Frequency of MB2 canals in second molars by microscopic assessment (n=200)

Table-I

Comparison between MB2 detecting procedures				
Procedure	Permanent maxillary molars			
	First		Second	
	Present	Absent	Present	Absent
Naked eye	128	72	112	88
Microscopic	192	8	168	32
Odd ratio & P-value	OR: 0.074; P-value <0.001		OR: 0.242; P-value <0.001	

Odd ratio calculation

Discussion:

This study aimed to investigate the frequency of the second mesiobuccal canal in permanent maxillary first and second molars. Our study encompassed individuals aged 18 years or older. Among our total participants, 63% were male, while the remaining 37% were female. Regarding age and gender similar settings were observed in some recent studies [11-14]. Betancourt et al. [15] observed that the MB2 canal was identified in molars of women in 23 cases (56.1% of the total identified) and in 18 cases in men (43.9%), with no significant differences between gender and the presence of the MB2 canal ($p=0.313$). Conversely, a study by Hasan et al. (2014) reported a significantly higher prevalence of MB2 in male patients than in females [16]. In this study, a visual inspection of 200 permanent maxillary first molar teeth without magnification revealed the presence of 128-second mesiobuccal canals, indicating a frequency of 64% for MB2 canals in these first molar teeth. Similarly, using the same visual observation method, among 200 permanent maxillary second molar teeth, 112 second

mesiobuccal canals were identified, resulting in a frequency of 56% for MB2 canals in the second molar teeth. Contrastingly, a recent study [17] demonstrated that the use of magnification loupes significantly enhanced both the detection (50.9%) and negotiation (86.8%) of second mesiobuccal canals in permanent maxillary first molars, surpassing the capabilities of observation with the naked eye alone. In our study, a microscopic assessment of 200 permanent maxillary first molar teeth revealed the presence of 192 second mesiobuccal canals, yielding a frequency of 96% for MB2 canals in the first molar teeth. This underscores the notable improvement in the identification of MB2 canals achieved through microscopic evaluation compared to naked-eye observation. Similarly, using the same method of observation, among 200 permanent maxillary second molar teeth, 168-second mesiobuccal canals were identified, indicating a frequency of 84% for MB2 canals in the second molar teeth. In a study by Buhley et al. [18], the incidence of identifying the MB2 canal among three distinct groups of practitioners was

recently reported as 17%, 63%, and 71%. The first group relied on no magnification, the second group utilized dental loupes, and the third employed an operating microscope. Their study concluded that dental loupes and the operating microscope were equally effective in locating the MB2 canal in maxillary molars. In a Jordanian *in vitro* study, it was found that the MB2 canal orifice could be detected through a clinical access cavity with careful bur use (troughing) up to 56.7% of the time. The utilization of magnification increased the rate to 63.9%, although the difference was not statistically significant. The prevalence of MB2 canals was notably high at 77.3%, and the effectiveness of detecting these canals was 73.3% without loupes and 82.7% with loupes [19]. Previous *in vivo* studies investigating the incidence of the MB2 canal in maxillary molars did not specify whether magnification was used. The majority of *in vivo* research has shown an incidence of the MB2 canal ranging from 18% to 36% [20,21]. Three studies indicated incidences of 64.6%, 77.2%, and 52% [22]. In a recent study [23] the utilization of magnification loupes ($\times 4.0$) increased the detection rate of MB2 canals in maxillary first molars by 50.9%. In another Bangladeshi study [24] it was also reported that ultrasonics offer particular advantages in locating MB2 canals due to the cavitation effect; Despite this benefit, few endodontists utilize ultrasonics for MB2 canal identification, with the majority preferring the use of a bur, and explorer.

Limitation of the study:

This study was limited by its single-center design and relatively small sample sizes. Additionally, the research was conducted over a brief period, raising concerns about the generalizability of the findings to the entire country. As a result, caution should be exercised in extrapolating the study's results to broader populations or drawing definitive conclusions about the overall scenario based on these limited parameters.

Conclusion:

In conclusion, this study highlights a higher prevalence of the second mesiobuccal canal (MB2) in permanent maxillary first molars compared to second molars. Notably, the efficacy of MB2 detection in both types of molars is significantly enhanced when employing microscopic assessment compared to naked-eye evaluation.

Recommendation

These findings underscore the crucial role of advanced visual techniques in endodontic practice, emphasizing the necessity for clinicians to integrate microscopic assessment into their procedures for more precise diagnostics and treatments. This integration has the potential to enhance the overall quality of endodontic care.

Funding: No funding sources.

Conflict of interest: None declared.

Ethical clearance: Ethical clearance was obtained from the institutional ethical committee of Military Dental Centre Dhaka, Dhaka Cantonment.

References:

1. Burns RC. Access openings and tooth morphology: Cohen's pathways of pulp. 8th ed. St Louis, Mo, USA: The Mosby Co.; 2002. p. 173-229.
2. Hess W, Zurcher E. The Anatomy of the Root Canals of the Teeth of the Permanent Dentition. London: John Bane, Sons and Danielsson Ltd.; 1925. p. 4-49.
3. Schilder H. Cleaning and shaping the root canal. *Dent Clin North Am* 1974; 18:269-96.
4. Wolcott J, Ishley D, Kennedy W, Johnson S, Minnich S. Clinical investigation of second mesiobuccal canals in endodontically treated and retreated maxillary molars. *J Endod* 2002; 28:477-9.
5. Cantatore G, Berutti E, Castellucci A. Missed anatomy: Frequency and clinical impact. *Endod Top* 2009; 15:3-31.
6. Pomeranz HH, Fishelberg G. The secondary mesiobuccal canal of maxillary molars. *J Am Dent Assoc* 1974; 88:119-24.
7. Gupta R, Adhikari HD. Efficacy of cone beam computed tomography in the detection of MB2 canals in the mesiobuccal roots of maxillary first molars: An *in vitro* study. *J Conserv Dent* 2017; 20:332-36.
8. Pecora JD, Woelfel JB, Sousa Neto MD, Issa IP. Morphologic study of the maxillary molars. Part II: internal anatomy. *Braz Dent J* 1992; 3: 53-7.
9. Cleghorn BM, Christie WH, Dong CC. Root and root canal morphology of the human permanent maxillary first molar: a literature review. *J Endod* 2006; 32: 813-21.
10. Silva EJ, Nejaime Y, Silva AI, Haiteir-Neto F, Zaia AA, Cohenca N. Evaluation of root canal configuration of maxillary molars in a Brazilian population using cone-beam computed tomographic imaging: an *in vivo* study. *J Endod.* 2014; 40(2):173-6.
11. Fogel HM, Peikoff MD, Christie WH. Canal configuration in the mesiobuccal root of the maxillary first molar: A clinical study. *J Endod.* 1994; 20:135-7.

12. Al Omer OE, Glennon J, Jennings M, Claffey NM. Root canal anatomy of maxillary first and second permanent molars. *Int Endod J.* 2000; 33:405–14.
13. Das S, Warhadpande MM, Redij SA, Jibhkate NG, Sabir H (2015) Frequency of second mesiobuccal canal in permanent maxillary first molars using the operating microscope and selective dentin removal: A clinical study. *Contemp Clin Dent* 6(1): 74-78.
14. Abduljabbar F, Mengari LF, Bahkali AM, Essa G, Farahat F, Abdelaal RM. Long Term Study of the Prevalence of Second Mesiobuccal canal in Maxillary First Molar of Saudi Population. *EC Dental Science* 2019; 18: 1014-1020.
15. Betancourt P, Navarro P, Fuentes R. CBCT technique for location of the MB2 canal of maxillary first molar. *Biomedical Research* 2017; 28(16)
16. Hasan M, Raza Khan F. Determination of frequency of the second mesiobuccal canal in the permanent maxillary first molar teeth with magnification loupes ($\times 3.5$) *Int J Biomed Sci.* 2014;10(3):201–207.
17. Hasan M, Raza Khan F. Determination of frequency of the second mesiobuccal canal in the permanent maxillary first molar teeth with magnification loupes ($\times 3.5$). *Int J Biomed Sci.* 2014 Sep;10(3):201-7. PMID: 25324702; PMCID: PMC4199472.
18. Buhrely LJ, Barrows MJ, BeGole EA, Wenckus CS. Effect of magnification on locating the MB2 canal in maxillary molars. *J. Endod.* 2002; 28:324–327.
19. Smadi L, Khraisat A. Detection of a second mesiobuccal canal in the mesiobuccal roots of maxillary first molar teeth. *Oral Surg. Oral Med. Oral Pathol. Oral Radiol. Endod.* 2007 Mar;103(3): e77–81.
20. Pomeranz HH, Fishelberg G. The second mesiobuccal canal of the maxillary molars. *J. Am. Dent. Assoc.* 1974; 88:119–124.
21. Green D. Double canals in single roots. *Oral Surg. Oral Med. Oral Pathol.* 1973; 35:689–696. [PubMed] [Google Scholar]
22. Seidberg BH, Altman M, Guttuso J, Suson M. Frequency of two mesiobuccal root canals in maxillary permanent first molars. *J. Am. Dent. Assoc.* 1973; 87:852–856.
23. Hameed, Muhammad Hasan, and Farhan Raza Khan. “Diagnosis of second mesiobuccal canal in maxillary first molars among patients visiting a tertiary care hospital.” *Int J Biomed Sci.* 11.2 (2015): 107.
24. Ahmed, Sageer, et al. “Canal Configuration In Mesiobuccal Root of Permanent Maxillary First Molar Teeth Among Bangladeshi Population-An In Vivo Study.” *Int J Med Sci* 7.12 (2020): 8-13.