

Chest Ultrasound- A New Way To Diagnose

SQRASHID

Abstract:

Chest ultrasound is a new modality and a new way of scanning and investigating the chest and lungs. It is getting popular both with the clinicians and the sonologists as it is cheap, easily available and portable and so can be taken to the patient's bedside in the Intensive Care Unit (ICU) or High Dependency Unit (HDU). Its need is increasing with the passage of time. It is more used nowadays with the prevalence of Dengue fever to detect pleural effusion and also the degree of pleural effusion. Its use also increased in the ICU and HDU during COVID pandemic to detect

pneumonia. Even for carrying out procedures like pleural fluid aspiration for diagnostic or therapeutic purpose its usage is increasing for accurate and quick access to the targeted area of fluid collection. It is also being used to exclude any collection at the site of aspiration so as to treat it before discharge of the patient.

Key Words: Chest ultrasound, lungs, pleural effusion, lung consolidation.

(J Bangladesh Coll Phys Surg 2024; 42: 189-193)

DOI: <https://doi.org/10.3329/jbcps.v42i2.72363>

Introduction:

Chest Ultrasound was introduced much later after ultrasound application on other sites like abdomen, breasts, small parts etc. The reason being lungs contain air and air or gas is the biggest enemy of ultrasound. As air reflects and disperses the ultrasound waves and therefore the waves cannot penetrate through it, making it impossible to see the organ of interest that we need to scan and see (Fig.1). For this reason, gas containing organs like gastrointestinal tract (GIT) and lungs cannot be visualized by ultrasound. To scan GIT it is filled with water after removing the air bubbles from the water and to scan lungs we take the help of artifacts. The word artifact means manmade. As these are machine generated images by ultrasound interaction with air in the lungs. These artifacts are appear on the monitor when ultrasound waves strike the air inside the lungs and are reflected and refracted. Therefore, the only pathology that can be easily, quickly and accurately detected and diagnosed by ultrasound here is pleural effusion. Which can be detected even when so small that it is just hairline thin. The reason being fluid is best imaged by ultrasound. It is also possible to comment on the density of the fluid whether it is thin or thick or if there is debris in the fluid or not.

Tools and Positioning of Patients

To scan the lungs lower frequency probes are used as we need depth and to scan the superficial parts, we use

Address of Correspondence: Dr. Sabrina Q. Rashid, Consultant Sonologist, Bangladesh Specialized Hospital.

21 Shyamoli, Mirpur Rd. Dhaka 1207, Mobile: 01715415257, E-mail: drsabrinaq@gmail.com

Received: 2 Sept. 2023

Accepted: 9 Sept. 2023

high frequency probes. This principle is followed in scanning all body organs or parts. Evaluation of more distal structures, as in the cases of pulmonary edema, pneumonia, or pleural effusion, require a lower frequency transducer, such as a 3.5 to 5.0 MHz phased array, or curvilinear transducer are optimal.¹

Evaluation of the thoracic wall and the pleura are usually done using the 9 to 12 MHz linear-array transducer, allowing detailed visualization of the more superficial nature of the anatomic structures.¹

Patients are usually placed in a supine or seated position, keeping in mind the physics of the medium which is being on evaluation. For example, pleural effusions will collect in a dependent manner, and a seated position, allowing gravity to cause effusions to collect at the inferior lung region, just above the diaphragm. The air in pneumothorax will rise to the apex of the area it is confined in. However, a lung consolidation such as pneumonia will be seen relatively independent of position.¹

Chest Ultrasound Scan Protocol

The probe is placed in the following locations for a systematic scan of the chest. The abbreviations as printed on the ultrasound pictures are given below:

RACW (Right anterior chest wall) -

Second or third intercostal space in the mammary line. For assessment of right lung.

RAAXL (Right anterior axillary line)-

Fifth intercostal space, at the level of nipple. For the assessment of Rt. lung.

RCosto (Right mid axillary line)-

Below the previous in fifth intercostal space. To detect pleural effusion in right side.

RPLAPS (Right posterior-lateral Alveolar and/or Pleural syndrome)-

Posterior most dependent part of lung. To detect consolidation and effusion.

Indications

Indications for thoracic ultrasound vary. In cases of trauma bedside thoracic ultrasound is useful for diagnosis of pneumothorax, hemothorax, rib fractures, pulmonary contusions, and chest wall hematomas, comprising of the extended form of the “focused assessment with sonography for trauma” (FAST) exam, known as EFAST (meaning Extended FAST). Non-traumatic uses for thoracic ultrasound include evaluation for pleural effusions (Fig.4 & 5), infectious causes such as pneumonia and empyema, pulmonary edema, chronic obstructive pulmonary disease (COPD), pulmonary embolism. Symptoms and clinical findings that can warrant ultrasonographic evaluation of patients include chest pain, dyspnea, fever, and hypoxia, just to name a few.^{2,3,4}

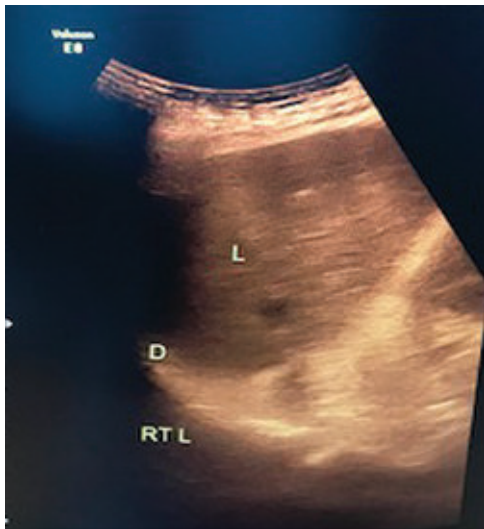

Figure 1: Normal right lung (RT L). Normal lung is not visualized by ultrasound as it contains air. Below it right hemi-diaphragm (D) and liver (L) are well visualized.

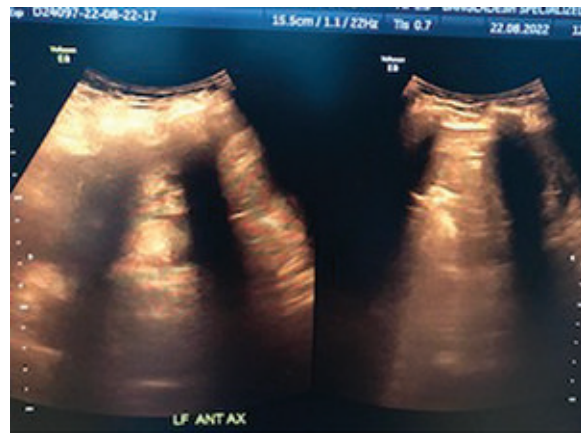


Figure 2: Left anterior axillary line. Normal A-line.

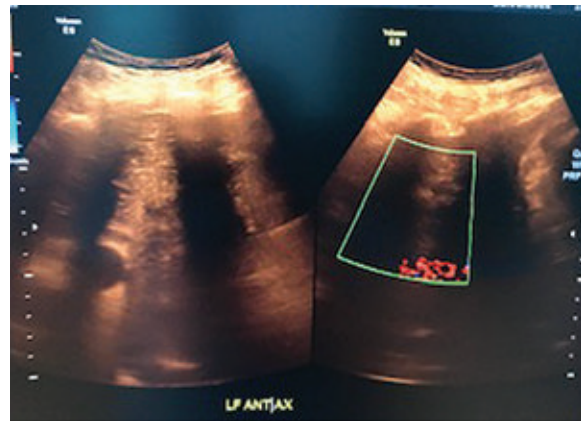


Figure 3: Thick fluid or Lung tissue? Vascularity in the later on Doppler application.

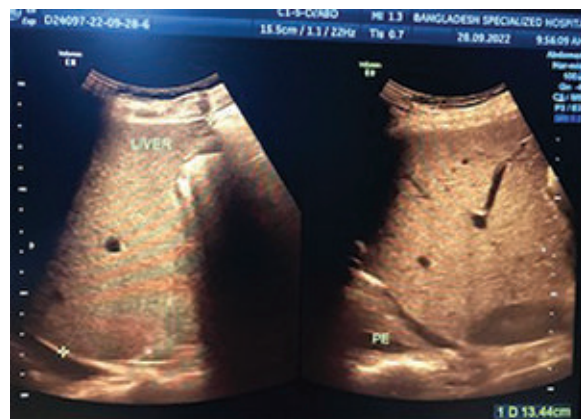


Figure 4: Small pleural effusion, right side.

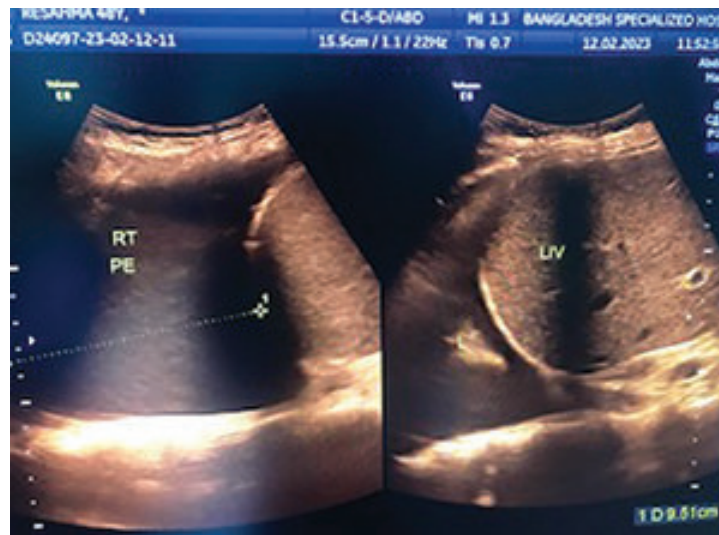

Figure 5: Large pleural effusion, right side (black or anechoic).

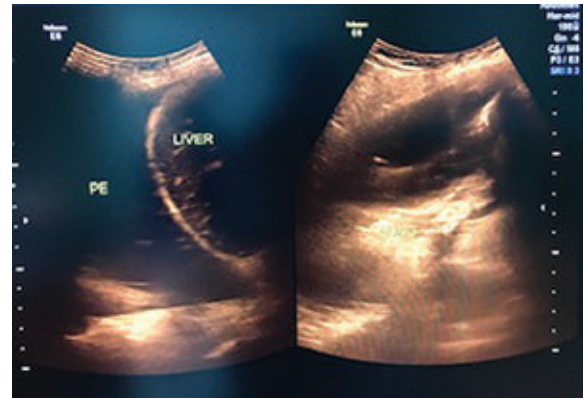
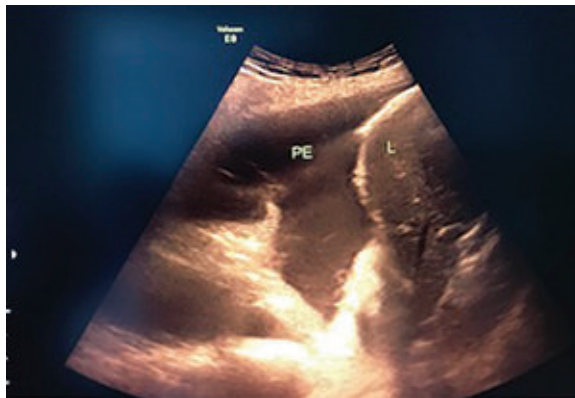

Figure 6a: Large Pleural effusion with atelectic right lower lung lobe (The echogenic solid in the effusion. Visible as it does not contain air anymore). **b:** Large Pleural effusion with atelectic right lower lung lobe.

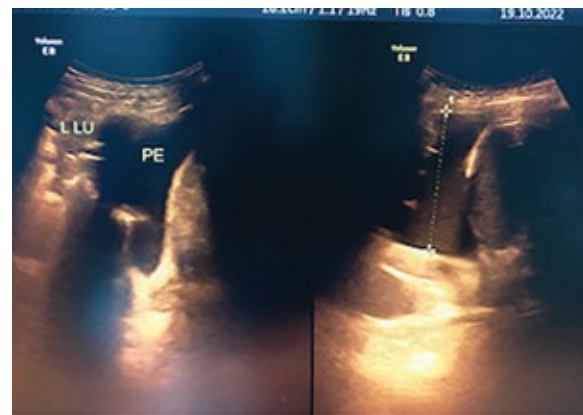
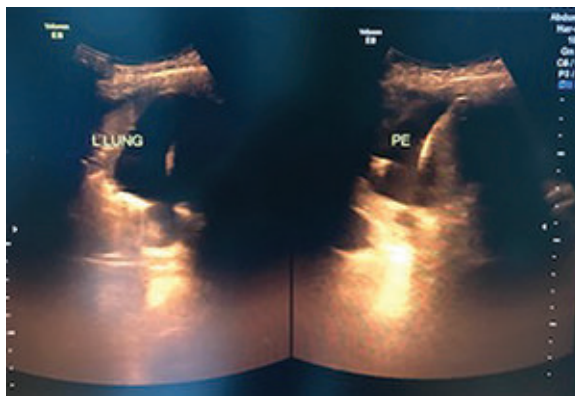


Figure 7a: Pleural effusion in Dengue fever. **b:** Pleural effusion in Dengue fever.

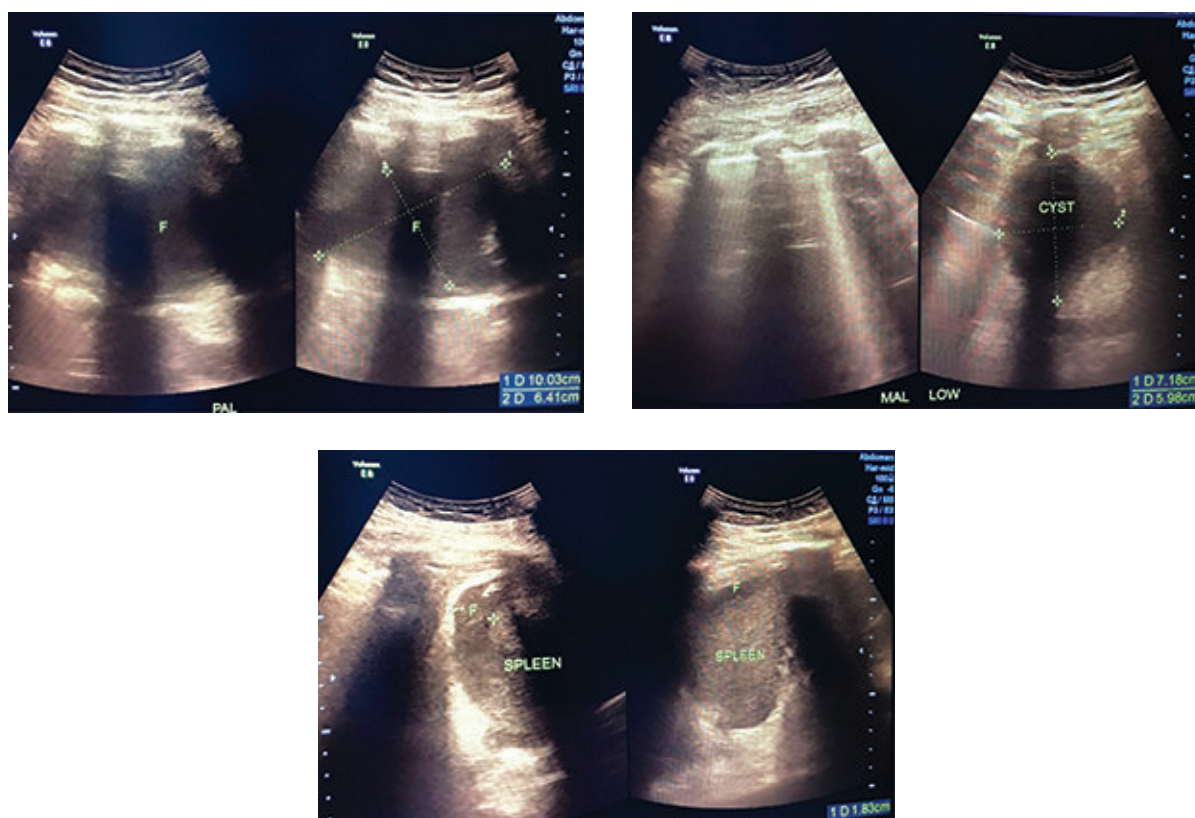


Figure 8a. Left Posterior axillary line with thick fluid collection after pleural effusion aspiration. **b:** Mid axillary line with normal lung tissue showing A-lines in upper part (Rt. Image) and thick fluid collection after aspiration in lower part at the site of aspiration (Lf. Image). **c:** After left posterior aspiration of pleural fluid. 18mm thick layer of subphrenic dense fluid collection too.

Discussion

Lung parenchyma is normally not visualized directly with ultrasonographic evaluation. However, artifacts produced by the ultrasound waves when striking air in the lung may be noted in some pathologies giving pathognomonic clues to them.

Disruptions in the normal visceral-parietal pleural interface via the introduction of air or fluid, are also key uses for thoracic ultrasonography. Under normal conditions, the parietal and visceral pleura are visualized as a single hyperechoic line known as the “pleural line.” It is approximately 1 cm distal to the ribs (Fig.2).

Acoustic impedance due to the underlying lung produces an echo artifact known as A lines, which are characteristically hyperechoic, regularly spaced horizontal lines below the pleural line. There are also Z lines which are short, broad, ill-defined vertical comet tail artifacts arising from the pleural line but do not extend to the edge of the screen.

Lung sliding may also be noted as the parietal and visceral pleura slide over each other and are visualized via ultrasound as a “shimmering” back and forth movement appearance of the pleural line and associated artifacts. Introduction of free air into the intrapleural space, as in the case of pneumothorax, disrupts the visualization of the lung sliding, and the pleural line appears static rather than dynamic. The loss of lung sliding is sensitive, but not specific for pneumothorax, as pleural adhesions, history of pleurodesis, atelectasis, mainstem intubation, apnea, and COPD can all give similar appearances. However, the “lung point” sign has been shown to be the most specific for pneumothorax. Lung point can be observed when the transducer is over the boundary between the aerated lung and the initiation of the pneumothorax, in which lung sliding will move in and out of view with the normal respiratory cycle. This may not be seen in the complete collapse of the lung parenchyma, and false positive lung points may be observed over pleural borders at the heart and diaphragm.

Also of note, “lung pulse” is the term associated with lung sliding seen in apneic patients resulting from slight movements along a normal pleural line due to the pulsations transmitted from the cardiac motions. Some evaluators may choose to use M mode in their evaluation, showing dynamic changes in the chest wall and underlying parenchyma, giving a “sandy beach” or “seashore” sign appearance. In this view, a normal lung will show a more superficial, linear appearance (small waves in water) of the stationary chest wall. The underlying, mobile, lung parenchyma appears more granular, like the sand on a beach. Disruption of the normal anatomy with a pneumothorax will cause loss of the more distal granule appearance and be replaced with continuing horizontal lines, often named the “barcode” or “stratosphere” sign. Presence of B lines rules out pneumothorax.

Due to a pathologic fluid within the pulmonary interstitial and alveolar space, a vertical, hyperechoic, ring down artifact will be noted. It extends to the bottom of the screen, and moves with respiratory effort, appearing as if a flashlight or multiple flashlights were being swung back and forth. These artifacts, known as B lines or “lung rockets” are secondary to the reverberation of ultrasonographic waves due to the fluid within the interlobular septae. B lines are diagnostic of pulmonary edema, such as occur in congestive heart failure and will be noted before fluid accumulation in the alveolar spaces. Evaluation for B lines is performed using curvilinear probes, evaluating multiple regions of bilateral lung fields, with at least 3 or more B lines noted in an ultrasound scan in at least two fields.

Thoracic ultrasound diagnosis of pulmonary edema has been shown to precede chest radiographic abnormalities and has a sensitivity and specificity of 97% and 95% respectively. The number of B lines present corresponds to the severity of the pulmonary edema present and correlates with the degree of improvement after treatment.

Focal and localized B lines may also be noted in traumatic pulmonary contusion and may be utilized for early detection in trauma evaluations.

In the case of consolidated pneumonia, heterogeneous, hyperechoic foci with irregular borders in the subpleural parenchyma may be noted having the appearance similar to the liver and coined “hepatization” of the lung. “Spine sign” is found in translobar consolidation. Indicating that one can see by ultrasound deeper tissues behind lungs, like spine, due to consolidation of lung. “Shred sign” is seen in non-translobar consolidation.

In addition, static or dynamic air bronchograms, seen as hyperechoic foci that may move with respirations within the lung parenchyma, representing air movement within the diseased lung, may be noted, as well as, associated effusions. Static when there is no air flow and Dynamic indicating air flow in infections like pneumonia. Stomach air mimics air bronchograms seen within lung parenchyma, so always look for diaphragm. As stomach air is below diaphragm in left side. Consolidated lung may be confused with thick pleural effusion. If Doppler is put on, there will be color flow in the former (Fig. 3).

Of note, atelectasis may appear similar to pneumonia with lung consolidation on both chest x-ray and thoracic ultrasound. Presence of static or dynamic bronchograms may allow differentiation between the two conditions, as dynamic air bronchograms, in which the hyperechoic artifacts are mobile, moving greater than 1 mm with respiratory efforts, are more likely in pneumonia than in atelectasis (Fig. 6a & 6b).

Additional history and findings such as fever and leukocytosis may strengthen the suspicion of pneumonia, as well.

Empyema may also be seen with bedside ultrasound, appearing as a hyperechoic fluid collection, often septated or loculated appearance. Early findings may appear hypoechoic without septa (Fig. 8a,b,c).^{5,6,7,8}

References:

1. Taylor A, Anjum F, O'Rourke MC. Thoracic and Lung Ultrasound (book). Last Update: September 26, 2022.
2. Schellenberg M, Inaba K. Critical Decisions in the Management of Thoracic Trauma. *Emerg Med Clin North Am.* 2018 Feb; 36(1):135-47.
3. Koh DM, Burke S, Davies N, Padley SP. Transthoracic US of the chest: clinical uses and applications. *Radiographics.* 2002 Jan-Feb; 22(1): e1.
4. Hew M, Tay TR. The efficacy of bedside chest ultrasound: from accuracy to outcomes. *Eur Respir Rev.* 2016 Sep; 25(141): 230-46.
5. Lichtenstein D. Novel approaches to ultrasonography of the lung and pleural space: where are we now? *Breathe (Sheff).* 2017 Jun;13(2):100-11.
6. Francisco MJ, Rahal A, Vieira FA, Silva PS, Funari MB. Advances in lung ultrasound. *Einstein (Sao Paulo).* 2016 Jul-Sep; 14(3): 443-48.
7. Lichtenstein DA. BLUE-protocol and FALLS-protocol: two applications of lung ultrasound in the critically ill. *Chest.* 2015 Jun; 147(6): 1659-70.
8. Lichtenstein D, Mezière G, Seitz J. The dynamic air bronchogram. A lung ultrasound sign of alveolar consolidation ruling out atelectasis. *Chest.* 2009 Jun; 135(6): 1421-25.