

# Pantothenate kinase-associated neurodegeneration (PKAN) a rare neurodegenerative disease-Two case reports

GK KUNDU<sup>a</sup>, K DAS<sup>b</sup>, NE SABAH<sup>c</sup>, MN NISHI<sup>d</sup>, MA SARKER<sup>e</sup>, S AHMED<sup>f</sup>

## Abstract:

*Neurodegeneration with brain iron accumulation (NBIA) is a subtype of inherited metabolic disorders. It includes pantothenate kinase-associated neurodegeneration (PKAN), which is a rare autosomal recessive disorder caused by the mutation of pantothenate kinase 2-gene (PANK2). It affects the deep grey matter nuclei causing progressive extra pyramidal motor impairment. We present two cases who are*

*presented in our department with walking difficulty, dystonia and dysarthria. MRI of brain (T2) showed- hyper intensity of the basal ganglia with the classic eye-of-the-tiger sign and one child's genetic study revealed mutation in PANK2 gene. We managed them with anti dystonic drugs along with iron chelating agent.*

*(J Bangladesh Coll Phys Surg 2024; 42: 209-213)*

*DOI: <https://doi.org/10.3329/jbcps.v42i2.72390>*

## Introduction:

Pantothenate kinase-associated neurodegeneration (PKAN) is the most common NBIA and has an estimated prevalence with one to two per million persons worldwide. It is a member of the Neurodegeneration with Brain Iron Accumulation (NBIA) family, heterogeneous group of disorder characterized by common features such as extra pyramidal movements, brain iron accumulation and eye involvement.<sup>1</sup> Usually, PKAN manifests in early childhood with gait disturbances and quickly progresses to a severe movement deficit like dystonia, dysphagia, and dysarthria. The hallmark of this disease is the “eye-of-the-tiger” sign on T2-weighted magnetic resonance imaging, which reflects the focal accumulation of iron in globus pallidus.<sup>2</sup> The disease manifests almost exclusively in the central

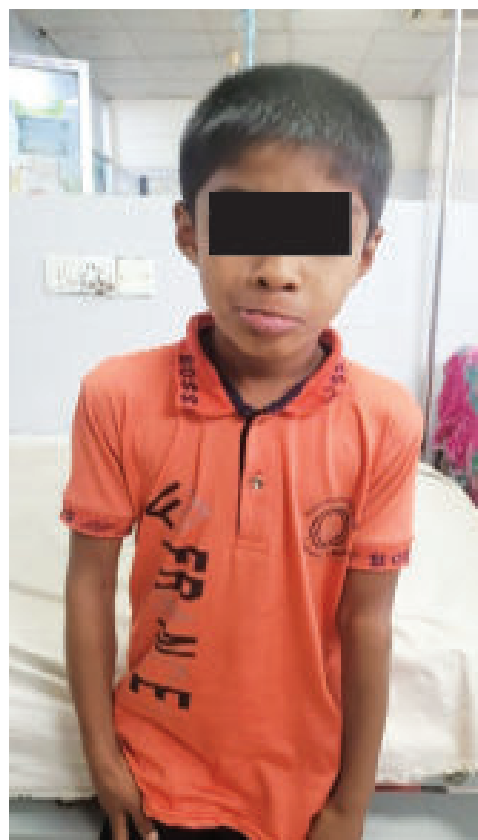nervous system (CNS), where a strong reduction in neurons and synapses is evident. Because of its rarity, current knowledge about PKAN is based on case reports, case series and personal observations presented by clinicians from different medical centers.<sup>3</sup> To the best of our knowledge, till now no childhood PKAN case has been reported from Bangladesh.

- Professor Gopen Kumar Kundu, Chairman, Department of Pediatric Neurology, Bangabandhu Sheikh Mujib Medical University.
- Dr. Konica Das, Department of Pediatric Neurology, Bangabandhu Sheikh Mujib Medical University.
- Dr. Noor-A-Sabah, Department of Pediatric Neurology, Bangabandhu Sheikh Mujib Medical University.
- Dr. Meher Nigar Nishi, Department of Pediatric Neurology, Bangabandhu Sheikh Mujib Medical University.
- Dr. Mohammad Arbab Sarker, Department of Pediatric Neurology, Bangabandhu Sheikh Mujib Medical University.
- Dr. Sanjida Ahmed, Consultant, Department of Pediatric Neurology, Bangabandhu Sheikh Mujib Medical University.

**Address of Correspondence:** Professor Dr. Gopen Kumar Kundu, Chairman, Department of Pediatric Neurology, Bangabandhu Sheikh Mujib Medical University, Shahbagh, Dhaka. Mobile no-01718590768, E-mail: [gopen.kundu@gmail.com](mailto:gopen.kundu@gmail.com)

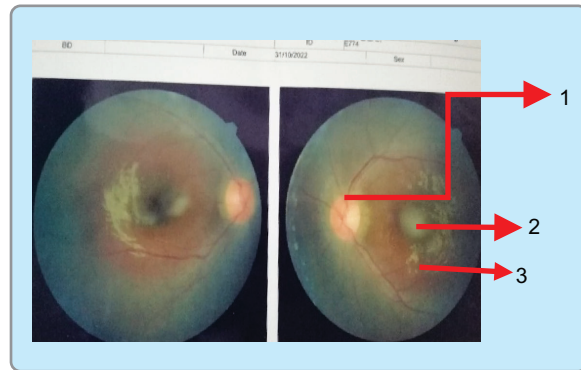
**Received:** 03 April, 2023

**Accepted:** 22 November, 2023



**Case (1):**

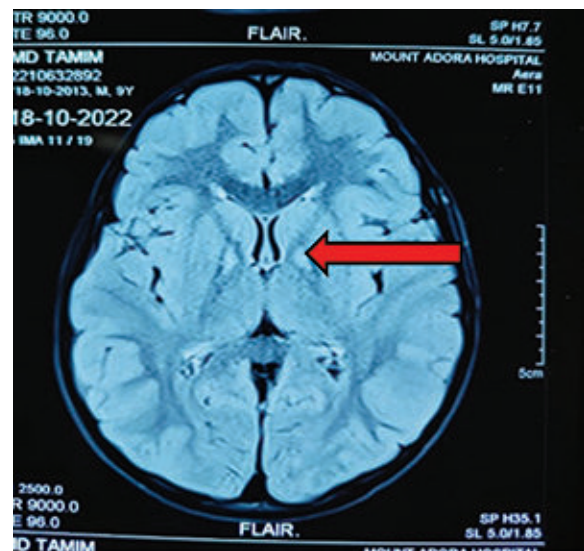
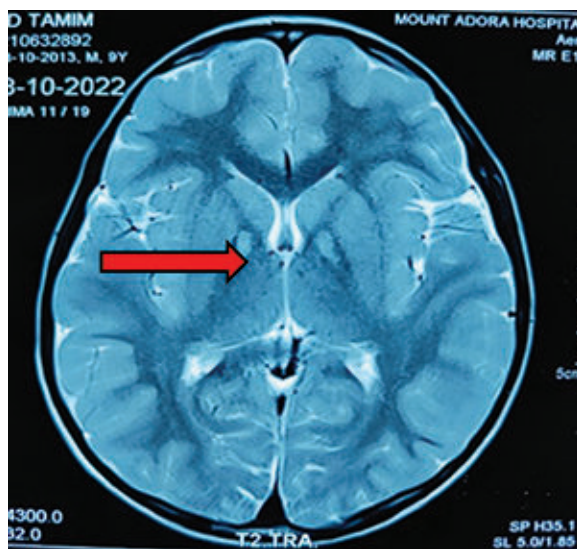
A 9 years old boy, 2<sup>nd</sup> issue of his consanguineous parents, hailing from rural area of Bangladesh, got admitted in BSMMU with the complaints of progressive walking difficulty, abnormal movement of all four limbs & dysarthria since six years of age along with difficulty in night vision & deterioration of hand writing. He has no h/o seizure, unconsciousness, jaundice, skin pigmentation, hearing impairment, taking any offending drug and no family history of such type of illness. This child was delivered by normal vaginal delivery and cried immediately after birth. He was developmentally age appropriate upto 6 years of age. He was immunized as per EPI schedule. Other family members were healthy. O/E: patient was conscious, vitally stable, mildly pale, anthropometrically severely underweight & stunted. Nervous system examination reveals, patient was conscious, dysarthria present, cranial nerves were intact except color vision, in both limbs spasticity and rigidity present, power 4/5, all jerks were exaggerated, plantar bilaterally extensor, dystonia & abnormal dystonic gait present. Sensory & cerebellar function was intact. Other systemic examination revealed no abnormalities. Investigation report shows - Complete blood count and peripheral blood film were normal. Fundoscopic examination findings - Disc pallor in both eye. Bull's eye maculopathy and Retinitis pigmentosa was present bilaterally.



**Figure 1:** Color Fundoscopy showed disc pallor (arrow -1), Bull's eye maculopathy (arrow-2) and Retinitis pigmentosa (arrow-3)

Radiological features of PKAN on brain MRI. Axial T2 (A) and axial FLAIR (B) images showed “eye-of-the-tiger” sign with bilaterally symmetrical medial globus pallidus hyper intensity surrounded by a region of hypo intensity .

After confirmation of diagnosis, we started treatment with oral Trihexyphenidyl, Co enzyme, Levocarnitine, Riboflavin, Deferiprone, and supportive therapy: physiotherapy, speech & language therapy. Patient was clinically gradually improved. Now he is on regular follow up.

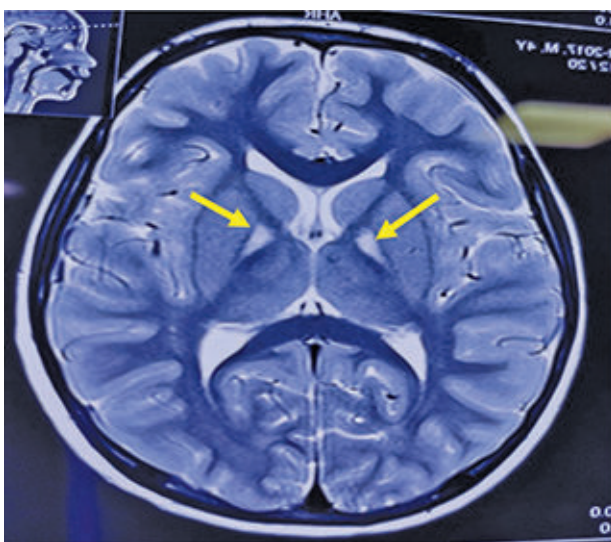


**Figure:** MRI of brain axial T2 (A) and axial FLAIR (B) images showed the “eye-of-the-tiger” sign with bilaterally symmetrical medial globus pallidus hyper intensity surrounded by a region of hypo intensity.

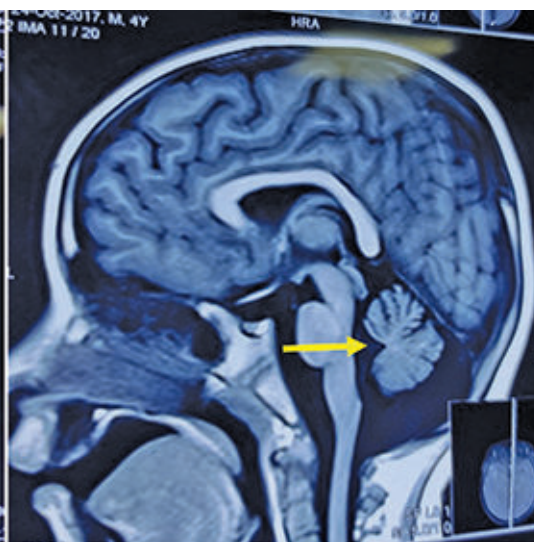
**Case 2:**

A 4 years old male child 2<sup>nd</sup> issue of non-consanguineous parents, got admitted on 12th may,2021 with the complaints of difficulty in walking with frequent fall and poor balance since one and half year of age. Initially it was infrequent then gradually deteriorating over time. Mother also noticed he developed dystonia in both upper and lower limbs which exacerbated while attempting to hold any object. He also had slurred speech. His birth history was uneventful and developmentally he was age appropriate prior to this

illness. There was no family history of such type of illness. He had no h/o seizure, unconsciousness, abnormal behavior, or any visual and hearing impairment. On examination child was conscious, alert, vitally stable, well thriving. Nervous system examination revealed dysarthria, dystonia and rigidity. Cranial nerve examination was normal. All jerks were normal and plantar response was bilaterally flexor. Gait was ataxic. Sensory function was intact. Cerebellar function was normal except truncal ataxia. Slit lamp examination of both eyes and fundoscopic examination revealed normal findings, no K-F ring or retinitis pigmentosa was present. Other systemic examination revealed normal findings. Investigations showed Complete blood count with PBF was within normal limit. MRI of brain (T2 and FLAIR) revealed hyperintensity of bilateral globus pallidus surrounded by hypo intensity, which is known as eye-of-tiger sign (Figure 2) and also he had cerebellar atrophy (Figure 3). Genetic study revealed mutation in PANK2 gene. This Patient was treated with multiple anti dystonic drugs like- trihexyphenidyl and baclofen for dystonia and rigidity. Physiotherapy and speech therapy was also started. Metabolic cocktail therapy i.e tab levocarnitine, cap co-enzyme Q, Vitamin B complex was also given as supportive management. Iron chelating agent, deferiprone was started in 27mg/kg/day orally as specific therapy. His dystonia is gradually improving and now patient is on regular follow up 3 monthly clinically and radiologically.



**Figure 2:** MRI of brain showing hyperintensity of bilateral globus pallidus with surrounding hypo intensity (eye-of-tiger sign)(Arrow)



**Figure 3:** MRI of brain showing cerebellar atrophy (Arrow)



**Discussion:**

PKAN is a disorder which comes under an umbrella term called Neurodegeneration with Brain Iron Accumulation (NBIA). It is an autosomal recessive disorder caused by the absence or deficiency of PANK2 gene located in chromosome 20p13-p12.3, which is indirectly responsible for the generation of adenosine triphosphate (ATP) in the body by producing co-enzyme-A (CoA), helping in production of energy in the mitochondrial cells. The deficiency of PANK2 can lead to the accumulation of N-pantothenoyl-cysteine and pantotheine, which may lead to cell toxicity or may cause cell damage.(4) Brain iron levels are age-dependent: At birth no iron is detectable in the brain, but iron then accumulates during development. In adulthood and old age, gradual increase of iron deposition is observed mostly in microglia and astrocytes, particularly prominent in the globus pallidus, red nucleus, substantia nigra (SN), dentate nucleus, and putamen but to a lesser extent also in the caudate, thalamus and frontal gray matter as documented by histochemistry and magnetic resonance imaging (MRI) studies. Why iron selectively accumulates with increasing age remains ill understood. One hypothesis is that dysfunction in blood brain barrier may allow iron to enter uncontrolled to predisposed areas.(5)

The classic PKAN is characterized by early onset usually by 6 years of age while atypical PKAN occurs usually at the age of 13–14 years. In last 3 years we diagnosed only this 2 cases of PKAN in our department. PKAN is an extra pyramidal type of motor disorder with dystonia, rigidity and other involuntary movements (choreoathetosis or tremor) and also with pyramidal signs. Gregory and Hayflick reported other features such as dysarthria, dysphagia, optic atrophy which can eventually cause significant loss of vision, retinitis pigmentosa, parkinsonism, poor balance, seizures, progressive intellectual impairment, blepharospasm and torticollis.(4) In our two cases spasticity, rigidity, dysarthria, dystonia were present.

Pigmentary retinal degeneration occurs in two thirds of affected individuals with classic PKAN. Retinopathy occurs early in the disease, although it is not often recognized until a full diagnostic evaluation including electroretinogram (ERG) and visual field testing is performed. The retinal degeneration follows a typical clinical course, with nyctalopia (night blindness)

followed by progressive loss of peripheral visual fields and sometimes eventual blindness. Funduscopic changes initially include a flecked retina and later progress to bone spicule formation, conspicuous choroidal vasculature, and “bull’s-eye” annular maculopathy. Individuals with a normal ophthalmologic examination at the time of diagnosis generally do not develop retinopathy later.(4) In our 1<sup>st</sup> case history of loss of vision was present. On fundoscopic examination disc pallor, Bull’s eye maculopathy, Retinitis pigmentosa was present bilaterally. But in 2<sup>nd</sup> case eye evaluation revealed normal. In peripheral blood film acanthocytes is found in 8% of patients with classic PKAN.(6)

The pathognomonic sign in PKAN is hyperintensity of bilateral globus pallidus with surrounding hypointensity (eye of tiger sign) on MRI of brain.(7) In our cases MRI of brain showed eye-of-tiger sign. The peripheral hypointense signals on T2 weighted image is due to iron deposition and the central hyperintensity is due to the gliosis and apoptosis due to cell death. In PKAN, iron-containing pigment accumulates in globus pallidus and the pars reticulata of the substantia nigra.(2) Genetic study of our 2<sup>nd</sup> case revealed mutation in PANK2 gene which confirmed our diagnosis.

Management of PKAN consists of mainly supportive and symptomatic. Dystonia is the most common symptom. Dystonia and spasticity can be managed with trihexyphenidyl, baclofen, injectable botulinum toxin. Surgical treatment including deep brain stimulation, stereotactic pallidotomy, and bilateral thalamotomy may be effective in PKAN. Oral iron chelating agent deferiprone is found effective in few studies.(8) (9) Our patient was also treated with iron chelator deferiprone at doses between 25-30 mg/kg per day. Other supportive treatments were given for dystonia were oral trihexyphenidyl, physiotherapy, occupational therapy and speech therapy. Baclofen and trihexyphenidyl have been reported as most effective medications for restricting dystonia and spasticity.(4)

**Conclusion:**

It can be concluded that childhood dystonia and eye-of-tiger sign on neuroimaging are the diagnostic feature of pantothenate kinase associated neurodegeneration (PKAN), that can be treated with iron chelating agent deferiprone along with other supportive managements.

**References:**

1. Kurian MA, McNeill A, Lin JP, Maher ER. Childhood disorders of neurodegeneration with brain iron accumulation (NBIA). *Dev Med Child Neurol.* 2011;53(5):394–404.
2. Sethi KD, Adams RJ, Loring DW, El Gammal T. Hallervorden spatzi syndrome: Clinical and magnetic resonance imaging correlations. *Ann Neurol.* 1988;24(5):692–4.
3. Marshall RD, Collins A, Escolar ML, Jinnah HA, Klopstock T, Kruer MC, et al. Diagnostic and clinical experience of patients with pantothenate kinase-associated neurodegeneration. *Orphanet J Rare Dis.* 2019;14(1):1–12.
4. Saha A, Shabnam S, N S. Pantothenate kinase-associated neurodegeneration (PKAN) – a rare clinical entity. *Acta Oto-Laryngologica Case Reports.* 2016;1(1):90–7.
5. Schneider SA, Zorzi G, Nardocci N. Pathophysiology and Treatment of Neurodegeneration with Brain Iron Accumulation in the Pediatric Population. *Curr Treat Options Neurol.* 2013;15(5):652–67.
6. Hayflick SJ, Westaway SK, Levinson B, Zhou B, Johnson MA, Ching KHL, et al. Genetic, Clinical, and Radiographic Delineation of Hallervorden–Spatzi Syndrome. *N Engl J Med.* 2003;348(1):33–40.
7. Schaffert DA, Johnsen SD, Johnson PC, Drayer BP. Magnetic resonance imaging in pathologically proven hallervorden-spatzi disease. *Neurology.* 1989;39(3):440–2.
8. Klopstock T, Tricta F, Neumayr L, Karin I, Zorzi G, Fradette C, et al. Safety and efficacy of deferiprone for pantothenate kinase-associated neurodegeneration: a randomised, double-blind, controlled trial and an open-label extension study. *Lancet Neurol.* 2019;18(7):631–42.
9. Hogarth P, Kurian MA, Gregory A, Csányi B, Zagustin T, Kmiec T, et al. Consensus clinical management guideline for pantothenate kinase-associated neurodegeneration (PKAN). *Mol Genet Metab.* 2017;120(3):278–87.