

# Feasibility and Effectivity of Video-assisted Thoracoscopic Surgery in the Management of Acute Empyema Thoracis – A Prospective Study

MA HOQUE<sup>a</sup>, MMR MIA<sup>b</sup>, NK SARKAR<sup>c</sup>, SMZ RASHA<sup>d</sup>

## Abstract:

**Introduction:** Empyema thoracis is a condition in which pus and fluid from infected tissue collects in the pleural cavity. The optimal treatment of empyema thoracis, especially in the acute condition remains controversial, whether to go for a non-operative approach (antibiotics and chest tube drainage) or an early operative regimen, VATS (Video-assisted thoracoscopic surgery). The study is conducted to determine the effectiveness of VATS in the treatment of acute empyema thoracis.

**Methods:** We conducted a prospective comparative study between two methods of treatment i.e., chest tube insertion and VATS as primary intervention in the acute empyema thoracis. Each group consisted of 40 patients who were diagnosed as acute empyema thoracis during the period of January 2021 and June 2022. The duration of chest tube in-situ, hospital stay, cost, complications, success and outcomes were compared between the two groups.

## Introduction:

Empyema thoracis is the localized or free collection of purulent material in the pleural space as a result of combination of pleural dead space, culture medium of pleural fluid and inoculation of bacteria.<sup>1</sup> This is a serious complication of infection adjacent to or within the chest that rarely resolves without appropriate medical therapy

**Results:** It was found that VATS was better than the conventional chest tube insertion in terms of the mean duration of hospital stay ( $16.05 \pm 3.58$  vs  $25.78 \pm 4.04$  days), mean duration of the chest tube in-situ ( $8.23 \pm 2.09$  vs  $17.18 \pm 3.30$  days), mean cost of the treatment (Taka  $12962.50 \pm 1469.29$  vs  $19175.00 \pm 1443.60$ ), complications ( $42.5\%$  vs  $77.5\%$ ) and success rate ( $80\%$  vs  $45\%$ ). There was no death in any group.

**Conclusion:** Video-assisted thoracoscopic surgery (VATS) is feasible and effective in the management of acute empyema thoracis.

**Key words:** Acute empyema thoracis, Intercostal drainage (ICD), Video-assisted thoracoscopic surgery (VATS)

(J Bangladesh Coll Phys Surg 2024; 42: 223-229)  
DOI: <https://doi.org/10.3329/jbeps.v42i3.74065>

a Mohammad Anamul Hoque, Registrar, Dept. of Thoracic Surgery, NIDCH, Mohakhali, Dhaka.

b Md. Mofizur Rahman Mia, Associate Professor, Dept. of Thoracic surgery, NIDCH, Mohakhali, Dhaka.

c Nirmal Kanti Sarkar, Assistant Professor, Dept. of Respiratory Medicine NIDCH, Mohakhali, Dhaka.

d Sheikh Md. Zakirullah Rasha, Jr. Consultant, Dept. of Thoracic Surgery, NIDCH, Mohakhali, Dhaka.

**Address of Correspondence:** Dr. Mohammad Anamul Hoque, Registrar, Department of Thoracic Surgery, National Institute of Diseases of the Chest & Hospital, Mohakhali, Dhaka. Mobile no: 01712636142. Email: dr.anamul27@gmail.com.

**Received:** 05 May 2024

**Accepted:** 26 May 2024

and drainage procedure. Empyema is usually a complication of para pneumonic effusion, also traumatic and post operative to be an important cause.<sup>2</sup> Empyema thoracis has been recognized as a serious problem associated with considerable morbidity and mortality, whether treated or untreated.<sup>3</sup> Based on the pathophysiology of the disease process it has three stages: stage I - exudative phase, stage II – fibrinopurulent phase and stage III – chronic or organizing phase.<sup>4</sup> For management purpose, empyema thoracis is divided into acute and chronic. The acute empyema may be as short as upto 3 weeks including exudative and fibrinopurulent phase treated by antibiotics, thoracic drainage, fibrinolysis or debridement under VATS.<sup>5</sup> Planning of therapeutic interventions for acute empyema based on duration of symptoms remains clinically challenging. This would suggest that if therapeutic goal is to be achieved, then intervention by mean of minimally invasive fashion, as initial treatment should be instituted early and with high expectations of

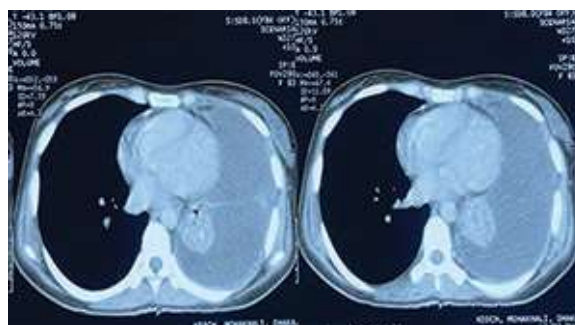
success in the majority of cases, regardless of stage.<sup>5</sup> The optimal treatment of empyema thoracis, especially in the acute phase remains controversial, so as whether to go for a non-operative option (antibiotics and chest tube drainage) or an early operative, video-assisted thoracoscopic surgery. While the former mode is less invasive and cheap, it is not clearly proven that it is better than the more invasive later mode of treatment in terms of conversion into thoracotomy, morbidity and duration of hospital stay.<sup>6</sup>

VATS is an overall safe procedure with a very low complication and mortality rate when performed by a trained thoracic surgeon in conscious sedated patients under local anesthesia or under general anesthesia.<sup>7,8</sup> It was found as a superior primary treatment in few studies but not usually routinely practiced in many hospitals yet.<sup>9</sup> A good prospective study is necessary to prove this concept of VATS in the management of acute empyema thoracis especially in our setting. The advantages of minimally access VATS needs to be applied and proved beyond doubts as whether it is better than the treatment with chest tube drainage alone in the acute empyema thoracis.<sup>10</sup> This study will take up to compare the efficacy of both treatment modalities in terms of morbidity, cost effectiveness, need for further intervention and to identify the optimal way of managing the condition.

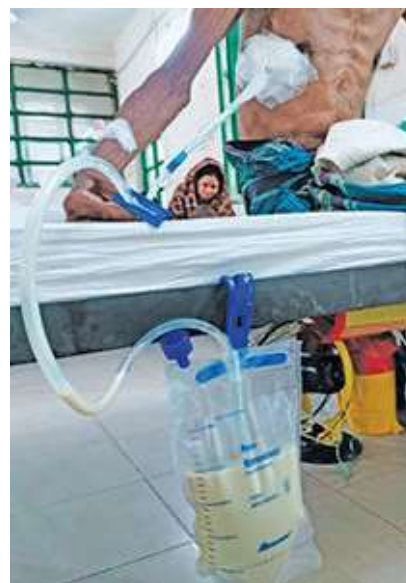#### Method:

This is a prospective comparative study of two treatment modalities i.e., chest tube insertion (ICD) and VATS as primary intervention in the acute empyema thoracis. The study was conducted in the department of Thoracic Surgery, National Institute of Diseases of the Chest and Hospital, Dhaka, between the period of January 2021 and June 2022. Total 80 patients with acute empyema thoracic were enrolled according to inclusion and exclusion criteria and were divided into two equal treatment groups by convenient sampling method. 'Group A' or ICD group and 'Group B' or VATS group consisted of 40 patients each. The inclusion criteria were - patients diagnosed as an acute empyema thoracis. The following patients were excluded from the study - empyema associated with carcinoma, terminally ill patients, child below 14 years and patients not fit for surgery, associate co-morbidities (heart failure, myocardial infarction within 6 months, chronic renal failure, uncontrolled DM, and immunosuppression). Patients who needed thoracotomy during VATS were also excluded.

The data was collected in a semi-structured questionnaire comprising of history, clinical examination, investigations including imaging modalities and pleural fluid analysis and post-operative follow up of the patients. All patients irrespective of the group to which they belong were evaluated by a pre-operative routine work-up. All patients were started on antibiotics according to the culture and sensitivity reports of the pleural fluid analysis. Other supports such as supplemental O<sub>2</sub>, antipyretics, analgesics, etc. were given preoperatively according to need. Then they were subjected to either mode of treatment & divided into two groups. Counseling was done and consent for the intervention was taken. Group A (ICD): 40 patients were subjected to chest tube insertion under local anesthesia (LA) following all the necessary precautions and standard protocols.



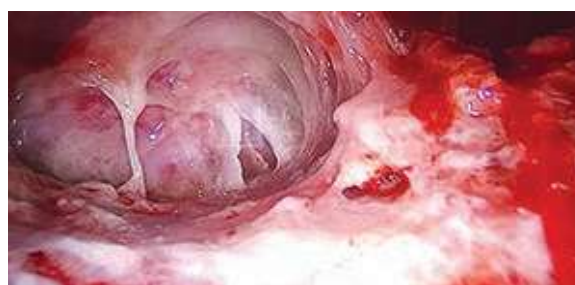**Figure 1:** CT scan of the chest



**Figure 2:** ICD for empyema thoracis.

The position of the patient was supine or semi-recumbent. Then skin preparation and draping (usually 5th intercostal space at anterior axillary line was selected) and local anesthetics infiltration done. A 1.5 to 2 cm skin incision was made in the direction of rib and bluntly dissected intercostal soft tissue down to the pleura and parietal pleura then entered with a Kelly's forceps. The track was checked with finger and ICD tube then inserted with Kelly's forceps and connected to an underwater seal drainage system. The column movement with respiration was checked and ICD tube secured and adhesive dressing given. The chest drain tube was removed if the patient was symptom free, clinically & radiological full expansion of lung, minimal or absence of drainage and no evidence of air leak. The end point of the study was clinical outcomes (discharge without complications or death). The treatment was considered failure if the patient did not improve clinically as well as radiologically and if he/she needed VATS/thoracotomy for further management. Other data of Group A patients were collected & analyzed. Group B (VATS): 40 patients were subjected to VATS under local anesthesia with conscious sedation or under general anesthesia. Patients were kept nil by mouth for 6 hours prior to the procedure. Intravenous access was achieved in the upper limb same to the side of VATS. Regional anesthesia by means of intercostal nerve block and subcutaneous infiltration of 10 ml solution of 2% lignocaine & bupivacaine at the desired incision site with intravenous propofol and pethidine were administered by anesthesiologist to increase patient's comfort without compromising respiration. And for general anesthesia, patients were intubated by a suitable double lumen endotracheal tube. Patients were then made to lie in lateral decubitus position with affected side facing upward. This was uni-portal VATS where incision site was usually 4th or 5th intercostal space in between anterior & mid axillary line. A 3–5 cm size incision was made and the subcutaneous tissue and muscles were bluntly dissected to reach the pleura. Then a wound protector was used and systemic exploration of the pleural cavity was done by a rigid thoracoscope (Karl Storz, Germany and Hopkin's 30° telescope) 5 mm or 10 mm diameter. Pus was drained under direct vision, breakdown of locules done, pleural plaques removed and irrigation given. Chest tube size 28 fr to 32 fr was introduced through corner of the incision site and

connected with water seal drainage bag followed by proper suturing of the wound. Watchful observation was done to detect any complications and all procedure related data were recorded. The criteria for success were similar to that of group A and the treatment was considered failure if the patient needed a thoracotomy later. The endpoint was the same. Chi square test was done for the calculation of continuous and categorical variables. Outcome variables in between groups were measured by Fisher's exact test. Statistical package for the social science (SPSS) version 23.0 was used for statistical analysis of data. A  $p$  value  $<0.05$  was considered statistically significant.



**Figure 3:** View of pleura cavity during VATS.

#### **Result:**

The cohort included total 80 patients with acute empyema thoracis. Age range in total population was from 15 to 65 years and most of the patients (56.2%) belongs to 36–55 years age group. The mean age in group-A was  $41.65 \pm 11.54$  years ( $\pm$ SD) and in group-B was  $42.58 \pm 11.86$  years ( $\pm$ SD). Most of the patients had diabetes mellitus (DM), representing 37.5% of the population followed by chronic obstructive pulmonary diseases (COPD), hypertension (HTN), ischemic heart diseases (IHD) and they were compared between the groups. Demographic characteristics of the study population were shown in table I. Common presentation of the patients was fever (57.5%), breathlessness (48.7%), cough (42.5%) and chest pain (21.5%). Most of our patients had moderate dense opacity (55%) in CXR P/A view. Sixty patients were evaluated by CT scan of the chest and found empyema with free collection in 54.5% and multiple loculation in 45.4% cases. During VATS, pleuro-parenchymal adhesion was observed in 80%, multiple loculation in 67.5%, and thickened pleura in 17.5% cases. There was no parenchymal lesion.

We found that VATS was better than the conventional chest tube insertion in terms of mean duration of hospital stay ( $16.05 \pm 3.58$  vs  $25.78 \pm 4.04$  days,  $p < 0.001$ ), mean

duration of the chest tube in-situ ( $8.23 \pm 2.09$  vs  $17.18 \pm 3.30$  days,  $p < 0.001$ ), mean cost of the treatment (Taka  $12962.50 \pm 1469.29$  vs  $19175.00 \pm 1443.60$ ,  $p < 0.001$ ), complications (42.5% vs 77.5%) and success rate (80% vs 45%,  $p = 0.001$ ). There was no procedure related mortality in either group. Characteristics of main outcome variables with complications of the study population were shown in the table II.

**Table-I**

*Demographic characteristics in the two groups (n=80).*

Variables	Group		p value
	Group A	Group B	
Age (years):			
$\leq 25$	4 (10.0)	2 (5.0)	
26-35	7 (17.5)	11 (27.5)	
36-45	17 (42.5)	15 (37.5)	
46-55	7 (17.5)	6 (15.0)	
$> 55$	5 (12.5)	6 (15.0)	
Mean $\pm$ SD	$41.65 \pm 11.54$	$42.58 \pm 11.86$	0.725 <sup>a</sup>
Sex:			
Male	24 (60)	30 (75)	0.152 <sup>b</sup>
Female	16 (40)	10 (25)	
Residence:			
Rural	29 (72.5)	34 (85)	0.172 <sup>b</sup>
Urban	11 (27.5)	6 (15)	
Side:			
Right	23 (57.5)	24 (60)	0.820 <sup>b</sup>
Left	17 (42.5)	16 (40)	
Total	40 (100)	40 (100)	

<sup>a</sup>Unpaired t test was done to measure the level of significance. <sup>b</sup>Chi-square test was done to measure the level of significance. Figure within parenthesis indicates in percentage.

**Table-II**

*Outcome variables compared in between two groups (n=80).*

Variables	Groups		p value
	Group A	Group B	
Operative time (mins)	$28.13 \pm 4.59$	$73.38 \pm 7.17$	$< 0.001^*$
Duration of hospital stay (days)	$25.78 \pm 4.04$	$16.05 \pm 3.58$	$< 0.001^*$
Duration of tube in situ (days)	$17.18 \pm 3.30$	$8.23 \pm 2.09$	$< 0.001^*$
Cost of the treatment (Taka)	$19175.00 \pm 1443.60$	$12962.50 \pm 1469.29$	$< 0.001^*$
Complication Air leak	3 (7.5)	2 (5.0)	0.263 <sup>b</sup>
Bleeding	0 (0.0)	5 (12.5)	0.012 <sup>b</sup>
Surgical emphysema	3 (7.5)	1 (2.5)	0.432 <sup>b</sup>
Wound infection	3 (7.5)	1 (2.5)	0.108 <sup>b</sup>
Encysted collection	15 (37.5)	6 (15.0)	0.022 <sup>a</sup>
Collapse lung- partial	7 (17.5)	2 (5.0)	0.154 <sup>b</sup>
Mortality	0 (.0)	0 (.0)	-
Success	18 (45)	32 (80)	$-0.001^*$
Failure	22 (55)	08 (20)	

\*Unpaired t test was done to measure the level of significance. Data was expressed as Mean  $\pm$  SD

<sup>a</sup>Chi-square test was done to measure the level of significance.

<sup>b</sup>Fisher's exact test was done to measure the level of significance.

Figure within parenthesis indicates in percentage

**Discussion:**

Pleural space infection or empyema is a frequently encountered condition that is associated with significant morbidity and mortality. In acute empyema, drainage of infected material from the pleural space is a fundamental part of empyema treatment. Traditionally, tube thoracostomy has been performed with large-bore drain tube but no consensus exists regarding ideal drain size. The primary causes of drain failure are occlusion and dislodgement. Drain occlusion occurs more commonly with empyema than with uncomplicated pleural effusion or pneumothorax with reported blockage rates typically from 11% to 30%.<sup>11</sup> Since the improvement of laparoscopic techniques, thoracoscopic surgery has become more effective and is recommended for the treatment of many thoracic diseases, including empyema with satisfactory results. The choice of thoracoscopic approach must be made with two primary goals in mind: (1) complete evacuation of potentially infected fluid and/or material and (2) complete re-expansion of the lung.

In our study, total 80 patients with acute empyema thoracis were divided into two groups. Group-A consisted 40 patients underwent chest tube drainage and another 40 patients underwent VATS in group-B. Age range in total population was from 15 to 65 years and most of the patients (56.2%) belongs to 36- 55 years age group. There was no significant difference between the two groups regarding the age. In a retrospective study by Majeed FA and co-workers it was found that patient with overall age was  $44 \pm 16.37$  years.<sup>12,13</sup> Male female ratio in our study was 2.1 :1 without any significant difference between the two groups. Similar observation was made by Shahin Y et al in their study.<sup>14</sup> We found right-sided empyema in 47 (58.7%) and in left-sided in 33 (41.3%) patients. Nearly half (48.7%) of our patients had different co-morbidities. Diabetes was the most common (37.5%), followed by COPD (18.7%) and HTN (12.5%). Similar results were seen in a study done by Cargill TN et al.<sup>15</sup>

Evaluation of symptoms of our patients with empyema thoracis revealed that the most common symptom was fever (57.5%), followed by breathlessness (48.7%) and cough (42.5%). A retrospective cohort study in Thailand conducted by Tantraworasin A et al. showed breathlessness in 60.1%, fever in 49.9% and cough in 40.4% patients.<sup>16</sup> The duration of symptoms before diagnosis of our patients was mostly within 2 to 3 weeks

in 51.2% and then within 1 to 2 weeks in 30%. Similar observation was made by Pilav I and colleagues in their study.<sup>17</sup> Most of our patient found to have moderate dense opacity (55%) in chest x-ray followed by mild opacity (25%) and massive involvement (20%). Sixty patients were evaluated by CT scan of the chest and found empyema with free collection in 54.5% cases and multiple loculation in 45.4% cases which was statistically significant ( $p < 0.04$ ). Among the VATS group, pleuro-parenchymal adhesion was found in 32 (80%), multiple loculation in 27(67.5%), thickened pleura in 7(17.5%) cases. Most of the VATS were done under G/A 31(77.5%) and only 9 (22.5%) were done under L/A with conscious sedation. Our findings match with others' reports.<sup>18,19</sup>

The duration of hospital stays for a patient getting admitted with the diagnosis of empyema thoracis in the acute stage represents the efficacy of management. In our study, the duration varied from 8 days to 42 days in ICD group and from 9 to 40 days in VATS group. The mean duration of hospital stay in ICD group was  $25.78 \pm 4.04$  days whereas in VATS group it was only  $16.05 \pm 3.58$  days which was statistically significant ( $p < 0.001$ ). The patients who were treated successfully with the primary intervention itself (considered success) had a less duration of stay compared to the patients who needed second intervention (considered failure). The duration of chest tube in-situ represents the efficacy of the intervention in clearing the pleural cavity collection and also represents the morbidity of the patient in terms of pain suffered and restricted mobility. The duration varied from 8 days to 32 days in ICD group and from 5 to 16 days in case of VATS group. The mean duration of the chest tube in-situ was  $17.18 \pm 3.30$  days in ICD group whereas it was only  $8.23 \pm 2.09$  days in VATS group which was significantly shorter than that of the ICD group ( $p < 0.001$ ). One patient in ICD group had the longest duration of tube in-situ (32 days). The tube was in-situ for 20 days following the ICD and remaining 12 days were subsequent to thoracotomy because of the failure of the primary intervention. Nandeesh M and co-workers found that the mean duration of hospital stay in ICD group was 25.2 days whereas in VATS group it was only 15.5 days. In another study, the mean duration of the chest tube in-situ was 17.3 days in ICD group, whereas in VATS group it was only 8.1 days.<sup>20</sup> Other studies also found the similar result.<sup>21,17</sup>

Treatment cost is a major concern, especially in a developing country like ours. The cost incurred also represents the efficacy of the intervention done. The mean cost of the treatment was taka 19175.00 ± 1443.60 in ICD group whereas it was taka 12962.50 ± 1469.29 in VATS group ( $p < 0.001$ ). The calculated cost did not include the cost of the investigations such as CT scan. Obviously the patients who were cured with one primary intervention (success group) had to pay less. It has to be mentioned that the success group in ICD paid less than that of success group in VATS. Whereas, considering the greater number of failures, the mean cost in ICD group was definitely more. A study conducted by Elsayed HH et al. in Cairo, Egypt observed that the average cost of treatment Rs. 7,350\$ in ICD group and only Rs. 3,100\$ in VATS group.<sup>22</sup> Another study reported the results similar to our observation.<sup>23</sup>

In our study we observed that, the complication rate in the ICD group (77.5%) than VATS group (42.5%). Air leak, bleeding, surgical emphysema, encysted collection with thickened pleura, partially collapsed lung (trapped) were the complication in both groups. Most of the complications were managed conservatively except encysted collection with thickened pleura (21) and partial trapped lung (9), which needed second intervention. Similar observation was found in a study conducted by Shatila M et al.<sup>24</sup> We also found that in the ICD group, only 45% had successful treatment with the primary intervention. The remaining needed a second intervention in the form of VATS and thoracotomy. Whereas in the VATS group, 80% had success with primary intervention and only 20% patients needed thoracotomy. Several other researchers found results which were similar to our study.<sup>13,20,21,22</sup> There was no death in both groups which well matches with the observations by Wilson H and colleagues.<sup>25</sup>

### Conclusion:

We observed that in the management of acute empyema thoracis, VATS as a primary intervention was associated with less morbidity, shorter hospital stay with less treatment cost and high success rate. This study concludes that video-assisted thoracoscopic surgery (VATS) is better than conventional ICD tube insertion as a primary intervention of treatment in the management of acute empyema thoracis.

### Limitations of the study:

- The study was conducted in a single thoracic surgery center and therefore may not apply to those with different patient population.
- Since this study included a small size, further studies on a larger scale of patients should be conducted for proper assessment of the result which we had found.
- Long-term follow-up was beyond the scope of this study.

**Funding:** No funding sources.

**Conflict of interest:** No potential conflict of interest relevant to this study was reported.

### References:

1. Gupta DK, Sharma S; Management of empyema - Role of a surgeon. *J Indian Assoc Pediatr Surg* 2005;10:142-6. <https://doi.org/10.4103/0971-9261.16963>
2. Preetam Rajgopal Acharya, Kusum V. Shah; Empyema thoracis: A clinical study. *Annals of Thoracic Medicine - Vol 2, Issue 1, January-March 2007.* <https://doi.org/10.4103/1817-1737.30356> PMID:19724669 PMCID:PMC2732064
3. Solaini L, Prusciano F, Bagioni P; Video-assisted thoracic surgery in the treatment of pleural empyema. *Surg Endosc* 2007; 21:280-284. <https://doi.org/10.1007/s00464-006-0151-z> PMID:17122974
4. Parikh DH, Crabbe DCG, Auldist AW, Rothenberg SS; *Pediatric Thoracic Surgery.* Springer-Verlag London Ltd; 2009:110-1. <https://doi.org/10.1007/b136543>
5. Mitsunori Higuchi, Hiroyuki Suzuki; Current status and prospect of medical and surgical management for thoracic empyema. *Current Challenges in Thoracic Surgery, 2020.* <https://doi.org/10.21037/ccts.2020.02.09>
6. Coote N; Surgical versus non-surgical management of pleural empyema. *Cochrane Database Syst Rev.* 2002;(2):CD001956. <https://doi.org/10.1002/14651858.CD001956>
7. Tassi GF, Marchetti GP, Pinelli. Minithoracoscopy; a complementary technique for medical thoracoscopy. *Respiration.* 2011;82(2):204-206. <https://doi.org/10.1159/000324072> PMID:21447932
8. Tassi G, Marchetti G; Mini thoracoscopy: a less invasive approach to thoracoscopy. *Chest.* 2003;124(5):1975-1977. <https://doi.org/10.1378/chest.124.5.1975> PMID:14605075

9. Lackner RP, Hughes R, Anderson LA, Sammut PH, Thompson AB; Video assisted evacuation of empyema is the preferred procedure for management of pleural space infections. *Am J Surg.* 2000 Jan;179(1):27-30.  
[https://doi.org/10.1016/S0002-9610\(99\)00257-3](https://doi.org/10.1016/S0002-9610(99)00257-3)  
PMid:10737573
10. Molnar TF; Current surgical treatment of thoracic empyema in adults. *Eur Cardiothorac Surg* 2007; 32:422-430.  
<https://doi.org/10.1016/j.ejcts.2007.05.028>  
PMid:17646107
11. Matin TN, Glesson FV; Interventional radiology of pleural diseases. *Respirology.* 2011;16: 419-29.  
<https://doi.org/10.1111/j.1440-1843.2011.01948.x>  
PMid:21324048
12. Farhan Ahmad Majeed, Sohail Saqib Chatha, Usama Zafar et al; VATS thoroscopic decortication for empyema thoracic: A retrospective experience and analysis of 162 cases. *JPak Med Assoc, february2021; vol.71, no.2-A:502-4.*  
<https://doi.org/10.47391/JPMA.431>  
PMid:33819237
13. Mohammed Ali Farrag, Hatem Yazed Al Bawab, Nevine Mohamed Mohamed Abd ELfattah, Eman Badawy Abd Elfattah, Mahmoud Mohsen Mahmoud Khalil; Evaluation of the role of video - assisted thoroscopic surgery in management of empyema. *Egyptian Journal of Bronchology, Vol. 12 No. 4, 2018:419-426.*  
[https://doi.org/10.4103/ejb.ejb\\_23\\_18](https://doi.org/10.4103/ejb.ejb_23_18)
14. Shahin Y, Duffy J, Beggs D, Black E, Majewski A; Surgical management of primary empyema of the pleural cavity: outcome of 81 patients. *Interact Cardiovasc. Thorac. Surg.* 2010; 10:565-7.  
<https://doi.org/10.1510/icvts.2009.215004>  
PMid:20053696
15. Tamsin N. Cargill, Maged Hassan, John P. Corcoran et al; A systematic review of comorbidities and outcomes of adult patients with pleural infection. *Eur Respir J* 2019; 54: 1900541.  
<https://doi.org/10.1183/13993003.00541-2019>  
PMid:31391221 PMCID:PMC6860993
16. Apichat Tantraworasin , Asara Thepbunchonchai et al; Factors associated with recurrent bacterial empyema thoracis. *Asian Journal of Surgery* (2018); 41: 313-320.  
<https://doi.org/10.1016/j.asjsur.2017.02.009>  
PMid:28372933
17. Ilijaz Pilav, Alma Alihodzic Pasalic, et al; Efficacy of Video-Assisted Thoracoscopic Surgery (VATS) in the Treatment of Primary Pleural Empyema. *Original paper / acta inform med, 2020 dec; 28(4): 261-264.*  
<https://doi.org/10.5455/aim.2020.28.261-264>  
PMid:33627927 PMCID:PMC7879437
18. Claudia Ravaglia, Carlo Gurioli, Sara Tomassetti, Gian Luca Casoni ;Is Medical Thoracoscopy Efficient in the Management of Multiloculated and Organized Thoracic Empyema? *Respiration, 2012;84:219-224.*  
<https://doi.org/10.1159/000339414>  
PMid:22832393
19. Ahmed Hassan Ali Abo-El-maged, Mohamed Fahmy Elsamadony, Mousa Mohamed El-Shamly et al; Safety and efficacy of medical thoracoscopy in the management of loculated thoracic empyema. *Egyptian Journal of Chest Diseases and Tuberculosis, 66 (2017) :445-451.*  
<https://doi.org/10.1016/j.ejcdt.2016.12.013>
20. Nandeesh M., B.J. Sharathchandra, P.B. Thrishuli; ICD Versus VATS as Primary Treatment in Fibrinopurulent Stage of Empyema Thoracis .*Journal of Clinical and Diagnostic Research.* 2013 Dec;Vol-7(12): 2855-2858.
21. Shipra Sharma, Santosh Kumar Sonker, Sukh Lal Nirala; Prospective comparative study of video assisted thoracoscopic surgery versus conventional thoracostomy drainage in empyema thoracis in paediatric age group. *Sharma S et al. Int J Res Med Sci.* 2015 Oct;3(10):2538-2542.  
<https://doi.org/10.18203/2320-6012.ijrms20150786>
22. Hany Hasan Elsayed, Ahmed Mostafa, Essam Fathy et al; Thoracoscopic management of early stages of empyema: is this the golden standard? *Journal of Visualized Surgery, 2018;4:114.*  
<https://doi.org/10.21037/jovs.2018.05.18>  
PMid:29963403 PMCID:PMC5994441
23. K. Robert Shen, Alejandro Bribriescio, Traves Crabtree et al; The American Association for Thoracic Surgery consensus guidelines for the management of empyema. *The Journal of Thoracic and Cardiovascular Surgery, june 2017;153(6) :e129-e146.*  
<https://doi.org/10.1016/j.jtcvs.2017.01.030>  
PMid:28274565
24. Mohamed Shatila, Walid Abu Arab, Nader Fasih, Khaled Karara, Abdel Maguid Ramadan; Comparative study between outcome of intercostal tube drainage and video assisted thoracoscopic surgery in management of complicated parapneumonic effusion in children. *Journal of the Egyptian Society of Cardio-Thoracic Surgery* 26 (2018); 68-72.  
<https://doi.org/10.1016/j.jescts.2017.12.002>
25. Wilson H, Mohite P, Hall A, Anikin V; Timing and efficacy of VATS debridement in the treatment of parapneumonic empyema. *Arch Pulmonol Respir Care, 2016; 2(1): 016-019.*  
<https://doi.org/10.17352/aprc.000010>