

Scar Endometriosis, An Uncommon Entity

L SAHA

Summary:

Scar endometriosis is an uncommon condition where there is presence of endometrial tissue in the abnormal sites. Generally this is a benign lesion although malignant transformation is possible. Commonest site is at the site of laparoscopy done for non gynaecologic indications². Extrapelvic sites are fairly uncommon, among which abdominal wall may also be affected³. This case of scar

endometriosis was diagnosed after 2 years of caesarean section. Patient presented with pain and swelling below the umbilicus. Pain had a distinct relationship with the menstrual cycle. Swelling appeared later and was slowly increasing in size. There was a high index of suspicion based on history and clinical findings. Wide excision was done and histopathology reported the lesion as scar endometriosis.

(J Bangladesh Coll Phys Surg 2011; 29: 99-101)

Introduction:

Presence of functioning endometrium (glands and stroma) in sites other than uterine mucosa is called endometriosis. It is not a malignant condition although malignant transformation is possible¹.

The most common location is within the pelvis and has been reported to occur in as many as 44% of women undergoing laparoscopy for non-gynaecological symptoms².

However, extra pelvic endometriosis is a fairly uncommon disorder and difficult to diagnose. The various sites for extra pelvic endometriosis are bladder, kidney, bowel, omentum, lymph nodes, lungs, pleura, extremities, umbilicus, hernial sacs, and abdominal wall³.

Abdominal wall endometriomas often develop in previous surgical scars but there is a case report of a spontaneous occurrence also⁴. Majority of the scar endometriosis have been reported after obstetrical or gynaecological procedures such as caesarean delivery, hysterotomy, hysterectomy, episiotomy, and tubal ligations^{5,6,7} but few cases are also reported following appendectomy, in the laparoscopic trocar tract, amniocentesis needle tract. Scar endometriosis patients are often referred to the general surgeons because the clinical presentation suggests a surgical cause. In a study

by Blanco et al⁸ the diagnosis was initially confused with inguinal hernia, incisional hernia and abdominal wall tumor.

Here is the report of a case of scar endometriosis following caesarean section over a period of 2 years. This paper may play some role to increase the awareness among the clinicians regarding this rare condition, which is often misdiagnosed and hence delays the patients cure.

Case History:

A 28 year old lady, working as an assistant nurse, married for 7 years, having one child of 3 years and 6 months old referred to a gynaecologist with the complaints of localized painful swelling below umbilicus for 2 years. At first she had pain below umbilicus. Pain increased during the period of menstruation which became intolerable on the first day, decreased from the 2nd day onwards. But thereafter she had low grade pain in the area throughout the cycle. After eight months she noticed a swelling below umbilicus. Swelling was gradually increasing in size. Her obstetric history revealed delivery of a male baby by caesarean section due to primi gravida with breech presentation. She also complained of low grade dysmenorrhoea. She was found to be with good general health, not pale, normo-tensive. A swelling of 4 cm diameter, circumscribed, tender, not red or warm, was found 2 cm below the umbilicus and 5 cm above the caesarean scar. Swelling was non reducible, not fixed with the overlying skin but slightly fixed with underlying structure. On per vaginal examination uterus was found bulky, antverted and mobile. Based on characteristic history and examination findings, there was a high index of suspicion of endometriosis considering other possibilities like hematoma, granuloma,. Patient was

Dr. Laxmi Saha, FCPS Obstetrics and Gynaecology, Consultant Obstetrics and Gynaecology, Sonagazi Upazila Health Complex, Feni

Address of Correspondence: Dr. Laxmi saha, FCPS, Obstetrics and Gynaecology, Consultant Obstetrics and Gynaecology, Sonagazi Upazila Health Complex, Feni

Received : 17 May, 2009

Accepted : 17 September, 2009

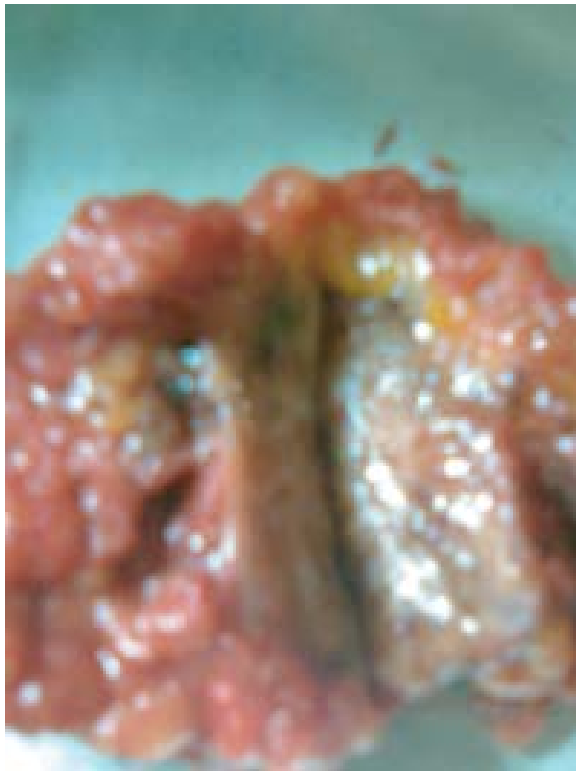

Fig-1: Gross appearance of the lesion (after surgical excision)

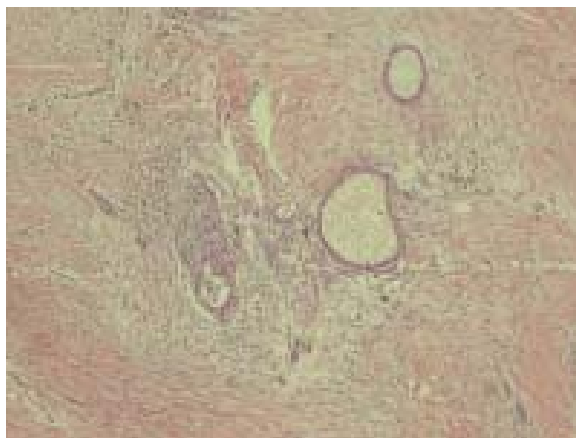


Fig:-2: Microscopic appearance of the lesion showing fibromuscular tissue containing endometrial gland and stroma

advised excision biopsy but initially she refused and preferred medical treatment if any. A trial of medical treatment was given with progesterone and analgesic for one month, as the patient had associated dysmenorrhoea. However, medical trial did not bring any benefit for the patient except slight improvement of dysmenorrhoea..

Finally wide excision of the swelling was done and histopathology reported the case as scar endometriosis. The patient is kept under regular follow-up.

Discussion:

Endometrioma is a well-circumscribed mass of endometriosis. Abdominal wall endometrioma presents as a painful swelling resembling surgical lesions such as hernias, hematomas, granulomas, abscess and tumors. So that is why these cases first report to general surgeons. This case was reported to the gynaecologist as the patient had exaggerated pain during menstruation.

Scar endometriosis most commonly occurs after operation on the uterus and tubes. Incidence of scar endometriosis following hysterotomy is 1.08-2% where as after cesarean section the incidence is 0.03-0.4%.⁷ The reason for higher incidence after hysterotomy has been given as the early decidua has more pluripotential capabilities and can result in cellular replication producing endometriomas.

Time interval between operation and presentation has varied from 3 months to 10 years in different series. The etiology of abdominal wall endometrioma is thought to be a result of transportation of endometrial tissue during surgical procedures and subsequently stimulated by estrogen to produce endometriomas. The simultaneous occurrence of pelvic endometriosis with scar endometriosis is infrequent⁷. This patient also did not have associated pelvic endometriosis. Preoperative diagnosis is difficult to make and sometimes the diagnosis is made after excision only. This particular case was diagnosed after excision histopathology.

Various diagnostic methods have been described in the literature. Till recently the use of ultrasonography (USG) have hardly been reported in detail and anecdotal reports have described it as nonspecific, can give a varied picture of hypo echoic mass with scattered internal echoes. Recently a large series of 12 patients where USG and color Doppler substantially contributed to the correct preoperative diagnosis⁹ and it is suggested that sonographic and color doppler when combined with clinical data may substantially contribute to the preoperative diagnosis. FNAC has been reported to be accurate in diagnosis but in a recent report by Dwivedi et al. FNAC was not diagnostic in any of the four patients who underwent this procedure^{10,11}. Anecdotal studies have mentioned the use of computed tomography (CT)

and magnetic resonance imaging (MRI) in making a diagnosis. CT usually shows a solid, well-circumscribed mass. MRI can be more helpful when the lesion is small because of its high spatial resolution, furthermore it perform better than CT scan in detecting the planes between muscles and abdominal subcutaneous tissue.¹² However, imaging technique was not used as a diagnostic tool in this case.

Treatment of choice is wide excision of the lesion and may sometimes require mesh placement which was not done in this patient. Medical treatment with the use of progestogens, oral contraceptive pills, and danazol is not effective and gives only partial relief in symptoms. Goel et al¹³ reported failure of medical treatment in their two cases as in this case. Recently there has been report of use of gonadotrophin agonist but only with the prompt improvement in symptoms with no change in the lesion size¹⁴. These patients need to be followed up because of the chances of recurrence, which require re-excision. In cases of continual recurrence possibility of malignancy should be kept in mind. To prevent the occurrence of scar endometriosis it has been suggested that at the end of surgery especially on uterus and tubes, the abdominal wall wound should be cleaned thoroughly and irrigated vigorously with high jet solution before closure¹⁵.

Conclusion

One should have a high index of suspicion of scar endometriosis when a woman presents with a painful swelling in the abdominal scar especially with a history of previous gynaecological or obstetrical surgery. This condition can be confused with other surgical conditions. Efforts should be made to make a preoperative diagnosis with the help of imaging techniques and FNAC. Medical treatment is not helpful. Wide excision is the treatment of choice. Patient should be followed-up for recurrence.

Acknowledgement:

The author acknowledges Prof Golam Mostafa, Professor of Pathology, NIDCH, Dhaka for providing with the histopathology slide of the lesion. Special thanks is also due to Dr Arjun C. Dey Senior Consultant

of Paediatrics, Infectious Disease Hospital, Dhaka to extend his constant support in preparing the manuscript.

References:

1. Dutta DC. Endometriosis and Adenomyosis. In: Textbook of Gynaecology. 4th edn West Bengal India. 2006:284-96
2. Rawson JM. Prevalance of endometriosis in asymptomatic women. *J Reprod Med* 1991;36: 513-5
3. Markham SM, Carpenter SE, Rock JA. Extra pelvic endometriosis. *Obstet Gynecol Clin North Am* 1989; 16: 193-219.
4. Ideyi SC, Schein M, Niazi M, Gerst PH. Spontaneous endometriosis of the abdominal wall. *Dig Surg* 2003; 20: 246-8.
5. Padmanabhan LD, Mhaskar R, Mhaskar A. Scar endometriosis. *J Obstet Gynaecol India* 2003; 53: 59-61.
6. Bhowmick RN, Paul P, Dutta S, Roy B. Endometriosis of laparotomy scar. *J Obstet Gynaecol India* 1986; 36: 130-2.
7. Chatterjee SK. Scar endometriosis: A Clinicopathological study of 17 cases. *Obstet Gynecol* 1980; 56: 81-4.
8. Blanco RG, Parithivel VS, Shah AK, Gumbs MA, Schein M, Gerst PH. Abdominal wall endometriomas. *Am J Surg* 2003; 185:596-8.
9. Francica G, Giardiello C, Angelone G, Cristaino S, Finelli R, Tramontano G. Abdominal wall endometriomas near cesarean delivery scars: sonographic and color doppler findings in a series of 12 patients. *J Ultrasound Med* 2000; 22:1041-7.
10. Simsir A, Thorner K, Waisman J, Cangiarella J. Endometriosis in abdominal scars: a report of three cases diagnosed by fine needle aspiration biopsy. *Am Surg* 2001;67:984-6.
11. Dwivedi AJ, Agarwal SN, Silva YJ. Abdominal wall endometriomas. *Dig Dis Sci* 2002 ;47:456-61.
12. Balleyguier C, Chapron C, Chopin N, Helenon O, Menu Y. Abdominal wall and surgical scar endometriosis. Results of magnetic resonance imaging. *Gynecol Obstet Invest* 2003; 55:220-4.
13. Goel P, Sood SS, R, Dalal A. Cesarean scar endometriosis - Report of two cases. *Indian J Med Sci* 2005; 59:495-8
14. Rivlin ME, Das SK, Patel RB, Meeks GR. Leuprolide acetate in the management of cesarean scar endometriosis. *Obstet Gynecol* 1995; 85:838-9.
15. Wasfie T, Gomez E, Seon S, Zado B. Abdominal wall endometrioma after cesarean section: a preventable complication. *Int Surg* 2002; 87: 175-7.