

Submental intubation in oral maxillofacial surgery

Quazi Billur Rahman*¹, Rajan Karmakar², Subrata Kumar Mondal³, AKM Faizul Hoque⁴,
Manash Kumar Basu⁵

¹Department of Oral and Maxillofacial Surgery, Bangabandhu Sheikh Mujib Medical University (BSMMU), Dhaka, ²Oral and Maxillofacial Surgeon, ³Department of Anaesthesia, Dhaka Medical College & Hospital, ⁴Bangabandhu Sheikh Mujib Medical University (BSMMU), ⁵Sir Salimullah Medical College & Hospital.

Corresponding author: Email: qureshinaz@yahoo.com

Abstract

Background: Oral and maxillofacial surgical procedures present a unique set of problems for both the anaesthetists and the surgeons. Simultaneous access to the oral or nasal cavities and dental occlusion is required for the surgical treatment of some craniofacial deformities. Generally, airway is maintained by orotracheal or nasotracheal intubation and some instances by tracheostomy however, nasotracheal intubation is contraindicated in skull base or midface fracture. Tracheostomy has inherent complications ranging from surgical emphysema to disfigurement where as orotracheal route prevents free access to oral cavity. In these circumstances, submento-tracheal intubation may provide a better option to overcome these problems.

Objective: The aim of this study was to evaluate outcome of conversion of orotracheal route to submentotracheal route for surgical correction of maxillofacial trauma & deformity and time required to change from oral to submental route, accidental extubation, postoperative complications, and the healing of intraoral and submental scars were evaluated.

Patients and Methods:

Method: A total of 23 patients were selected from maxillofacial department of BSMMU and other institutions from December 2007 to March 2011 to use this technique. After standard orotracheal intubation, a 2 cm incision was made lateral to the midline in the submentum and a blunt dissection opposite to the skin incision on the lingual aspect of the mandible provides access to the floor of the mouth, the orotracheal tube is disconnected and pulled through the floor of the mouth then to the submental incision, the tube is then sutured to the skin. Surgery was completed without interference from flexometallic endotracheal tube. Following surgery the sequence is reversed and the patients extubated in the conventional manner.

Results The technique was used in 13 patients with multiple facial fractures & 10 patients with facial deformity. The mean age of the group was 30 (20-50) years. The submental orotracheal intubation was completed successfully in all patients. No accidental extubations or tube injuries occurred. The mean time required for intubation was 6 minutes. All patients were extubated in the operating theatre. The intraoral and submental accesses healed with minimal scarring in all patients. There were no incidence of intra- or postoperative complications related to submental intubation.

Conclusions Submental intubation is a simple, safe, and predictable approach without significant morbidity that facilitated safe airway and enhances meticulous surgical procedure of fractured skull base and midface.

Keywords Airway management, Panfacial fractures, Orthognathic surgery, Submental intubation.

(JBSA 2012; 25(1): 21-27)

Introduction

Corrections of fractured craniomaxillofacial skeleton usually involve open reduction and precise rigid fixation by the mini- and microplate osteosynthesis. An important consideration during surgical procedure is the maintenance of airway without interfering to the reconstruction of

fractured segments. Essentially the anaesthesiologist and the surgeon are competing for the same space. The surgeon needs access to an unobstructed field; and in most instances for accurate functional reconstruction of facial fractures involving tooth-bearing segments of bone, a period of intraoperative Maxillomandibular fixation (MMF)

is essential to check for restoration of pretraumatic occlusion^{1,2}. Wear facets must be carefully checked against the corresponding dental elements and the teeth brought into normal intercuspation in centric relation. It is not possible without bringing the dentition together. Intraoperative MMF generally precludes the use of an orotracheal tube. Therefore, in these type of injuries and patient requiring orthognathic surgery the mode of intubation is controversial, with many anaesthesiologists arguing against nasal intubation. Nasotracheal intubation prohibits the midfacial degloving approach for LeFort II, LeFort III, nasoseptal, naso-orbito-ethmoid complex fractures and in orthognathic surgeries. Nasotracheal intubation is contraindicated in nasal fractures, fracture of cribriform plate of ethmoid, mid and pan-facial fractures where surgical reconstruction of fractures of the naso-orbito-ethmoidal complex is required³. Furthermore, nasal intubation may lead to complications in cases of skull base fracture, with the risk of creating a communication between nasal cavity and anterior cranial fossa, causing brain damage, leakage of cerebrospinal fluid, and meningitis^{4,5} while an orotracheal tube interferes with the maxillomandibular fixation, compromising the reduction and stabilization of fractured segment of the maxilla and mandible⁶. In situations where maxillomandibular fixation is required and nasoendotracheal intubation is contraindicated, a cricothyrotomy or tracheostomy has been the traditional method of airway control⁷. This procedure may involve a significant risk of iatrogenic complications such as tracheal stenosis, internal emphysema, damage to the laryngeal nerves, tracheoesophageal fistula and scarring^{8,9}. An alternative to the classic methods is the submental route for tracheal intubation. The technique consists of diverting the proximal end of an orotracheal tube through the floor of the mouth and submental region. This allows free intraoperative access to the dental occlusion and nasal pyramid without endangering patients with skull base trauma, and at the same time avoids transtracheal dissection^{10, 11, 12}. The objective of this study was to present the results of submental intubation in a case series of maxillofacial trauma and facial deformity patients and to evaluate the outcomes of this procedure for the anesthetic management of the patients.

Methods

This clinical study was conducted from October 2008 to March 2010. 15 male & 8 female patients of mean age 30 years (range, 20-50 years) who had midfacial fractures, including Le Fort I, II& III, along with naso-orbital ethmoidal (NOE), mandibular or panfacial fracture requiring surgical corrections and manipulation of both mandible & maxilla were selected for this study. The technique of submental intubation was adapted from the general principles published by Hernandez Altemir¹¹. The following variables was evaluated to assess the results of Altemir's intubation technique:

- 1) Time required for intubation
- 2) Accidental extubation
- 3) Postoperative complications (hemorrhage; injury to the sublingual glands, wharton's duct, or lingual nerve; orotracheal fistula; and infection) and
- 4) Healing of intraoral and submental scars.

The time required for submental intubation is the time from the fixation of the endotracheal tube after orotracheal intubation to the fixation of the endotracheal tube at submentum.

In addition, ages, sex, type of facial trauma were recorded. Patients with severe neurological damage, polytrauma and patients who need repeated operation anticipated were excluded from the study.

Intubation Technique

All the subjects were intubated orally either awake or after induction of general anaesthesia with a flexometallic cuffed endotracheal tube having an internal diameter of 7.0, 7.5 or 8.0. mm with a detachable connector. The oral part of the intubated endotracheal tube was pulled through the submental incision by the following steps.

After aseptic painting and draping of chin and mouth, 2% lignocaine with 1:100,000 adrenaline was infiltrated before skin incision was made in the paramedian plane of the submentum and about 1 cm from the lower mandibular margin.

A curved haemostat was passed to the floor of the mouth through the incision after piercing subcutaneous tissue, platysma, and deep cervical fascia mylohyoid muscle (Fig 1).

The tongue was lifted upward and pushed backward and the tip of the hemostat would be visible just below the mucosa of the floor of the mouth, anterior to Wharton's duct papillae.

A blunt dissection of about 1.5 cm was made parallel to the gingival margin, at the junction of the attached lingual alveolar mucosa and the free mucosa of the floor of the mouth (Fig 2).

The breathing circuit was separated from the endotracheal tube and its connector to facilitate easy passage through the submental incision.

The proximal part of the intubated endotracheal tube was held by the curved hemostat to bring it out from mouth cavity to the exterior through submental incision. During this step, endotracheal tube kept fixed in the trachea by anesthetist while surgeon pulls the free end of that endotracheal tube in to the submentum. Three minutes ventilation with 100% oxygen is mandatory to avoid hypoxaemia.

Finally endotracheal tube fixed by suture, connected to the breathing circuit and resume maintenance of anaesthesia as usual. And surgery started in an obstructed field where free access to the oral or nasal cavity and occlusal test could be performed for precise functional correction of midface or skull base fracture.

It is important to ensure that the tube has not been displaced during its passage through the tunnel. The tube was reconnected and secured to the skin with 2-0 silk sutures in a similar fashion like drain tube (Fig 3). The tube should be freely movable for intraoral manipulation. A pharyngeal pack was then inserted to seal the pharynx from & debris during surgery. Anatomical reduction, pretraumatic occlusion (Fig 5) and rigid internal fixation of the maxillofacial fractures were achieved by using miniplates osteosynthesis. Facial deformity was corrected by osteotomy and fixed with mini & microplate.

Temporary maxillomandibular fixation was used in all cases to achieve optimal maxillomandibular occlusion.

Absence of nasotracheal tube allowed the reduction of naso-orbital ethmoidal (NOE) fractures to be completed easily without distorting nasal anatomy.

At the end of the surgery, the maxillomandibular fixation was released and submental intubation converted to oral intubation. The endotracheal tube was pulled back intraorally in the reverse order (first the flexometallic tube, then the pilot tube cuff). The submental skin incision was closed with interrupted prolene sutures and the intraoral incision left to heal secondarily. The patients were followed up on regular basis at 1 week, 1 month and 6 months. Assessment was based on postoperative morbidity in terms of function and aesthetics.

Results

Most of the facial injuries were a combination of fractures affecting the dental occlusion (mandibular, maxillary, and dentoalveolar) and fractures of the midface (involving the nose region). Patients' demographic and clinical data are presented in Table I. Submental orotracheal intubation was completed successfully in all 23 patients. In all the subjects, submental intubation allowed simultaneous treatment of all the fractures without changing the method of intubation and without any interference from the tube during the operation. There was no difficulty in passing the tube through the floor of mouth, and the total duration of submental intubation procedure ranged from 5 to 9 minutes (mean, 6 minutes).

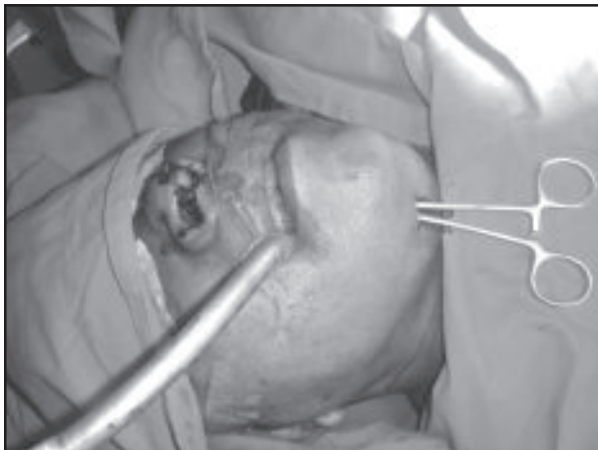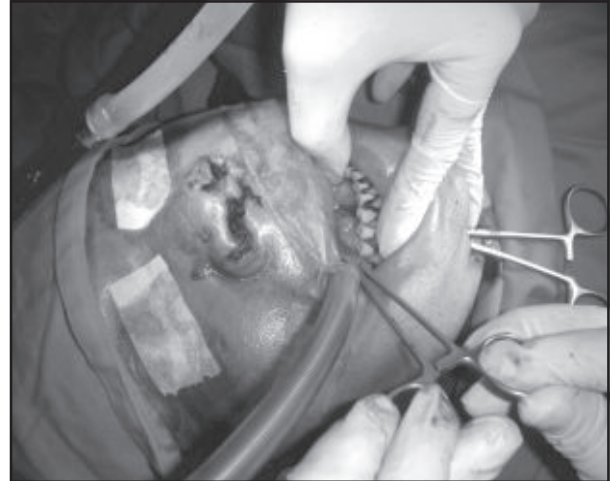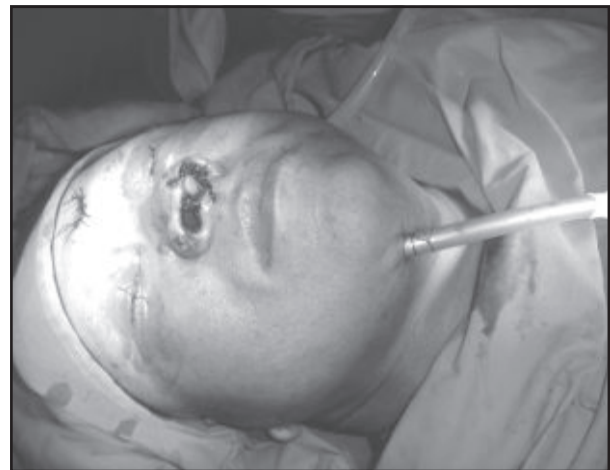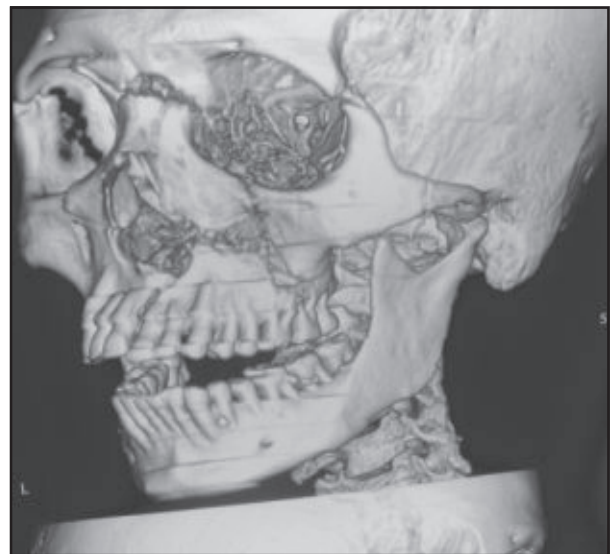
Disconnection of the standard connector from the tube was done easily. During this manoeuvre, there was no incidence of complications such as accidental extubation, exposure of the wires or loosening of the connector after re-attachment. Time period for disconnection from the ventilator ranged from 1 to 2 minutes (mean, 1.5 minutes), and there was no significant oxygen desaturation in any subject during the procedure. None of the subjects in the present study required postoperative ventilation. All 23 subjects were extubated in the operating theatre without postoperative-assisted ventilation.

Subjects were evaluated in the postoperative period at 1 week, 1 month and 6 months. No motor or sensory deficit was found. There was no complication regarding salivary gland or duct damage, Normal healing in the mucosa of the floor of the mouth was observed. No bleeding or infection in the area was noted. The scar has been well accepted by the subjects without any hypertrophic scarring or keloid.

Table I Patients managed by submental intubation

Age	Sex	Type of Patients
21	M	Class II open bite deformity
30	M	Mandible-Maxilla Le Fort III fracture
30	F	Mandible-Maxilla Le Fort II fracture
20	M	Facial asymmetry
40	M	Mandible- Maxilla Le Fort II-NOE* fracture
50	M	Pan facial fracture
24	F	Class III open bite deformity
22	F	Skeletal Class II malocclusion
35	F	Maxilla Le Fort II fracture
22	M	Facial Asymmetry
45	F	Mandible-Maxilla Le Fort III fracture
33	M	Pan facial fracture
26	M	Mandible-Maxilla Le Fort II-NOE* fracture
36	F	Le Fort II-NOE* fracture
23	F	Skeletal Class II malocclusion
48	M	Mandible- Maxilla-Nasal Bone fracture
20	F	Bi-Maxillary Proclination
42	M	Pan facial fracture
24	M	Mandible-Maxilla Le Fort II fracture
20	M	Skeletal Class III Malocclusion
35	M	Skeletal Class II Malocclusion
21	M	Class II Open bite deformity
23	M	Mandible-Maxilla Le Fort III fracture

*NOE- Naso ethmoid fracture

**Fig 1** Oral intubation and blunt dissection**Fig 2** Artery forcep in oral cavity**Fig 3** Submental endotracheal tube in situ**Fig 4** 3D CT scan of Midfacial Fracture

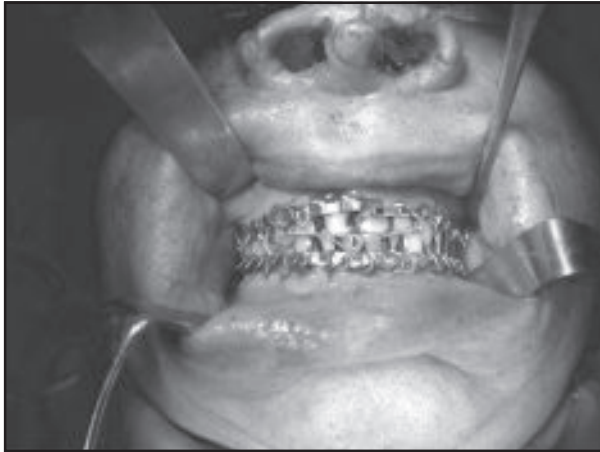


Fig 5 *Final occlusion after reduction*

Discussion

Maintaining safe airway is the primary concern during any maxillofacial surgery while unobscured freely accessible surgical field is necessary for accurate fixation of fractured facial skeleton. The alternative to orotracheal intubation significantly facilitates manoeuvres for reduction and stabilization of the jaws, which often requires immobilization with arch bars and wires. In orthognathic surgery oral intubations preclude checking occlusion during surgical procedure and nasal intubation distorts normal nasal anatomy. According to literature, retromolar intubation has been reported to have disadvantages like being more traumatic, obtrusive, costly and requiring more operating time¹³. Another alternative nasal tube switch technique was not performed due to problems associated with the intraoperative re-intubation, like risk of aspiration due to posterior nasal bleeding, potential airway compromise with need for emergency tracheostomy/cricothyroidotomy, unfavorable manipulation of an unstable cervical spine, excessive stress on fixations with possible loosening of plates and screws¹⁴.

Since the first description the submental intubation has undergone various modifications and found new indications¹². The main changes in the original technique by Hernandez¹¹ was avoidance of subperiosteal dissection on the lingual aspect of the mandible. Injury to the important structures in the floor of the mouth could be avoided by careful supraperiosteal blunt dissection of the passage as close as possible to the inner

side of the mandible. It could be safely used in patients with midfacial or panfacial fractures with possible base of skull fractures, as well as in patients undergoing elective Le Fort osteotomies or simultaneous elective mandibular orthognathic surgery and rhinoplasty procedure¹⁵. In our present series, submental intubations were possible in all the patients without any major complications, allowing unimpeded manipulation of the fractured fragments, satisfactory achievement of occlusion, establishment of maxillomandibular fixation and complete assessment of facial symmetry, as well as easy access to endotracheal tube for the anaesthesiologist. Average duration of technique was 6 minute. Moreover, extubation was found to be simple and took only 1,5 minutes(mean) and the cosmetic results were acceptable, with no long-term morbidity. In our series, no episodes of compromised airway or arterial desaturation occurred during the procedure. Other possible potential complications such as orocutaneous fistula, trauma to the submandibular and sublingual glands or canals, damage to the lingual nerve, and hypertrophic scar were also not observed. Antonio Figueiredo Caubi et al¹⁶ in 2008 studied on submental intubation in oral & maxillofacial surgery and they also found the same result. In another study done by Federico Biglioli et al¹⁷ in 2003 reported the same result except one case with superficial infection which is also consistent with our result. Another crucial decision during the management of patients with maxillofacial trauma is when to remove the endotracheal tube. Tracheal extubation of these patients must be done only after adequate evaluation. It is based on the patient's ability to maintain airway reflexes, the potential for residual respiratory depression, and airway edema. MacInnis and Baig¹⁸ proposed a midline approach for submental intubation. We agree with other authors that this approach can traumatize the Wharton's ducts, interferes with attachment of the genioglossi and geniohyoid muscles,¹⁹ and can cause injury to mandibular lingual perforating vessels, which are present in the midline in 98% of instances,²⁰ leading to bleeding and sublingual hematoma. We used a size 8 surgical glove finger covering the distal end of the tube, which facilitated tube passage through submental access and

protected from blood from entering. The present study reported excellent results with the use of submental endotracheal intubation for surgical treatment of 13 patients with panfacial fractures and 10 patients with facial deformity. In all cases, the planned surgery was completed without interference from the artificial airway and, most importantly, without compromising the airway. There are no incidence of complications related to submental intubation i.e. cuff leakage, infection or abscess in the wound and floor of the mouth, salivary fistula or mucocele, and hypertrophic scarring. All these complications are relatively rare and avoidable with meticulous technique.¹⁹ Submental intubation is a simple, safe, effective technique and bears very low morbidity for maxillofacial trauma patients and is suitable to replace tracheostomy where long-term ventilation is not required.

So this study concluded that Submental intubation ensures comfortibility for the surgical team by keeping the artificial air way from the surgical field and by doing so; make the surgical field unobstructed. Submental intubation is a useful alternative to airway management in patients with pan facial fractures and deformity. It provides a safe and reliable route for the endotracheal intubation while staying away of the surgical field, therefore, permitting intraoperative checking of the dental occlusion. Moreover, it is easy to adapt for the anaesthetist and surgeon to transfer the orotracheal route to submentotracheal route. In addition it doesn't need any special equipment. The simplicity of the technique with no specialized equipment or technical expertise required and quicker execution makes it especially advantageous. This technique therefore, when used in appropriate cases, allows both the surgeon and the anesthetist deliver a better quality of patient care.

References

1. Markowitz BL, Manson PN. Panfacial Fractures: Organization of treatment. *Clin Plast Surg*. 1989; 16:105–14
2. Shumrick KA, Kersten RC, Kulwin DR, Sinha PK, Smith TL. Extented access internal approaches for the management of facial trauma. *Arch Otolaryngol Head Neck Surg*. 1992; 118:1105–12
3. Muzzi DA, Losasso TJ, Cucchiara RF. Complication from a nasopharyngeal airway in a patient with a basilar skull fracture. *Anesthesiology* 1991; 74:366-8
4. Taher AA: Nasotracheal intubation in patients with facial fractures. *Plast Reconstr Surg* 90:1119, 1992
5. Seebacher J, Nozik D, Mathieu A: Inadvertent intracranial introduction of a nasogastric tube, a complication of severe maxillofacial trauma. *Anesthesiology* 42:100, 1975
6. Paetkau D, Strand M, Onc B. Submental orotracheal intubation for maxillofacial surgery. *Anesthesiology* 2000; 92: 912–914
7. Phero JC, Weaver JM, Peskin RM. Anesthesia for maxillofacial/mandibular trauma. In: Benumof JL, editor. *Anesthesiology clinics of North America. Anesthesia of otolaryngologic and head and neck surgery*. Philadelphia: Saunders; 1993. pp. 509–23
8. Taicher S, Givol N, Peleg M, Ardekian L. Changing indications for tracheostomy in maxillofacial trauma. *J Oral Maxillofac Surg*. 1996 Mar; 54(3):292-5
9. Amin M, Dill-Russell P, Manisali M, Lee R, Sinton I. Facial fractures and submental tracheal intubation. *Anaesthesia*. 2002 Dec; 57(12):1195-9
10. Haddock AR, Barnard NA. Maintaining the airway during the treatment of severe facial injuries. *Br Dent J*. 1993 Jan 23; 174(2):56-7
11. Hernández Altemir F. The submental route for endotracheal intubation. A new technique. *J Maxillofac Surg*. 1986 Feb; 14(1):64-5
12. Green JD, Moore UJ. A modification of submental intubation. *Br J Anaesth*. 1996 Dec; 77(6): 789-91
13. Martinez- Lage JL, Eslava JM, Cebrecos AI, Marcos O. Retromolar intubation. *J Oral Maxillofac Surg*. 1998; 56:302–6
14. Werter JR, Richardson G, Mcilwain MR. Nasal tube Switch: Converting from nasal to an oral

- endotracheal tube without extubation. *J Oral Maxillofac Surg.* 1994; 52:994-6
15. Biglioli F, Mortini P, Goisis M, Bardazzi A, Boari N. Submental orotracheal intubation: An alternative to tracheotomy in transfacial cranial base surgery. *Skull Base.* 2003;13: 189-95
 16. Antonio FC, Belmiro CV, Ricardo HV, Hecio Henrique AM, Nelson SR. Submental intubation in oral maxillofacial surgery: Review of the literature and analysis of 13 cases. *Med Oral Patol Oral Cir Bucal.* 2008 Mar;13(3):E197-200
 17. Federico B, Pietro M, Mario G, Alessandro B, Nicola B. Submental Orotracheal Intubation: An Alternative to Tracheotomy in Transfacial Cranial Base Surgery. *Skull Base: An Interdisciplinary Approach.* 2003;13(4): 189-195
 18. MacInnis E, Baig M: A modified submental approach for oral endotracheal intubation. *Int J Oral Maxillofac Surg* 28:344, 1999
 19. Schütz P, Hamed HH: Submental intubation versus tracheostomy in maxillofacial trauma patients. *J Oral Maxillofac Surg* 66:1404, 2008
 20. Cova M, Ukmar M, Bole T, et al: Evaluation of lingual vascular canals of the mandible with computed tomography. *Radiol Med* 106:391, 2003