



ORIGINAL ARTICLE

Surgical Reconstruction of Old and Neglected Tendo Calcaneus Injury: Experience of 20 Cases in Bangladesh

Md. Nazrul Islam¹, Md. Rabiul Islam², Tahmina Begum³, Md. Moshabbirul Islam⁴, SM Syeed-UI-Alam⁵

¹Associate Professor, Department of Orthopedic Surgery, Ad-Din Sokina Women's Medical College, Jashore, Bangladesh; ²Assistant Professor, Department of Otolaryngology & Head-Neck Surgery, Mugda Medical College, Dhaka, Bangladesh; ³Assistant Professor and Head, Department of Pathology, Mugda Medical College, Dhaka, Bangladesh; ⁴Post-Graduate Student (Orthopedic Surgery), National Institute of Traumatology & Orthopedic Rehabilitation, Dhaka, Bangladesh; ⁵Assistant Professor, Department of Surgery, Bangabandhu Sheikh Mujib Medical University, Dhaka, Bangladesh

Abstract

Background: Treatment of old and neglected rupture of Tendo calcaneus is difficult due to formation of wide gap between the two ends. **Objective:** This present study was aimed to assess the post-operative outcomes of surgical reconstruction of old and neglected Tendo calcaneus injury. **Methodology:** This was a non-randomized clinical trial which was conducted at Department of Orthopedic Surgery, Ad-Din Sokina Women's Medical College, Jashore, Bangladesh from January 2017 to December 2020 for a period of 4 years. The patients aged between 18 to 60 years were selected for this study after fulfilling the inclusion and exclusion criteria. **Results:** All patients were non diabetic and normotensive. Affected Tendons were on both sides. Out of 20 patients 16 male and 04 were female. Twenty patient from 18 to 60 year were included in this study and obtained excellent result with this reconstruction surgery. Success rate was considered almost 100 percent. Only one patient developed mild wound infection. **Conclusion:** Old neglected rupture of Tendo calcaneus is very difficult problem as patients become unable to walk properly. [*Journal of Current and Advance Medical Research, January 2023;10(1):3-6*]

Keywords: Surgical reconstruction; old and neglected; tendo calcaneus injury

Correspondence: Dr. Md. Nazrul Islam, Associate Professor, Department of Orthopedic Surgery, Ad-Din Sokina Women's Medical College, Jashore, Bangladesh; **Cell no.:** +8801776513618; **Email:** nazruldr.14@gmail.com; **ORCID:** <https://orcid.org/0009-0000-9342-6585>
©Authors 2023. CC-BY-NC

Introduction

Treatment of old neglected is challenging due to formation of wide gap between two ends of ruptured Tendo calcaneus¹. It is never possible to repair end to end so reconstruction surgery is the only way of treatment. Injuries of the Tendo calcaneus are relatively common in middle-aged athletes. Tendinitis, trauma due to RTA and fall from height and abuse of steroid injection into the tendon². Disruption also can occur from a direct blow to the

contracted tendon or from a laceration. An inability to bend the foot downward or "push off" the injured leg when walking³. An inability to stand on the toes on the injured leg. A popping or snapping sound when the injury occurs.

Treatment of old and neglected rupture of Tendo calcaneus is difficult due to formation of wide gap between the two ends but this problem can be overcome by reconstruction surgery of various

procedures like Turco's and pankovis and Boswoth procedures⁴.

Turco's procedure is better by applying peroneus brevis tendon. This present study was aimed to assess the post-operative outcomes of surgical reconstruction of old and neglected Tendo calcaneus injury.

Methodology

Study Settings and Population: This was a non-randomized clinical trial which was conducted in the Department of Orthopedic Surgery at Ad-Din Sakina Women's Medical College, Jashore, Bangladesh and at different private institutes in that area from January 2017 to December 2022 for a period of six years. The patients with the age group of 20 to 70 years were selected as study population. Fractures were on both sides. The ages of defects were from few days to months.

Surgical Procedure: Patient were operated under regional anesthesia (spinal). Patient was placed in prone position. Affected limb was cleaned properly and draping done over the operated area. A longitudinal midline incision was given to expose the Tendo calcaneus including the two injured ends. A small incision given over the base of fifth metatarsal and peroneus brevis tendon was exposed and cut. Then this peroneus brevis Tendon released proximally.

Lateral septum was incised and the peroneus brevis Tendon was drawn through the 1st incision. Tow slits were made in coronal plane one in the distal end one in the proximal end. The tip of the cut peroneus brevis tendon pushed through the slit of distal end from lateral to medial and then pushed from lateral to medial side through the slit of proximal end. Then distal part of the peroneus brevis tendon pulled upward and stitched with proximal part of the peroneus brevis Tendon and

Tendo calcaneus with nonabsorbable suture material (prolin 1/0). The wounds were closed with placing a drain tube in situ. Skin closed with applying sterile dressing and a short leg cast placed gravity equines. After 48 hours' drain tube removed and one 12th postoperative day stitches off.

Usually after one-month Cast is removed and patient were allowed to walk with 50% weight bearing and successively advised to walk with full weight bearing and without crutch and patient also advised to come for follow up.

Follow up and Outcomes Measures: After 48 hours' drain tube removed and on 12th POD stitches off. And sometime compression was applied for rigid fixation and usually after one-month patient were allowed to walk with 50.0% weight bearing and successively advised to walk with full weight bearing and without crutch and patient also advised to come for follow up.

Statistical Analysis: Statistical analyses were performed with SPSS software, versions 27.0 (IBM SPSS Statistics for Windows, Version 27.0. Armonk, NY: IBM Corp.). Continuous data that were normally distributed were summarized in terms of the mean, standard deviation, median, minimum, maximum and number of observations. Categorical or discrete data were summarized in terms of frequency counts and percentages. For end points analysis, Chi-square test was used for categorical variables and an analysis of variance (Student t Test) for continuous outcomes. Baseline characteristics were presented by treatment group. When values are missing, the denominator were stated. Every effort was made to obtain missing data, even after the follow-up time had passed. A two-sided P value of less than 0.05 was considered to indicate statistical significance.

Patients who will withdraw consent to participate in the study were included up to the date of withdrawal, with the exception of the analysis of death from any cause. For survival analyses, Kaplan–Meier estimates was generated. We were calculated Kaplan–Meier estimates of the cumulative proportion of patients with events, with the number of patients at risk indicated below the plot at specific time points. In efficacy time-to-event analyses, we were censored data for patients in whom the event of wound infection had not occurred at either the censoring date for the primary analysis.

Ethical Clearance: All procedures of the present study were carried out in accordance with the principles for human investigations (i.e., Helsinki Declaration) and also with the ethical guidelines of the Institutional research ethics. Formal ethics approval was granted by the local ethics committee.

Participants in the study were informed about the procedure and purpose of the study and confidentiality of information provided. All participants consented willingly to be a part of the study during the data collection periods. All data were collected anonymously and were analyzed using the coding system.

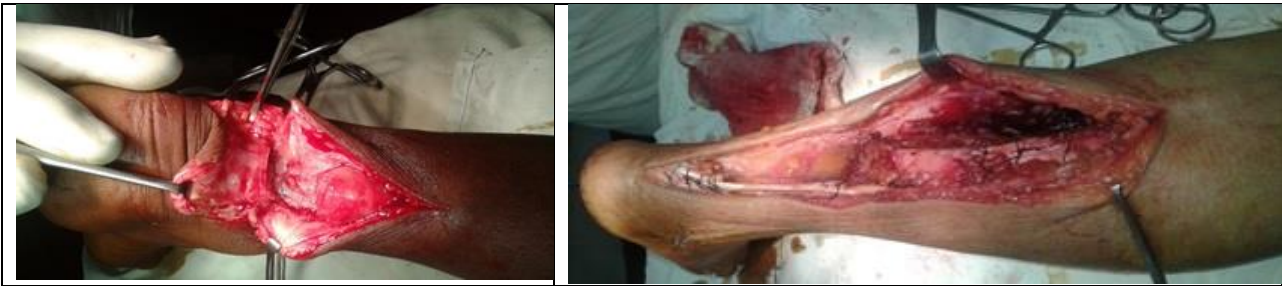

Figure I & II: Operative Procedure

Results

A total number of 20 patients were recruited for this study. Most of the patients were in less than 40 years of age group which was 11(55.0%) cases and the rest of 9(45.0%) cases in the age group of more than 40 years. The mean age with SD of the study population was 39.7±12.14 years with the range of 20 to 60 years (Table 1).

Table 1: Age Distribution of Study Population

Age Group	Frequency	Percent
Less Than 40 Years	11	55.0
More Than 40 Years	9	45.0
Total	20	100.0
Mean±SD (Range)	39.7±12.14(20-60)	

Male was predominant than female which was 16(80.0%) cases and 4(20.0%) cases respectively. The ratio of male and female was 4:1 (Table 2).

Table 2: Gender Distribution of Study Population

Gender	Frequency	Percent
Male	16	80.0
Female	4	20.0
Total	20	100.0

In this study history of smoking was found in 45.0% cases (Figure I).

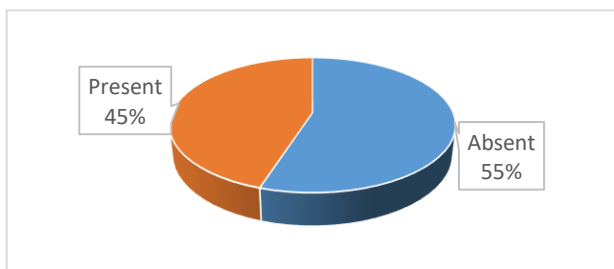


Figure I: Showing Smoking History among Study Population (n=20)

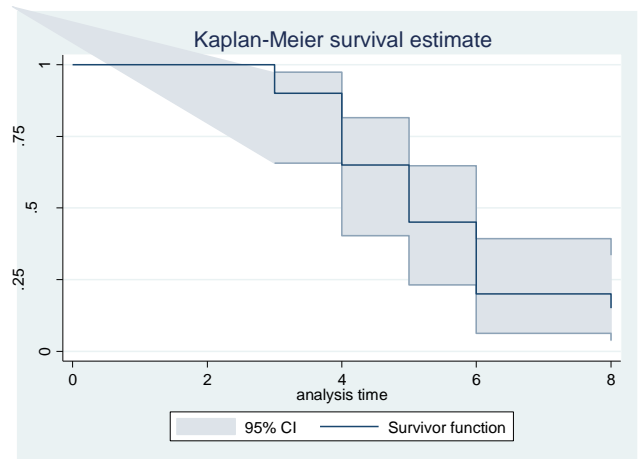


Figure II: Showing the Kaplan-Meier curve of Survival

The survival analysis was performed to see the Kaplan-Meier curve of survival with the 95% confidence interval (Figure II).

Discussion

Tendo calcaneus has been related to a relatively hypo vascular area among the tendons⁵. The major blood supply of the tendon is through its mesotendon, with the richest supply through the anterior mesentery. With increasing age this anterior mesenteric supply has been shown to be reduced.

Age-dependent changes in collagen cross- linking results in increased stiffness and loss of viscoelasticity, predisposing to injury. Most commonly the mechanisms of tendo calcaneus rupture are pushing off with the weight bearing forefoot while extending the knee, sudden unexpected dorsiflexion of the ankle, and violent dorsiflexion of the plantar flexed foot as in a fall from a height. In cases of recent injury end to end repair is possible but in old neglected cases wide gap is formed due to retraction of two ends⁶.

Therefore, end to end repair is impossible. So reconstruction surgery is only way of treatment and there are various procedures are available for reconstruction like V-Y plasty of Abraham and pankovics procedure, teuffer procedure and turco's procedure, Boswath procedure. It was selected the turco's procedure for reconstruction of my patients as this procedure of reconstruction is reinforced by peroneus brives tendon but in case of pankovis (V-Y plasty) and boswath procedure there are chance of infection due to release of gastrocnemius muscle with sheath and bleeding during release and necrosis of the released muscle and sheath⁷.

Conclusion

Turco's procedure is versatile, reliable and useful in reconstruction of Tendo calcaneus rupture. The procedure is simple and can provide the coverage of the defect. So I preferred this procedure and perform the operation. And all of my patient became well and satisfied as they were able to walk as before. Therefore, this operation was performed for normal wellbeing of the patients as before and all patients became well.

Acknowledgements

None

Conflict of Interest

The authors have no conflicts of interest to disclose

Financial Disclosure and Funding Sources

This study has been performed without any funding from outside else.

Contributions to authors: Islam MN, Islam MR, Begum T, prepared the manuscript from protocol preparation upto report writing. Islam MM, Syeed-UI-Alam SM have revised the manuscript. All authors involved from protocol preparation up to manuscript writing & revision.

Data Availability

Any inquiries regarding supporting data availability of this study should be directed to the corresponding author and are available from the corresponding author on reasonable request.

Ethics Approval and Consent to Participate

Ethical approval for the study was obtained from the Institutional Review Board. As this was a prospective study the written informed consent was obtained from all study participants. All methods were performed in accordance with the relevant guidelines and regulations.

Copyright: © Islam et al. 2023. Published by *Journal of Current and Advance Medical Research*. This is an open access article and is licensed under the Creative Commons Attribution Non Commercial 4.0 International License (CC BY-NC 4.0). This article is published under the Creative Commons CC BY-NC License (<https://creativecommons.org/licenses/by-nc/4.0/>). This license permits use, distribution and reproduction in any medium, provided the original work is properly cited, and is not used for commercial purposes. To view a copy of this license, please See: <https://creativecommons.org/licenses/by-nc/4.0/>

Cite this article as: Islam MN, Islam MR, Begum T, Islam MM, Syeed-UI-Alam SM. Surgical Reconstruction of Old and Neglected Tendo Calcaneus Injury: Experience of 20 Cases in Bangladesh. *J Curr Adv Med Res* 2023;10(1):3-6

ORCID

Md. Nazrul Islam: <https://orcid.org/0009-0000-9342-6585>

Md. Rabiul Islam: <https://orcid.org/0009-0006-7480-6172>

Tahmina Begum: <https://orcid.org/0009-0000-4302-9338>

Md. Moshabbirul Islam: <https://orcid.org/0009-0000-2630-0683>

SM Syeed-UI-Alam: <https://orcid.org/0009-0003-8639-6033>

Article Info

Received: 17 April 2023

Accepted: 12 May 2023

Published: 1 July 2023

References

- Järvinen TA, Kannus P, Maffulli N, Khan KM. Achilles tendon disorders: etiology and epidemiology. *Foot Ankle Clin* 2005;10:255-266.
- Sheth U, Wasserstein D, Jenkinson R, Moineddin R, Kreder H, Jaglal SB. The epidemiology and trends in management of acute Achilles tendon ruptures in Ontario, Canada: a population-based study of 27 607 patients. *Bone Joint J* 2017;99-B:78-86.
- Nilsson-Helander K, Silbernagel KG, Thomeé R, et al. Acute achilles tendon rupture: a randomized, controlled study comparing surgical and nonsurgical treatments using validated outcome measures. *Am J Sports Med* 2010;38:2186-2193.
- Ganestam A, Kallemose T, Troelsen A, Barford KW. Increasing incidence of acute Achilles tendon rupture and a noticeable decline in surgical treatment from 1994 to 2013: a nationwide registry study of 33,160 patients. *Knee Surg Sports Traumatol Arthrosc* 2016;24:3730-3737.
- Soroceanu A, Sidhwa F, Aarabi S, Kaufman A, Glazebrook M. Surgical versus nonsurgical treatment of acute Achilles tendon rupture: a meta-analysis of randomized trials. *J Bone Joint Surg Am* 2012;94:2136-2143
- Twaddle BC, Poon P. Early motion for Achilles tendon ruptures: is surgery important? A randomized, prospective study. *Am J Sports Med* 2007;35:2033-2038
- Olsson N, Silbernagel KG, Eriksson BI, et al. Stable surgical repair with accelerated rehabilitation versus nonsurgical treatment for acute Achilles tendon ruptures: a randomized controlled study. *Am J Sports Med* 2013;41:2867-2876