

CASE REPORT

Lingual Thyroid Diagnosed As a Cause of Cretinism: A Case Report

Jasmine Ara HAQUE¹, Hosne Ara RAHMAN², Waseka Akhter JAHAN³

¹Principal Medical Officer, Institute of Nuclear Medicine and Allied Science, Mitford, Dhaka, Bangladesh;
²Principal Medical Officer, Institute of Nuclear Medicine and Allied Science, Mitford, Dhaka, Bangladesh;
³Assistant Professor, Department of Biochemistry, National Institute of Neurosciences & Hospital, Dhaka, Bangladesh

(Received: 20 January 2014; Reviewed: 21 March 2014; Accepted: 31 March 2014)

Abstract

Hypothyroidism is one of the common endocrine disorders. Causes are variable. It can be congenital or acquired. Congenital hypothyroidism termed as cretinism. Lingual thyroid is one of the rare congenital anomaly causing hypothyroidism. Its clinical incidence varies between 1/3000 and 1/10,000. Up to 70% of patients with lingual thyroid have hypothyroidism and 10% suffer from cretinism. Here a 14 year old short stuttered obese female present with the complaints of voice change & weight gain. Biochemically she was diagnosed as hypothyroid. To find out the cause it was detected the gland was not in normal position but in the lingual position which was detected by SPECT CT Tc-99m isotope thyroid scan. The patient was treated with levo-thyroxin accordingly and was improved.

Keywords: Hypothyroidism, lingual thyroid, cretinism

[Cite this article as: Haque JA, Rahman HA, Jahan WA. Lingual Thyroid Diagnosed As a Cause of Cretinism: A Case Report. J Curr Adv Med Res 2014;1(2):42-45]

Correspondence: Dr. Jasmine Ara Haque, Principal Medical Officer, Institute of Nuclear Medicine and Allied Science, Mitford, Dhaka, Bangladesh; **Email:** drjasminebd@yahoo.com; **Cell no.:** +8801711348595

Contributions to authors: JAH & HAR have contributed in the diagnosis of the case. WAJ has prepared & revised the manuscript.

Introduction

Lingual thyroid is an unusual presentation of thyroid gland which was first described by Hickman¹. This is a rare embryological anomaly characterized by the presence of thyroid tissue outside its normal position resulting from a defect of the thyroid diverticulum migration from the base of the tongue, place of appeared, until its final pre-tracheal position. The prevalence of lingual thyroid is approximately 1 per 100,000 to 300,000 patients²⁻⁴ and 1 in 4000 cases of

thyroid disease^{3,5}. Female predominance is seen ranging from 75 to 89% of the all lingual thyroid cases^{4,6-8}. Usually it presents as an asymptomatic nodular mass of the posterior lingual midline, usually less than a centimetre in size sometimes reaching more than 4 cm in size. Larger lesions can present with local symptoms including dysphagia, dysphonia and dyspnoea^{6,9}. Occasionally respiratory difficulty or haemorrhages can occur¹⁰. At least 15% of patients either present with hypothyroid at the time of diagnosis¹. In this present case report a

14 year old girl was presented with a lingual thyroid at a tertiary care hospital in Dhaka.

Case Presentation

A 14 year old female referred to the Centre for Nuclear Medicine & Ultrasound at Mitford Hospital, Dhaka with the complaint of change of voice & weight gain. The patient was also complaint of sleepiness and constipation. Interestingly the patient didn't give any history of dyspnoea or dysphasia. The routine laboratory investigations were reported as normocytic normochromic anaemia (Hb% 11.8 mg/dl). On examination the patient was a short stuttered female according to the age and skin was rough. During evaluation of thyroid hormones FT3 level was normal (4.7 pmol/ml); FT4 level was in lower limit (10.0 pmol/ml) and thyroid stimulating hormone (TSH) level was elevated (55.3 mIU/dl). Later on the patient was diagnosed as a case of hypothyroidism.

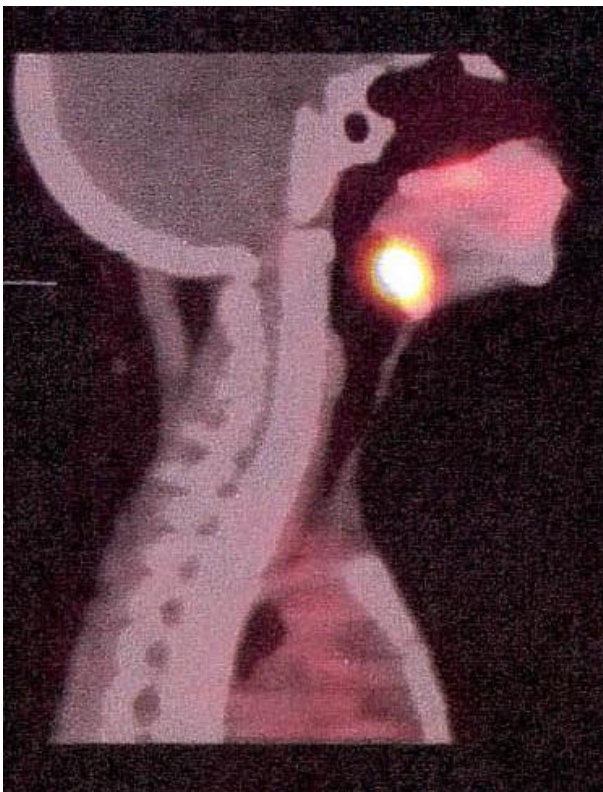

Figure I: Thyroid scan showing the Lingual Thyroid

Neck ultrasound for thyroid gland status was shown no thyroid tissue in thyroid bed as well as no lymphadenopathy. The patient was advised for isotope thyroid scan with Tc-99m and was found that atypical isotope activity in the oral cavity. The patient was done SPECT/CT and was confirmed the location of thyroid activity in the back of the tongue. It was diagnosed as lingual thyroid. Finally it was confirmed as thyroid tissue with biopsy. The patient was treated with levothyroxin (100 micro gm /day) in early morning before breakfast and was improved in next multiple follow-ups. At present the patient was biochemically euthyroid.

Discussion

Cretinism is a condition that results from inadequate secretion of thyroid hormones during fetal life or early infancy¹. The brain and skeleton fail to develop properly, resulting in mental retardation and dwarfism⁶. Cause of cretinism is unknown³. Some authors described that it is the result of a congenital deficiency in the secretion of the hormone thyroxin from the thyroid gland^{8,10}. In some cases, this is thought to be caused by an insufficient amount of iodine in the diet of the child's mother during pregnancy¹¹⁻¹². Routine screening of TSH levels in the blood spot samples obtained 5-7 days after birth has revealed an incidence of approximately 1 in 3000 resulting from either thyroid agenesis, ectopic or hypoplastic glands or dysmorphogenesis¹¹. The patient came to our centre with the complaint of unusual gaining weight with short stature. On examination she got the typical feature of rough skin with hoarseness of voice. Hormone assay shows that there was raised TSH level and low FT3 and FT4 level.

Lingual thyroid is the term applied to a mass of ectopic thyroid tissue located at the tongue base at the midline, usually between the circumvallate papillae and the epiglottis, in the area of the foramen caecum¹³. It is believed to result from defective descent of the thyroid anlage from its embryonic position at the base of the tongue to its normal pretracheal location,

which usually occurs on weeks 3 to 7 of embryonic development.

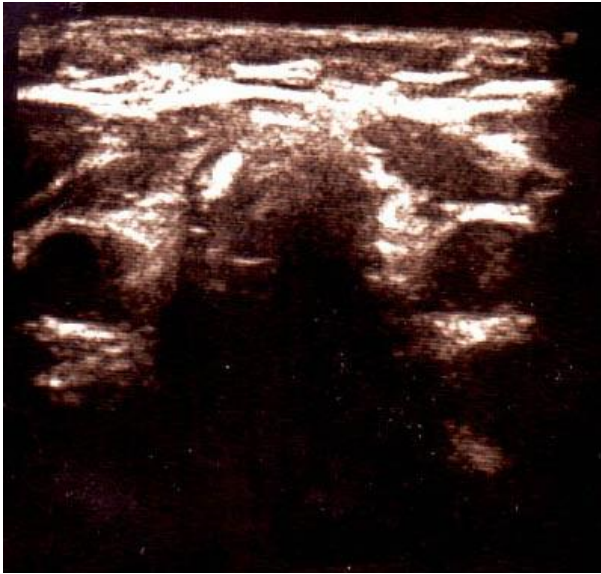


Figure II: USG of Lingual Thyroid

Defects in migration may lead to locations of the thyroid gland in other midline structures such as the trachea, the esophagus, or near the hyoid bone¹⁴. This is the most common benign mass found at the junction of the anterior two thirds and the posterior one third of the tongue. Postmortem studies indicate that up to 10% of people have thyroid tissue remnants near the base of their tongue¹⁵⁻¹⁶ although clinically apparent lingual thyroid is an unusual condition, with a few hundred cases reported in the literature. The estimated frequency of clinically significant lingual thyroid varies between 1/3000 and 1/10,000¹⁷. In 70% of these cases, the lingual thyroid is the only functional thyroid tissue¹⁸. Hypothyroidism is observed in an estimated 33% of the cases and is commonly precipitated by increased physiologic demands¹⁸. This entity is much more prevalent in females, with a male-to-female ratio of 1:3 to 1:8¹³. The pathogenesis of this condition remains unknown. It is postulated that maternal antithyroid antibodies may arrest the gland's descent and predispose the patient to poor thyroid function later in life¹⁶. The incidence of thyroid disease among family members of patients with lingual thyroid is higher than among the population¹⁷. A technetium scan should be used to confirm the diagnosis. These

scans frequently show radionuclide activity at the level of the mouth and no apparent activity in the normal position in the neck. CT provides an accurate method of determining the gland size, and it can be performed without contrast, because the thyroid tends to accumulate iodine. Here we used SPECT-CT scan of thyroid gland with Tc-99m radio isotope a hybrid technique for the detection of ectopic thyroid tissue which helps the physician to find out the exact location of activity. The standard treatment of lingual thyroid varies. Surgical treatment is preferred when there are symptoms like dysphagia or dyspnoea. In patient with obstructive symptom, Iodine-131 ablation of ectopic thyroid tissue has been proven successful and may be advantageous than surgery. In patient lacking thyroid tissue in the neck, the lingual thyroid can be excised and auto-transplanted to the muscles of the neck. In this case, the lingual mass was small and was not producing any symptom¹⁸. She was treated with levothyroxin (150 micro gm /day) in early morning before breakfast and was improved in her next follow-ups. At present the patient is biochemically euthyroid.

Conclusion

Congenital hypothyroidism due to lingual thyroid is an easily treatable condition. Appropriate biochemical, physiological and anatomical investigations are needed along with clinical diagnosis for proper management.

References

1. Hayat BM, Saif SM, Farhana B, Ali G. Adult Cretinism with Lingual Thyroid presenting as Menorrhagia. *Internat J Clin Cases Invest* 2011;2(6):44:48
2. Weider DJ, Parker W. Lingual thyroid: review, case reports, and therapeutic guidelines. *Ann Otol Rhinol Laryngol* 1977; 86: 841-847
3. Yeung VTF, Edward PL, Cockram CS. Cretinism and lingual thyroid presenting in an adult. *Postgraduate Med J* 1987; 63: 881-883
4. Neinas FW, Gorman CA, Devine KD, Woolner LB. Lingual thyroid: clinical characteristics of 15 cases. *Ann Int Med* 1973; 79: 205-210
5. Orti E, Castells S, Qazi QH, Inamdar S. Familial thyroid disease: lingual thyroid in two

- siblings and hypoplasia of a thyroid lobe in a third. *J Pediatr* 1971; 78: 675
6. Amani MEA, Benabadji N, Benzian Z, Amani S. Ectopic lingual thyroid. *Indian journal of nuclear medicine*. *Indian J Nucl Med* 2012; 27(2): 124–126
 7. Baughman RA. Lingual thyroid and lingual thyroglossal tract remnants: a clinical and histopathologic study with review of the literature. *Oral Surg* 1972;34:781–798
 8. Blizzard, R.M., Chandler, R.W., Landing, B.H. et al. Maternal autoimmunization to thyroid as a probable cause of athyrotic cretinism. *N Engl J Med* 1960, 263: 327-341
 9. Chowdhury WA, Chowdhury MR, Chowdhury EH. Lingual Thyroid-A Case Report. *Dinajpur Med Col J* 2010; 3 (1): 45-46
 10. Colledge N, Walker B, Ralston S. Davidson's principles and practice of medicine, 21st edition. 2010, p 922-969
 11. Johnson JC, Coleman LL. Magnetic resonance imaging of a lingual thyroid gland. *Pediatric Radiology* 1989;19:461–462
 12. Monroe JB, Fahey D. Lingual thyroid. *Arch Otolaryngol Head Neck Surg* 1975; 101:574–576
 13. Montgomery ML. Lingual thyroid:a comprehensive review. *West J Surg* 1935;43: 661-669
 14. Neinas FW, Gorman CA, Devine KD, Woolner LB. Lingual thyroid: clinical characteristics of 15 cases. *Ann Int Med* 1973;79: 205-210
 15. Grossman A, Olonovski D, Barenboim E. Hypothyroidism caused by a nonvisible lingual thyroid. *Head & neck* 2004;26:995-998
 16. Sauk JJ. Ectopic lingual thyroids. *J Pathol* 1970;102:239–243
 17. Van derGaag RD, Drexhage HA, Dussault JH. Role of maternal immunoglobulins blocking TSH-induced thyroid growth in sporadic forms of congenital hypothyroidism. *The Lancet* 1985;325:246-250
 18. Williams JD, Scalafani AP, Slupchinskij O, Douge C. Evaluation and management of the lingual thyroid gland. *Ann Otol Rhinol Laryngol* 1996;105:312–316