



ORIGINAL ARTICLE

Surgical Outcomes of Haemorrhoidectomy along With Suture Haemorrhoidopexy in Multiple Haemorrhoids

Mohammad Ibrahim Khalil¹, Md. Ashiqur Rahman², Adnan Ahmed³, Samia Shihab Uddin⁴,
Mohammad Alauddin⁵, ABM Khurshid Alam⁶, AZM Mostaque Hossain⁷

¹Assistant Professor, Department of Surgery, Dhaka Medical College, Dhaka, Bangladesh; ²Indoor Medical Officer, Department of Surgery, Dhaka Medical College & Hospital, Dhaka, Bangladesh; ³Indoor Medical Officer, Department of Surgery, Dhaka Medical College & Hospital, Dhaka, Bangladesh; ⁴Honorary Medical Officer, Department of Surgery, Dhaka Medical College & Hospital, Dhaka, Bangladesh; ⁵Indoor Medical Officer, Department of Surgery, Dhaka Medical College & Hospital, Dhaka, Bangladesh; ⁶Professor, Department of Surgery, Dhaka Medical College, Dhaka, Bangladesh; ⁷Professor, Department of Surgery, Dhaka Medical College, Dhaka, Bangladesh

[Received on: 20 February 2019; Reviewed on: 12 March 2019; Accepted on: 11 May 2019; Published on: 1 July 2019]

Abstract

Background: Dealing multiple haemorrhoids at a time is challenging for surgeon in the fear of developing anal stenosis postoperatively. **Objectives:** The purpose of the present study was to evaluate the outcome of suture haemorrhoidopexy for secondary position haemorrhoids in addition to haemorrhoidectomy for primary haemorrhoids (multiple). **Methodology:** This prospective interventional study was performed in Dhaka Medical College Hospital and in a private hospital in Gazipur, Bangladesh for over five (05) years from January 2012 to December 2016. Patients who presented with multiple haemorrhoids were included in this study. Open haemorrhoidectomy followed by suture haemorrhoidopexy was done. All patients were followed up after 1, 2, 4, 8 weeks, 6 months and 1 yearly. **Result:** Total 18 patients were operated. Among those immediate complications were encountered in patients as per rectal bleeding 1(5.55%), pain 3(visual pain scale 4)16.66%, mucosal oedema 6(33.33%), no patient developed early postoperative prolapse. No patient developed bowel incontinence. Late complications experienced as prolapse at 1 year follow up which was treated by conservative measures. No patient developed anal stenosis. Mean operating time was 25 minutes and duration of hospital stay was 1 day. **Conclusion:** Open haemorrhoidectomy along with suture haemorrhoidopexy for multiple haemorrhoids is a safe and cost effective alternate surgical procedure instead of PPH stapler. [*Journal of Current and Advance Medical Research* 2019;6(2):73-76]

Keywords: Suture haemorrhoidopexy; Multiple haemorrhoids; Secondary position haemorrhoids

Correspondence: Dr. Mohammad Ibrahim Khalil, Assistant Professor, Department of Surgery, Dhaka Medical College, Dhaka, Bangladesh; Email: drshahin32@gmail.com; Cell no.: 8801710086817

Cite this article as: Khalil MI, Rahman MA, Ahmed A, Uddin SS, Alauddin M, Alam ABMK, Hossain AZMM. Surgical Outcomes of Haemorrhoidectomy along With Suture Haemorrhoidopexy in Multiple Haemorrhoids. *J Curr Adv Med Res* 2019;6(2):73-76

Funding: This study has been performed without any funding from outside else.

Conflict of Interest: There was no conflict of interest to any of the authors.

Contributions to authors: Khalil MI, Rahman MA, Ahmed A, Uddin SS involved in protocol preparation, data collection; statistical analysis Khalil MI; Alauddin M, Alam ABMK, Hossain AZMM had involved in manuscript writing & revision of the manuscript.

Copyright: ©2019. Khalil et al. Published by Journal of Current and Advance Medical Research. This article is published under the Creative Commons CC BY-NC License (<https://creativecommons.org/licenses/by-nc/4.0/>). This license permits use, distribution and reproduction in any medium, provided the original work is properly cited, and is not used for commercial purposes.

Introduction

Since centuries, a large number of treatment modalities for haemorrhoidal disease are known, but none is the ideal one. The ideal treatment was not possible without understanding the definite pathology and pathological anatomy¹. Different study was carried out though out the last 35 years to design a more optimum treatment procedure for haemorrhoid²⁻⁴. The interventional attitude⁵⁻⁸ may involve physical and chemical procedures (Mitchell's sclerotherapy, atomization, cryosurgery, infrared, laser or radiofrequency coagulation), supradentate devascularisation (Baron's rubber banding, Pakravan's en Z-haemorrhoidopexy, Morinaga's haemorrhoid arterial ligation, De Longo's stapling haemorrhoidopexy)⁹ or haemorrhoidectomies (segmental hemorrhoidectomy of Parks, Milligan-Morgan, Fergusson or their variants using the harmonic scalpel¹⁰ or LigaSure¹¹ or the radical White head Verescu's procedure⁵).

As the piles mass protrude out of anal canal the mucosal covering becomes fragile, which bleeds easily. The fixation of these loose prolapsing piles cushions has been understood to be the main principle of newer modalities of treatment of haemorrhoids such as stapler and Doppler Guided Haemorrhoid artery Ligation (DGHL). Longo's procedure depends on shortening of long prolapsing tissue and fixing of cushions to their original position by auto-suturing above the dentate line¹²⁻¹⁴. In 1995, Morinaga reported a new technique for the haemorrhoidal artery ligation (HAL), in which specially designed proctoscope attached with a Doppler transducer is used for identification and ligation of haemorrhoidal arteries. Because the arteries carrying the blood inflow are ligated, internal pressure of the plexus haemorrhoidal is decreased¹⁵.

All the existing procedures have a recurrence rate varying between 18 % and 60.0%¹⁶. The main etiological factor of development of recurrence of the haemorrhoids is development of the collaterals in all the present procedures in which ligation of vessels is done at one site¹⁶. In this study we tried to show the effects of sutured haemorrhoidopexy in terms of post-operative events and recurrence rates along with cost effectiveness.

Methodology

Study Settings and Population: This prospective interventional study was performed in Dhaka Medical College Hospital, Dhaka, Bangladesh and in

a private hospital in Gazipur, Bangladesh for over five (05) years from January 2012 to December 2016. Symptomatic patients of haemorrhoids positioning in primary position, as well as secondary positions were included in the study. All these patients were clinically examined and evaluated for surgery. Clinically evident patients with GI malignancy were excluded from the study. The permission from hospital ethical committee was taken and written informed consent was taken from the patients after explaining the surgical procedure and its possible outcomes.

Surgical Procedure: The bowel was prepared by oral liquids for 24 h; 500 ml of Osmosol was given orally 12 hourly before the operation. Fleet enema was introduced at 10 PM, the day before the surgery and at 7.00 AM on the day of surgery. Under the saddle block/spinal anaesthesia, patient was positioned in lithotomy with steep head low position, which helped in reducing piles mass. Cases and lax mucosal and submucosal tissues were replaced upwards to their original position. The anal canal was lubricated generously with lots of jelly and massaged. A proctoscope was used to compress and push the piles masses upwards, eventually lax mucosal and submucosal layers, containing vessels, were repositioned in anal canal. A self-retaining anal speculum was used. Traditional open haemorrhoidectomy done for primary haemorrhoids. Secondary haemorrhoids were treated by haemorrhoidopexy. 3/0 atraumatic polyglactin suture were used in a 30 mm ½ circle needle. At the base of the pedicle a stitch was passed through along with muscle layer. 2-3 subsequent bite were taken only in mucosa and submucosa, depending on the size of secondary haemorrhoid, then tied. Precaution was taken so that deeper structures don't get injured.

Results

The series included total of 18 patients comprising of 10 males patients and 8 females patients, the average age was 47.5 years; ranged between 22 and 76 years.

Table 1: Post-operative Complications (1st week)

Complications	Frequency	Percent
Bleeding	1	5.5
Mucosal oedema	6	33.3
Prolapse	0	0.0
Incontinence	0	0.0

In all the cases, frequent episodes of bleeding per rectum were noted. In some patients itching around

the anus was noted while some were suffering from discharge per rectum and spoiling under wears (Table 1).

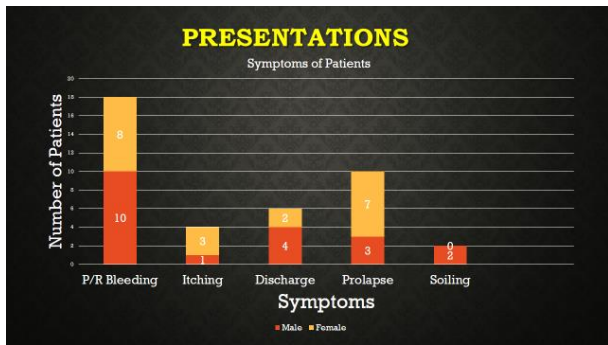


Figure I: Presentation of Patients

Sigmoidoscopy wasn't performed in all cases, but if there was a clinical suspicion of GI malignancy. Postoperatively, all the patients were discharged after 24 h, except for 2 cases. Postoperative minor bleeding was noted in 3 cases that required no treatment. The haemorrhoid masses were reduced 90.0% immediately postoperatively on the table, and further reduced in 3 to 7 days (Figure 3, 4 and 5).

Table 2: Post-operative complications (1st week)

Complications	Frequency	Percent
Bleeding	1	5.5
Mucosal oedema	6	33.3
Prolapse	0	0.0
Incontinence	0	0.0
Anal stenosis	0	0.0

The suture haemorrhoidopexy for haemorrhoids had minor oozing from some stitches in 11 % of cases during operation, which was controlled by compression. The small area of the mucosal tear noted in the early 3 cases required no treatment. Mucosal oedema present in 6(33.33%) cases, required no special treatment.

Table 3: Per Operative Events

Events	Frequency	Percent
Minor oozing	2	11.11
Mucosal tear	3	16.0
Reduction of pile mass		
Operating time		15 to 20

The patients were called for follow-up after 1, 3 and 6 months and later on yearly communicated over telephone for 2 years. At 1 year follow up in, haemorrhoid of grade I without bleeding were noted

in 1 patient. No stenosis was observed in the anal canal on per rectal and proctoscopy examination. No incidence of impairment of continence was noted. Postoperative pain was assessed by pain analogue score during hospital stay and all of them showed score ranging from 3 to 6 in pain analogue score. Total hospital cost in private hospital was 25000 BDT while the cost would be 50,000 BDT in stapled haemorrhoidopexy for same type of patient in same hospital setting. Mean operative time was 15 to 20 minutes.

Discussion

The Milligan- Morgan (MM) open haemorrhoidectomy is the most widely practiced surgical technique used for the management of haemorrhoids and is considered the current "gold Standard". Due to the high recurrence rate and potential complications, the use of stapler is decreasing day by day. Recurrence is a major issue associated with stapled haemorrhoidopexy. Cost of the stapler is also an issue of worth consideration. The systematic review by Laughlan et al and the meta-analysis by Giordano et al both showed that there is an increased risk of recurrence with Stapled haemorrhoidopexy compared with the Morgan-Milligan procedure, with odds ratios (ORs) ranging from 4.6 to 5.5 and incidence varying between 0 and 50%. The prolapse recurrence of 36%. The recurrence rate also depended on the degree of haemorrhoidal prolapse before the operation. This raises the question of how patients were selected and whether different techniques should be selected for some groups of patients.

According to a meta-analysis by Giordano et al stapled haemorrhoidopexy offers several short-term advantages, such as reduced blood loss and postoperative pain with a faster recovery time and shortened hospital stay. It also improves quality of life. The considerable increased risk of recurring haemorrhoidal prolapse should be weighed against these potential benefits and the patient should be involved in choosing the best treatment option.

Conclusion

Haemorrhoids is one of the most annoying diseases for the patients. But still an effective surgical procedure is an order of the day in the treatment of haemorrhoid because of post-operative adverse sequelae and cost of treatment. Suture haemorrhoidopexy can be a suitable alternative in the treatment of haemorrhoid, to be precise, with haemorrhoid in secondary positions especially in

developing countries like Bangladesh. In countries like Bangladesh where per capita income is low for most of the people, open haemorrhoidectomy along with suture haemorrhoidopexy for secondary position haemorrhoids is a safe and effective alternate surgical procedure instead of PPH stapler.

References

1. Parks AG. De haemorrhoids: a study in surgical history. *Guys Hosp Rep* 1955;104:135–156
2. Loder PB, Kamm MA, Nicholls RJ, Phillips RKS. Haemorrhoids: pathology, pathophysiology and aetiology. *Br J Surg* 1994;81:946–954
3. Thomson WHF. The nature of haemorrhoids. *Br J Surg* 1975;65:542–552
4. Haas PA, Fox TA, Haas GP. The pathogenesis of hemorrhoids. *Dis Colon Rectum* 1984;27:442–450
5. Mandache F. *Chirurgia rectului*. București: Ed. Med, 1971;451-72
6. Rădulescu D, Beluăică L. *Caiete de chirurgie practică*, vol. 2, ediția a 2-a. București: Ed. Med.; 1999;199-234
7. Chaudhry V, Abcarian H. Hemorrhoids. In: Cameron J, Cameron AM, editors. *Current Surgical Therapy*, 11th edition. Elsevier-Saunders; 2014:255-262
8. Rivadeneira DE, Steele SR, Ternent C, Chalasani S, Buie WD, Rafferty JL, et al. Practice parameters for the management of hemorrhoids. *Dis Colon Rectum* 2011;54(9):1059-64
9. Rahman ASMT, Rahman ASMZ, Biswas SK, Majumder KR, Biswas G. Stapled Haemorrhoidopexy Compared with Conventional Haemorrhoidectomy-A Systematic Review, *Faridpur Med Coll J* 2012;7(1): 37-41
10. Bilgin Y, Hot S, Barlas İS, Akan A, Eryavuz Y. Short – and long-term results of harmonic scalpel hemorrhoidectomy versus stapler hemorrhoidopexy in treatment of hemorrhoidal disease. *Asian J Surg* 2015;38(4):214
11. LigaSure hemorrhoidectomy versus stapled hemorrhoidopexy: a prospective, randomized clinical trial:mretraction. *Dis Colon Rectum* 2014;57(9):1151
12. Longo A. Stapled anopecty and stapled hemorrhoidectomy: two opposite concepts and procedures. *Dis Col Rect* 2002;45:571–572
13. Longo A. Treatment of hemorrhoids disease by reduction of mucosa and haemorrhoidal prolapse with a circular suturing device: a new procedure; in *Proceed. 6th World Congr Endoscop Surg*, Rome, 1998;June 3–6
14. Herold A, Kirsch J, Staude G, Hager T, Raulf F, Michel J. A German multi-centre study on circular stapled haemorrhoidectomy. *Colorectal Dis* 2000;2:18
15. Morinaga K, Hasuda K, Ikeda Y. A novel therapy for internal hemorrhoids: ligation of the haemorrhoidal artery with a newly devised instrument (Moricorn) in conjunction with a Doppler flowmeter. *Am J Gastroenterol* 1995;90:610–613
16. Chivate SD, Ladukar L, Ayyar M, Mahajan V, Kavathe S. Transanal suture rectopexy for haemorrhoids: Chivate’s painless cure for piles. *Indian Journal of Surgery*. 2012;74(5):412-7
17. Michalik M, Pawlak M, Bobowicz M, Witzling M. Long-term outcomes of stapled hemorrhoidopexy. *Videosurgery and Other Miniinvasive Techniques*. 2014;9(1):18
18. Laughlan K, Jayne DG, Jackson D, Rupprecht F, Ribaric G. Stapled haemorrhoidopexy compared to Milligan–Morgan and Ferguson haemorrhoidectomy: a systematic review. *International journal of colorectal disease*. 2009;24(3):335-44
19. Giordano P, Gravante G, Sorge R, Ovens L, Nastro P. Long-term outcomes of stapled hemorrhoidopexy vs conventional hemorrhoidectomy: a meta-analysis of randomized controlled trials. *Archives of surgery*. 2009 Mar 16;144(3):266-7