



**ORIGINAL ARTICLE**

**Surgical Outcomes of Temporary Ileostomy Patients attended at a Tertiary Care hospital in Dhaka City**

Muhammad Faridul Haque<sup>1</sup>, SM Syeed-Ul-Alam<sup>2</sup>, Ayesha Rahman<sup>3</sup>, Md. Mahfuzur Rahman Khan<sup>4</sup>, Muhammad Enamul Haque<sup>5</sup>

<sup>1</sup>Assistant Professor, Department of Surgery, Sylhet MAG Osmani Medical College, Sylhet, Bangladesh; <sup>2</sup>Junior Consultant, Department of Surgery, Shaheed Suhrawardy Medical College Hospital, Dhaka, Bangladesh; <sup>3</sup>Junior Consultant, Department of Surgery, Dhaka Medical College Hospital, Dhaka, Bangladesh; <sup>4</sup>Resident Surgeon, Shaheed Suhrawardy Medical College Hospital, Dhaka, Bangladesh; <sup>5</sup>Junior Consultant (Surgery), Upazila Health Complex, Sakhipur, Tangail, Bangladesh

[Received on: 1 November 2020; Accepted on: 20 December 2020; Published on: 1 January 2021]

**Abstract**

**Background:** Management of temporary ileostomy cases is very important considering the outcomes. **Objective:** The purpose of the present study was to observe the surgical complications of temporary ileostomy patients. **Methodology:** This prospective cohort study was conducted in the Department of Surgery at Sir Salimullah Medical College & Mitford Hospital, Dhaka, Bangladesh over a period of six months from July, 2011 to December, 2011. All patients who had undergone temporary ileostomy after admission were selected as the study population. Patients with temporary ileostomy at any age in both male and female were included in this study. The surgical complications like prolapse, retraction, stenosis, necrosis, skin excoriation, parastomal hernia, bleeding and wound infection were recorded. **Result:** A total number of 100 patients were selected for observation and management of complications of temporary ileostomy. Their ages ranging from 15 to 65 years with mean age 33.9±11.92 years. Complications were developed in majority cases of cases (52.0%). Several systemic complications were recorded like electrolytes imbalance (31%), hypoproteinaemia (14%), RTI (6%) and significant weight loss (4%). Skin excoriation was the more frequent local complication developed in 32 (32%) patients. However, 36 patients developed laparotomy wound related complication. **Conclusion:** In conclusion high frequency of complications are found among the temporary ileostomy patients. [*Journal of Current and Advance Medical Research, January 2021;8(1):65-69*]

**Keywords:** Surgical outcomes; complications; temporary ileostomy

**Correspondence:** Dr. Muhammad Faridul Haque, Assistant Professor, Department of Surgery, Sylhet MAG Osmani Medical College, Sylhet, Bangladesh; Email: [tutul28510@gmail.com](mailto:tutul28510@gmail.com); Cell no: +8801716342210

**Cite this article as:** Haque MF, Syeed-Ul-Alam SM, Rahman A, Khan MMR, Haque ME. Surgical Outcomes of Temporary Ileostomy Patients attended at a Tertiary Care hospital in Dhaka City. *J Curr Adv Med Res* 2021;8(1):65-69

**Funding:** This study has been performed without any funding from outside else.

**Conflict of Interest:** There was no conflict of interest to any of the authors of the study.

**Contributions to authors:** Data collection: Haque MF, Syeed-Ul-Alam SM, Rahman A; Data analysis: Haque MF; Manuscript writing: All authors are involved; Manuscript revised: Khan MMR, Haque ME

**Copyright:** ©2021. Haque et al. Published by Journal of Current and Advance Medical Research. This article is published under the Creative Commons CC BY-NC License (<https://creativecommons.org/licenses/by-nc/4.0/>). This license permits use, distribution and reproduction in any medium, provided the original work is properly cited, and is not used for commercial purposes.

## Introduction

The ileostomy is a surgically created opening in the small intestine (ileum) onto the anterior abdominal wall to divert intestinal contents<sup>1</sup>. Those consisting of a single intestinal lumen are termed end ileostomy, those giving access to an afferent and efferent limb may be loop or double barrelled ileostomy. Temporary ileostomy is performed for many different diseases and conditions<sup>2-5</sup>. Ileostomy is a lifesaving procedure in late moribund septic cases with fulminant enteritis and peritonitis and remains a necessary procedure mainly on a temporary basis<sup>6</sup>. Other indications for temporary ileostomy surgery are late case of acute intestinal obstruction, to protect low colorectal anastomosis and thereby reducing the serious complications of leakage, anastomosis leakage, blunt abdominal trauma, mesenteric vascular occlusion<sup>7</sup>.

An ileostomy has an adverse effect on the quality of life, which is further enhanced if stoma related complications occur. With conventional ileostomy, complications are reported in about 40.0% of patients in which 15.0% require operative correction, usually minor<sup>7</sup>. So it should be performed by an experienced surgeon who understands the potential metabolic and mechanical problems associated with ileostomy. Ileostomy related complications may be local and systemic. These may occur early or late, intermittently or progressively. Local complications are bleeding, stomal necrosis, skin excoriation, prolapse, retraction, stenosis, parastomal hernia, parastomal abscess and wound infection<sup>8</sup>. Systemic complications are electrolytes imbalance, malnutrition, hypoproteinaemia, weight loss or even death may occur<sup>4</sup>. Most of these complications can be prevented by adequate preoperative preparation and sound surgical technique and a better rehabilitation to prepare the patient psychologically<sup>9</sup>.

Construction of an ileostomy on temporary basis is common, frequently performed and lifesaving procedure though there is great advancement in the field of intestinal surgery<sup>10</sup>. A stoma should be formed by a surgeon who is not only technically skilled but also understands the potential metabolic and mechanical problems associated with an ileostomy or colostomy. But an ileostomy is most commonly constructed in emergency operation which is most likely done by the junior surgeons. So, ileostomy related complications are more frequent here<sup>1</sup>. The purpose of the present study was to observe the surgical complications of temporary ileostomy patients.

## Methodology

The study was designed as a prospective observational study. The study was conducted in the department of Surgery at Sir Salimullah Medical College & Mitford Hospital, Dhaka, Bangladesh. The study was conducted over a period of six months from July, 2011 to December, 2011. All patients who had undergone temporary ileostomy after admission in department of Surgery at Sir Salimullah Medical College & Mitford Hospital, Dhaka, Bangladesh from July 2011 to December 2011 were the study population. Purposive sampling method was used for this study. Patients with temporary ileostomy at any age in both male and female were included in this study. A temporary ileostomy was a surgically designed intestinal stoma for faecal diversion as a temporary measure and which would be closed after 2 to 3 months. The surgical complications like prolapse, retraction, stenosis, necrosis, skin excoriation, parastomal hernia, bleeding and wound infection were recorded. Face to face interview, clinical examination and some investigations were done to fill the semi-structured questionnaire which was well prepared in English but verbally translated to Bengali. According to inclusion and exclusion criteria, the patients were enrolled for the study. Various complications were noted during postoperative hospital stay and subsequently during follow up after one month, two months and during closure of stoma. All patients were also advised to come if any problem arises with ileostomy at any time. For these purposes all patients were assessed clinically by history and examination. Psychological complications were excluded from the study. The study was done after clearance of the ethical committee of the relevant Institute. All filled up questionnaire was checked for any inconsistency and after compilation of data. Statistical analysis was done by SPSS version 22.0. The quantitative data were expressed as mean with standard deviation. The qualitative data were expressed as frequency and percent.

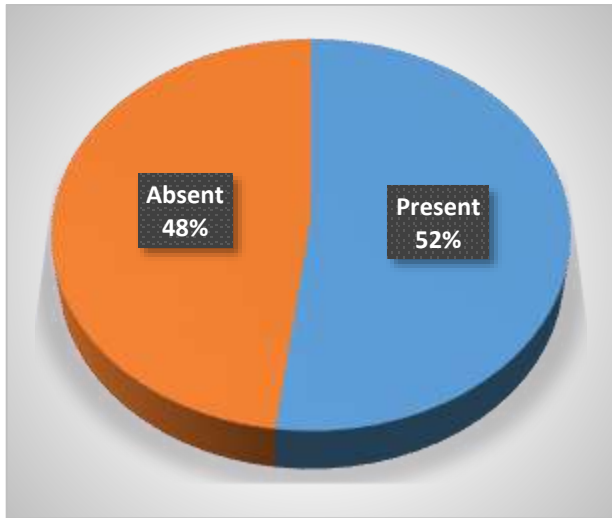
## Result

During the study period 100 patients selected for observation and management of complications of temporary ileostomy. Their ages ranging from 15 to 65 years with mean age 33.9±11.92 years (Table 1).

**Table 1: Patient Demography in the Studied Subjects**

Variables	Mean±SD	Range
Age in Years	33.9±11.92	15 to 65

Complications were developed in majority cases of cases. About 52.0% cases were developed complications and the rest of 48.0% cases were without complications (Figure 1).



**Figure 1: Frequency of Complication with Temporary Ileostomy**

Several systemic complications were recorded. Among these electrolytes imbalance was the more frequent systemic complication which was developed in 31(31%) patients. Other complications were hypoproteinaemia in 14(14%) patients, RTI in 6(6%) patients and significant weight loss in 4(4%) patients (Table 2).

**Table 2: Systemic Complications with Temporary Ileostomy**

Systemic Complications	Frequency	Percent
Electrolytes Imbalance	31	31.0
Hypoproteinaemia	14	14.0
RTI	6	6.0
Weight Loss	4	4.0

Skin excoriation was the more frequent local complication developed in 32 (32%) patients. However, 36 patients developed laparotomy wound related complication in which 28 (28%) patients develop only superficial wound infection and 08 (8%) patients develop wound dehiscence.

Other local complications were bleeding from stoma site (5.9%), prolapsed stoma (5.9%), retraction of stoma (3.9%), stenosis (2%), Necrosis of stoma (2%) and parastomal hernia (2%) (Table 3).

**Table 3: Local Complications with Temporary Ileostomy**

Local Complications	Frequency	Percent
Skin Excoriation	32	32.0
Superficial Wound Infection	28	28.0
Wound Dehiscence	8	8.0
Bleeding From Stoma	6	6.0
Prolapsed Stoma	6	6.0
Retraction Of Stoma	4	4.0
Stenosis	2	2.0
Necrosis Of Stoma	2	2.0
Parastomal Hernia	2	2.0

**Discussion**

Complication rate of ileostomy is variable due to age of the patients, urgency of surgery, diagnosis and time of presentation<sup>11-15</sup>. In this study the overall complication rate associated with temporary ileostomy was 52.0% cases which is fairly consistent with Rajput’s in which overall complication rate was 53.6% cases<sup>12</sup>. Overall complication rate was 42.94% according to Muneer’s which is also comparable with study<sup>5</sup>. Majority of these were treated conservatively with surgical intervention rate of 29.6% cases in which 50.0% cases due to closure of wound dehiscence. There are many factors suggested to predispose to stoma complications like high body mass index, use of steroids and immunosuppressive drugs, diabetes mellitus, old age, emergency surgery, surgical technique and surgeon’s experience<sup>15</sup>.

In present study, electrolytes imbalance was the most common systemic complication accounting about 31.0% patients. Other systemic complications were hypoproteinaemia in 14.0% of cases, RTI in 6.0% patients due to pre-existing pulmonary disease & smoking and significant weight loss in 4% of the cases due to hypercatabolic state. The average length of hospital stay in few patients was prolonged in this study due to concurrent medical problems that required prolonged hospital stay for adequate treatment and poor nutritional status prevailing in poor patients from rural areas that require proper nutritional built-up. Muneer’s showed comparatively lower rate of these systemic complication<sup>5</sup>. Pre-operative resuscitation with adequate fluids, correction of electrolytes imbalance and post-operative proper hydration should be maintained to reduce these complications.

Parastomal skin excoriation was the most common local complication accounting about 32% in this

present study which is consistent with Ahmad's in which about 39% patients with ileostomy developed local skin problems<sup>16</sup>. In another local study of Bhatti's shows that skin excoriation was the most common complication of temporary ileostomy accounting about 21.1% cases<sup>1</sup>. The probable cause may be improper location or construction of stoma and postoperative care or maintenance. It is difficult to maintain a good seal around the stoma. Previously, it is reported that this can be prevented using appliances consisting of flange or bag designed to fit closely and firmly the skin around the stoma, with the help of latex mixture, Karaya gum, stoma-adhesive or other pastes<sup>5</sup>.

Laparotomy wound infection including superficial wound infection and wound dehiscence comprises about 28.0% and 8.0% cases respectively in this present study. There are many factors suggested to predispose to wound infection like use of steroids and immunosuppressive drugs, diabetes mellitus, old age, emergency surgery, surgical technique and surgeon's experience<sup>15</sup>. According to Ahmad's laparotomy wound infection rate was 14.0% which is much lower than present study<sup>16</sup>.

Bleeding from stoma site was an early complication of temporary ileostomy. It was noted immediate post-operative period. In this present study, 6.0% of the cases presented with bleeding from stoma site in which two patients were managed by conservative treatment and two patient required ligation of the bleeding vessel under local anaesthesia. Its frequency was comparable to that reported in Safirullah's & Muneer's studies<sup>3,5</sup>.

Prolapse was the next common complication occurred in 6.0% cases which was similar to that of Safirullah's observation<sup>3</sup>. This can be managed by manual reduction and reformation of the stoma or revision by abdominal approach for incarcerated strangulated prolapse. In present study, four patients were managed by manual reduction till closure of the stoma and two patient required revision by abdominal approach for prolong stomal prolapse impending to gangrene.

In few studies, the link between higher body mass index and retraction is found. Two reasons i.e. a thickened fatty mesentery making mobilization more difficult and with a well-developed panniculus in obese patients traction is exerted on the bowel wall, which may be the main causes for retraction<sup>5</sup>. According to Bhatti's observation, retraction rate was 3.9% but in this study, retraction rate is 4.0% which is similar to some earlier studies<sup>1,6</sup>.

In this present study stenosis occurred in 2.0% of the cases in late post-operative period which is comparatively lower than that of Bhatti's observation which is 4% cases<sup>1</sup>. The causes of stenosis are small opening in abdominal wall during surgery, repeated friction of stoma against the stoma appliances causing fibrosis or apical stenosis. In this study, this was treated conservatively with gentle dilatation, stool softener, use of proper size appliances and their proper application.

Necrosis of the stoma spout was noted in 2.0% cases in present study which is comparable with that of Safirullah's study<sup>3</sup>. It occurs most frequently in obese patients and often in emergency procedures. The normal stoma in the immediate postoperative period is plum colored and shiny. With ischemia / gangrene it appears dusky and loses its shine and become black colored. In newly constructed stoma the use of transparent pouch is highly valuable in early detection of ischemia. The cause is excessive traction on mesentery of the loop and damage to the blood supply during surgery. Treatment is revision of the stoma as early as possible.

Another complication in the form of parastomal hernia occurring at the site of an intestinal stoma on the abdominal wall is also seen. The usual causes are, too large opening in the abdominal wall and stoma site lateral to the rectus muscle. This is diagnosed by digital examination of the stoma. True parastomal hernia has a peritoneal sac with enlarged fascial defect while pseudo hernia is the diffuse bulge without fascial defect, about 90% are true hernias. Parastomal hernia in this present study was only 2%, which is low as compared with other published series of Muneer (4%)<sup>5</sup>.

The present study had the following limitations. These should be kept in mind while deciding on the implications of the findings of the study. The sample size was relatively small. Most of the patients were illiterate and poor, so adequate diet and regular use of stoma appliances after buying it might not be satisfactory as expected.

## Conclusion

In conclusion high frequency of complications are found among the temporary ileostomy patients. Several systemic complications like electrolytes imbalance, hypoproteinaemia, RTI and significant weight loss are found. However, skin excoriation is the most frequent local complication followed by superficial wound infection, wound dehiscence, bleeding from stoma site, prolapsed stoma, retraction

of stoma, stenosis, Necrosis of stoma and parastomal hernia. Further large scale study should be carried out to get the real scenario.

## References

- Bhatti Y, Baloch I, Shabir SG, Rajib AD, Naz S. Frequency of complication of ileostomy: experience of 180 cases at Chandka Medical College Hospital Larkana. *Rawal Med J* 2010;35:127-135
- Kilic E, Taycan O, Belli AK, Ozmen M. The Effect of Permanent Ostomy on Body Image, Self-Esteem, Marital Adjustment and sexual Functioning. *Turk Psikiyatri Dergisi* 2007;18(4):73-80
- Safirullah, Mumtaz N, Asad UJ, Ahmad S. Complications Of Intestinal Stomas. *JPMI* 2005;19(4):407-411
- Doughty DB. History of Ostomy Surgery. 2008; 35(1): 34-38
- Muneer A, Razaque SA, Shaikh GA, Qureshi GA. Various Complications in Ileostomy Construction. *World ApplSci J* 2007; 2(3):190-193
- Asad AS, Memon M, Ahuja P, Soomro AG, Tahir SM, Shaikh NA. A Prospective Audit of Post-Operative Complications Of Construction Of Loop Ileostomy. *Medical channel* 2010;16(1):175-178
- Way LW, Doherty GM. Current surgical diagnosis and treatment. 12<sup>th</sup> edition. USA: McGraw-Hill Companies; 2006: 732-35
- Duchesne JC, Wang YZ, Weintraub SI, Boyle M, Hunt JP. Stoma complications: A multivariate analysis. *Am Surg* 2002;68:961-66
- Rajput A, Samad A, Khanzada TW. Temporary Loop Ileostomy: Prospective Study of Indications and Complications. *Rawal Med J* 2007;32:159-162
- Aziz A, Sheikh I, Jawaid M, Alam SN, Saleem M. Indications and Complications of Loop Ileostomy. *Journal of Surgery Pakistan* 2009;14(3):128-131
- Salts Healthcare: Stoma Surgery Complications. URL: <http://www.saltsstomacare.co.uk/information-for-ostomates/stoma-surgery-complications.aspx>
- Al-Fallouji MAR. Postgraduate Surgery, the Candidate's Guide. 2<sup>nd</sup> edition. England: Reed Educational and Professional 1998: Publishing Ltd; 289-91
- Shellito P C. Complications of abdominal stoma surgery. *Dis Colon Rectum*. 1998;41:1562–1572
- Common Post-operative Complications [online]. 2009 Aug 18. Available from: URL: <http://www.patient.co.uk/doctor/Common-Post-Op-Complications-to-Look-Out-For.htm>
- Arumugam PJ, Bevan L, Macdonald L, Watkins AJ, Morgan AR, Beynon J, et al. A prospective audit of stomas – analysis of risk factors and complications and their management. *Colorectal Dis* 2003;5:49-52
- Ahmad QA, Saeed MK, Muneera MJ, Ahmed MS, Khalid K. Indications and Complications of Intestinal Stomas- A Tertiary Care Hospital Experience. *Biomedca* 2010;26:144-147
- Datta PK, Bakshi SD, Lal P. Surgery in the tropics. In: Williams NS, Bulstrode CJK, O'Connell PR. Bailey & Love's Short practice of surgery. 25<sup>th</sup> edition. London: Arnold; 2008: 68-69
- Pearl RK, Prasad ML, Orsay CP, Abcarian H, Tan AB, Melzl MT. Early local complications from intestinal stomas. *Arch Surg* 1985; 120(10):1145-1147