



ORIGINAL ARTICLE

Surgical Treatment of Neglected Elbow Dislocation by Posterior Approach

Md. Nazrul Islam¹, Md. Rabiul Islam², Tahmina Begum³, Md. Moshabbirul Islam⁴

¹Associate Professor, Department of Orthopedic Surgery, Ad-Din Sokhina Women's Medical College, Jashore, Bangladesh; ²Associate Professor, Department of Otolaryngology & Head-Neck Surgery, Mugda Medical College, Dhaka, Bangladesh; ³Assistant Professor, Department of Pathology, Mugda Medical College, Dhaka, Bangladesh; ⁴Post-Graduate Student (Orthopedic Surgery), National Institute of Traumatology & Orthopaedic Rehabilitation, Dhaka, Bangladesh

[Received on: 1 April 2022; Accepted on: 20 May 2022; Published on: 1 July 2022]

Abstract

Background: Neglected elbow dislocation often results in contracture and functional impairments. Surgical treatment is challenging because of the accompanying triceps retraction. **Objectives:** The purpose of the present study was to surgical outcomes of treating the neglected dislocations of elbow joint using the posterior approach. **Methodology:** This was a non-randomized clinical trial over a three years period from January 2017 to December 2019. All the patients who were presented with a neglected elbow dislocation which was older than 21 days were selected as study population. The average follow-up was 18 months with the range 12 to 24 months after surgical procedure. **Results:** A total number of 10 patients were treated with an average age of 24.6±10.52 years (range 14 to 48 years). The dislocations were 6.6±3.69 months old on average (range 2 to 12months). Average elbow flexion was 46.5±26.04(15°-90°) and the extension deficit was 14.5±19.58(0°-50°) before the surgery. A paratricentral approach was used in all patients. In 7 patients, the dislocation was reduced without triceps lengthening. In 3 patients, a V-Y plasty of the triceps muscle was required. The improvements in the overall range of motion were statistically significant. Average elbow flexion was 118±11.35 (100°-130°) and extension deficit was 20.5±15.17. Complications included one case of ulnar nerve paresis, which subsided within two months, and one case of superficial infection. **Conclusion:** In conclusion the functional improvement in neglected elbow dislocations is outstanding. [*Journal of Current and Advance Medical Research, July 2022;9(2): 63-68*]

Keywords: Surgical treatment; neglected elbow dislocation; posterior approach

Correspondence: Dr. Md. Nazrul Islam, Associate Professor, Department of Orthopedic Surgery, Ad-Din Sokhina Women's Medical College, Jashore, Bangladesh; **Cell no.:** +8801776513618; **Email:** nazrul.dr14@gmail.com; **ORCID:** <https://orcid.org/0009-0000-9342-6585>

Cite this article as: Islam MN, Islam MR, Begum T, Islam MM. Surgical Treatment of Neglected Elbow Dislocation by Posterior Approach. J Curr Adv Med Res 2022;9(2):63-68

Funding: This study has been performed without any funding from outside else.

Conflict of Interest: There was no conflict of interest to any of the authors.

Contributions to authors: All authors involved from protocol preparation up to manuscript writing & revision.

Copyright: ©2022. Islam et al. Published by Journal of Current and Advance Medical Research. This article is published under the Creative Commons CC BY-NC License (<https://creativecommons.org/licenses/by-nc/4.0/>). This license permits use, distribution and reproduction in any medium, provided the original work is properly cited, and is not used for commercial purposes.

Introduction

Elbow dislocation can be diagnosed easily with clinical examinations and direct radiograms¹. In multitrauma cases and cases with other pathologies of ipsilateral extremity can be overlooked². The treatment of neglected elbow dislocation is more complicated than acute cases. Most authors recommend open reduction for late treatment of elbow dislocation³⁻⁴.

Treatment of neglected elbow dislocation is difficult for the orthopaedic surgeons in developing countries with the limited resources and untrained manpower. In addition, a very little information has been written in the standard textbooks. Elbow joint mobility after operative treatment is variable and has been considered related to several factors including the age of the patient, the duration of the untreated dislocation, the method of open reduction with or without triceps lengthening, the collateral ligament reconstruction, and postoperative mobilization with or without hinge external fixation^{1,3,4,7}.

The treatment of elbow dislocation is a challenging problem. Historically, the results have been hampered by frequent stiffness, recurrent instability, and/or dysfunction related to violation of the extensor mechanism. Postoperative complications have led some surgeons to recommend against surgical procedures for older patients and patients who are more than 3 months out from initial injury¹. Neglected elbow dislocations are common in developing countries. The main reason for the delayed diagnosis is that patients initially seek treatment from bonesetters who immobilize the elbow in extension. This leads to retraction of the triceps muscle and collateral ligaments. The resulting non-functional elbow contracture makes the surgical procedure quite challenging¹⁻². If these dislocations require surgical treatment, the surgeon has many options to consider: surgical approach, need for triceps lengthening (plasty), stabilization of the elbow after reduction, and repair of collateral ligaments²⁻⁸. The goal of this work was to share our experience in treating these neglected dislocations using the posterior approach.

Methodology

Study Settings & Population: This was a consecutive, prospective study over a three years' period from January 2017 to December 2019. The study included all the patients who presented with a neglected elbow dislocation, isolated or not, which

was more than 21 days old and treated surgically in our hospital. Patients presenting with elbow ankylosis were excluded from this study.

Surgical Procedure: Patients were operated under regional or general anaesthesia. Patients were placed on an ordinary surgical table in lateral positions on the contralateral side; the injured arm rested on a pad and the forearm and hand were left to hang. A tourniquet cuff was placed proximally on the arm. We used posteromedial and posterolateral. In midline, paratricentral approach was done in all patients. The ulnar nerve was identified and isolated with an elastic band, and then a posterior capsulotomy was performed to access the joint surfaces. In all cases, the triceps had retracted. The collateral ligaments were retracted to various degrees in all patients. In all cases fibrosis existed in the Olecranon fossa; heterotopic ossifications were present in one patient. The joint surfaces were normal in 8 cases. The Olecranon was covered with fairly thick fibrous in one case. Arthrolysis was performed in all cases. Any fibrotic tissue, osteophytes and heterotopic ossifications were resected. Reduction was obtained with slow, gentle, progressive maneuvers to avoid sudden movements that could injure the cartilage. As the triceps and ligaments progressively released, reduction was possible in most cases. If the collateral ligaments were too retracted to perform the reduction, they were detached from their proximal insertion. If reduction was still not possible because of significant triceps muscle retraction, we then performed an inverted V-Y triceps plasty¹¹. The dislocation of seven patients, were reduced without triceps lengthening; other three patients a V-Y triceps plasty was required. Once the joint was reduced, condylo-radial k-wires or condylo-humeral k-wires or both together we were used to stabilize the elbow at 90° for an average of 23 days (range 19 to 30 days). After implanting a suction drain and closings the incisions, an above-elbow cast was set up with the elbow at 90° until the k-wires were removed. All the patients underwent the same functional rehabilitation protocol. this was done on an outpatient basis with active mobilization during the first two weeks and then a combination of active and passive work afterwards. The patients were evaluated with the Mayo Clinic Elbow Performance index¹⁰. X-rays were done to evaluate condylo-radius and olecranon-humers alignment; the joint cartilage was evaluated based on the Knirk and Jupiter classification for post-traumatic elbow arthritis¹².

Statistical Analysis: Results were analyzed with statistical software (SPSS, version 18); a paired T-

test and logistical and linear regression analyses using the Chi² test were also performed. The statistical test was considered significant if the p value was below 0.05.

Ethical Consideration: All procedures of the present study were carried out in accordance with the principles for human investigations (i.e., Helsinki Declaration) and also with the ethical guidelines of the Institutional research ethics. Formal ethics approval was granted by the local ethics committee. Participants in the study were informed about the procedure and purpose of the study and confidentiality of information provided. All participants consented willingly to be a part of the study during the data collection periods. All data were collected anonymously and were analyzed using the coding system.

Results

Among included 10 patients there were 7 men and 3 were women, with an average age of 24.6±10.52

years (range 14 to 48). The dislocations were 6.6±3.69 months old on average (range 2 to 12 months). All the patients were right-handed and the dominant arm was affected in 40% of cases. They had various occupations like five in manual work (builder, mechani, fishermen, and farmer), 3 cases students and 2 cases housewives. The dislocations occurred because of RTA in 4 cases, during sports in 3 cases, during work in 3 cases. All the patients sought treatment because of limited elbow mobility. Anatomically, all the patients presented with a posterior dislocation: two were purely posterior, three were posteromedial and five were posterolateral. In 7 cases, only the dislocation was present others present with fractures. None of the patients could flex their elbow beyond 90°. The average elbow flexion was 46.5±26.04 (15°-90°). The average extension deficit was 14.5±19.58 (range 0°-50°) and the average range of motion was 32±25.52 (0°-90°) before the surgery. All the patients had difficulty performing activities of daily living and had an average Mayo clinic elbow performance index (10) score of 57 (range 26 to 78).

Table 1: Preoperative and Postoperative Results for Every Patient

Patient (case no)	Age (yrs)	Sex	Side	Delay (mon)	Preoperative mobility(deg.)			Postoperative mobility(deg.)			Surgical procedure	Score
					E1	F1	A1	E2	F2	A2		
1	30	M	L	8	0	30	30	15	110	95	T plasty	95 Ex
2	21	F	R	4	15	60	45	25	120	95		95 Ex
3	18	M	R	6	0	15	15	0	120	120	T plasty	100Ex
4	35	M	L	10	45	80	35	10	120	110		95 Ex
5	48	F	L	2	50	50	0	40	130	90		85 good
6	16	M	R	3	0	90	90	25	120	95		95 Ex
7	18	M	L	12	10	20	10	50	100	50	T plasty	70 Av.
8	26	M	L	10	15	40	25	10	130	120		100Ex
9	14	F	L	9	10	60	50	20	100	80		85 good
10	20	M	R	2	0	20	20	10	130	120		100 Ex
Mean	24.6			6.6	14.5	46.5	32	20.5	118	97.5		92
Min.	14			2	0	15	0	50	100	50		
Max.	48			12	50	90	90	15.17	130	120		
SD	10.5			3.69	19.58	26.04	25.52		11.3	21.9		

There were a few complications; ulnar nerve paresis in one case, which resolved after two months; one case of superficial infection in a patient who had a triceps plasty. The infection was resolved by revising the surgical wound and using appropriate antibiotics. The average follow-up was 18 months, with a minimum of 12 months and maximum 24 months (Table 1). In terms of function, the average

Mayo clinic elbow performance index was 92(range 70-100) with 7 excellent,2 good,1 average and none poor results. Slight pain during sustained, repetitive work was found in 2 patients, 1 of whom had a triceps plasty. For these two patients there was one good and one average result. None of the other patients had pain. Average flexion was 118±11.35(100° to 130°) and the average extension deficit was 20.5±15.17(0° to 50°).

The average range of motion was 97.5 ± 21.89 (range 50° to 120°). Flexion was greater or equal to 100 in nine cases. None of the patients complained of instability when performing activities of daily living. Clinical examination did not find any instability. All of the patients had return to their previous occupation. Only two patients were not satisfied with the results; among them, one had 90° of flexion. Analysis of X-rays showed that the dislocation had been reduced in all cases; the humeroulnar and humeroradial joints were aligned correctly (Figure III). According to Knirk Jupiter classification¹², 8 patients were at grade 0, 1 patient at grade 1 and another one patient at grade 2. There were no correlations between the age of the dislocation and the improvement in the range of motion. There was a statistically significant improvement in flexion of 71.5 and overall range of motion of 65.5 . An average of 6 was lost in extension. There was a statistically significant relationship between the degree of preoperative flexion and the need for a triceps plasty.

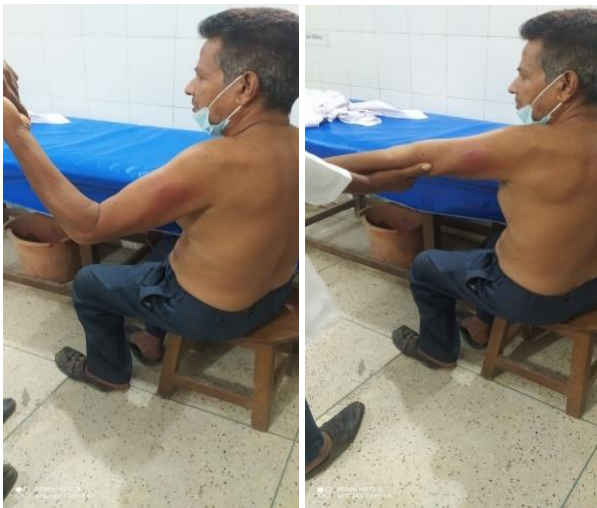

Figure I: Clinical appearance of flexion and extension of elbow of the patient after 24 months of surgery

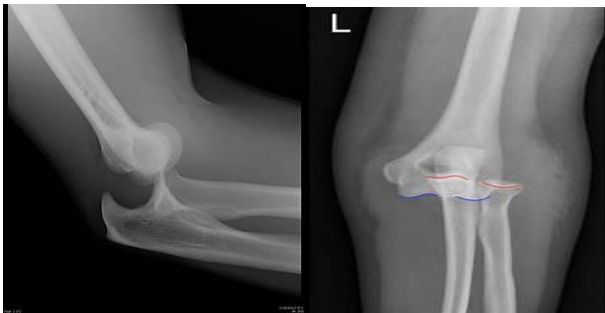


Figure II: Both view x-rays of a patient with posterior dislocation of left elbow

Discussion

Neglected elbow dislocations are common in developing countries. Patients first consult with bonesetters, who use massage, forceful manipulations and immobilization in extension to address the problem. This approach not only delayed the diagnosis and treatment, but also leads to complications¹³. For a long time, surgery was not advocated¹⁴⁻¹⁶. But after multiple published series describing good results from open reduction, surgical treatment is now back in favour^{2-8,11,17-19}.

Surgery is indicated based on how the patient tolerates the associated elbow stiffness^{1,8,17,20} and on the age of the dislocation. Martini et al¹ suggested that the elbow flexion of $80-90^{\circ}$ corresponds to functional stiffness. In these cases, surgery should not be performed. In cases where a maximum of 80° of flexion can be achieved, despite using the shoulder and hand to compensate, the stiffness makes the arm non-functional. Most authors advocate only operating on the latter group of patients^{1-2,4-5,7-8,17-18,20-21}. If the dislocation is less than six months old, the surgery is easier since the tissues (triceps and ligaments) are minimally retracted²¹. When the dislocation is older more than six months' indication for Surgery are not as straight-forward¹.

Based on our experience, if the dislocation results in the patient having less than 90° of elbow flexion, it should be surgically reduced. Even patients with 90° of elbow flexion are not able to bring their hand to the mouth, which is a particular concern in our region because food is eaten by hand with the right arm only. Patients with a dislocation that was older than six months had good and excellent results in 80% of cases. In the other 20.0% of cases, half of these patients had abnormal joint surfaces. The posterior and lateral approaches are used most often in open reduction^{3-4,7,17-19}. As with many others, we prefer to use the posterior approach instead of the combined lateral and medial approaches^{2-4,7,8,11,13,17-19,21}.

The posterior approach provides good exposure to the posterior structures that are typically retracted; it is also easy to perform a V-Y triceps plasty and an ulnar nerve transposition, when needed. The joint is reduced and fixed under direct visual control⁷. The overall aesthetics are also preferable, since there is only one surgical scar. In our series We used V-Y triceps plasty for retracted triceps described by Speed¹¹ most commonly used^{2-4,7,8,17,18}.

Although the V-Y triceps plasty is simple and reduction is easy to perform, this procedure has its disadvantages^{2,21}. It leads to more pain after surgery, an extension deficit^{4,18,21} and less available strength for manual work. There was a statistically significant relationship between the degree of preoperative flexion and the need for a triceps plasty (p).

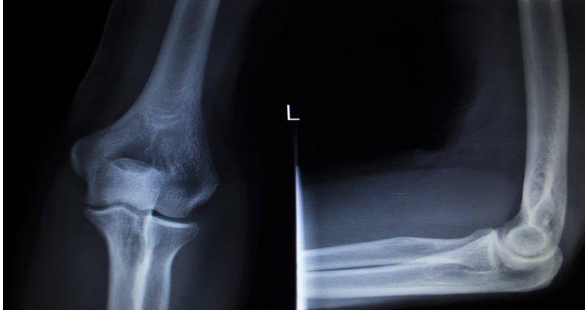

Figure III: Both view x-ray of elbow of the patient after 24 months of surgery

Surgery for neglected dislocations is typically conservative^{1,3-8, 17,18,21}. When the joint surfaces are

significantly damaged, or if open reduction fails, distal humerus resection^{20, 22} is an alternative to joint fusion, as the latter would greatly reduce the mobility of the joint. We and others believe that greatly retracted collateral ligaments do not need to be repaired to restore elbow stability^{3-5,7,17,18,21}.

We compared our functional results to published results where the same surgical technique was used (Table 2). We decided to only compare the functional results because the Mayo Clinic Elbow Performance index is not well-suited to neglected dislocations. In this scoring system, the lack of pain or the presence of moderate pain is heavily weighted 45 points^{5,8}. These present study results are comparable to those of Fowles et al⁴, Naidoo¹⁸, Mahaisavariya and Laupattarakasen⁷ who reported an average flexion greater than 110° in their series. Other than Mehta et al¹⁷ we had a smaller average extension deficit in our series (20.5°) which can be attributed to our lower rate of triceps plasty. The main complication in our series was ulnar nerve paresis, which resolved in two months after the surgery.

Table 2: Compared functional results

Authors	Essi et al ⁸	Fowles et al ⁴	Naidoo ¹⁸	Mahaisavariya and Laupattarakasen ⁷	Mehta et al ¹⁷	Current series
Extension deficit	94.5°	55°	40.4°	40°	13°	20.5°
Flexion	53°	112°	116°	122°	115°	118°
Range of motion	41.5°	67°	75.8°	82°	102°	97.5°

Conclusion

Neglected dislocations are a reality in our country. Despite challenging surgical treatment, the functional improvement and restoration of function is dramatic. A midline paratricapital posterior approach has many advantages and reduction can be achieved in most cases, without needing to use the triceps splitting approach. The reduced joint is stable even without repairing the collateral ligaments; fixation is needed for two or three weeks; if available, an external fixation can be used instead to provide early mobilization. This surgery is usually conservative; resection arthroplasty is limited to cases with significant joint destruction and failure of elbow reduction with resulting stiffness that makes the arm non-functional.

References

- Martini M, Benselama R, Daoud A. Les luxations négligées du coude—25 repositions sanglantes. *Revue de chirurgie orthopédique et réparatrice de l'appareil moteur*. 1984;70(4):305-12
- Arafiles RP. Neglected posterior dislocation of the elbow. A reconstruction operation. *The Journal of Bone and Joint Surgery*. British volume. 1987;69(2):199-202
- Billett DM. Unreduced posterior dislocation of the elbow. *Journal of Trauma and Acute Care Surgery*. 1979;19(3):186-8
- Fowles JV, Kassab MT, Douik MO. Untreated posterior dislocation of the elbow in children. *JBJS*. 1984;66(6):921-6
- Jupiter JB, Ring D. Treatment of unreduced elbow dislocations with hinged external fixation. *JBJS*. 2002;84(9):1630-5
- Krishnamoorthy S, Bose K, Wong KP. Treatment of old unreduced dislocation of the elbow. *Injury*. 1976;8(1):39-42
- Mahaisavariya B, Laupattarakasen W. Neglected dislocation of the elbow. *Clinical Orthopaedics and Related Research (1976-2007)*. 2005;431:21-5
- Essi FA, Najeb Y, Latifi M. La voie d'abord postérieure transtricipitale dans les luxations invétérées du coude. *Chirurgie de la main*. 2010;29(5):321-5

9. Hastings II H, Graham TJ. The classification and treatment of heterotopic ossification about the elbow and forearm. *Hand clinics*. 1994;10(3):417-37
10. Morrey BF, Adams RA. Semiconstrained arthroplasty for the treatment of rheumatoid arthritis of the elbow. *JBJS*. 1992;74(4):479-90
11. Speed JS. An operation for unreduced posterior dislocation of the elbow. *South Med J*. 1925;18(3):193-7
12. Knirk JL, Jupiter JB. Intra-articular fractures of the distal end of the radius in young adults. *JBJS*. 1986;68(5):647-59
13. Fourrier P, JP L, JP C. Incarceration Du Nerf Median Au Cours D'une Luxation Du Coude. *Chir Main* 2009;28(3):171-4
14. Silva JF. Old Dislocations of the Elbow: Hunterian Lecture delivered at the Royal College of Surgeons of England on 26th September 1957. *Annals of the Royal College of Surgeons of England*. 1958;22(6):363
15. Wilson JN. Fractures and joint injuries. 5th ed. Edinburgh Churchill Livingstone: Watson-Jones, 1976, p.434
16. Wright PE. Dislocations. In: Edmonson AS, Crenshaw AH, editors. *Campbell's operative orthopaedics*. 6th ed. St-Louis, Toronton and London: CV Mosby company;1980. p.459
17. Mehta S, Sud A, Tiwari A, Kapoor SK. Open reduction for late-presenting posterior dislocation of the elbow. *J Orthop Surg* 2007;15(1):15-21
18. Naidoo KS. Unreduced posterior dislocations of the elbow. *J Bone Joint Surg Br* 1982;64(5):603-6
19. Vangorder GW. Surgical approach in old posterior dislocation of the elbow. *J Bone Joint Surg Am* 1932; 14:127-43
20. Di Schino M, Breda Y, Grimaldi FM, Lorthioir JM, Merrien Y. Traitement chirurgical des luxations negligees du coude: a propos de 81 observations. *Rev Chir Orthop* 1990; 76:303-10
21. Mahaisavariya B, Laupattarakasen L, Supachutikul A, Taesiri H, Sujaritbudhungkoon S. Late reduction of dislocated elbow need triceps be lengthened? *J Bone Joint Surg Br* 1993;75:426-8
22. Shahriaree H, Sajadi K, Silver CM, Sheikholeslamzadeh S. Excisional arthroplasty of the elbow. *J Bone Joint Surg Am* 1979; 61:922-7