

## CENTRAL NERVOUS SYSTEM TUBERCULOMA IN A PREGNANT WOMEN : A CASE REPORT

Fahmida Shirin<sup>1\*</sup> Zubaida Khanam<sup>2</sup> Fahmida Islam<sup>3</sup> Md Salahuddin<sup>4</sup> Md Rabiul Karim<sup>5</sup>

### Summary

*Tuberculosis is still endemic in developing countries and over the past decades resurgence of this disease has been a major health threat mainly due to increasing frequencies of immunosuppressive states and drug resistance organism. Though it is a lung disease ,intracranial elements become involved in 5-10% of cases either as meningitis or tumour like masses i.e. tuberculoma. Its occurrence during pregnancy is occasional and its clinical picture mimicking toxemia of pregnancy and brain tumor. In addition, the effects of pregnancy on tuberculosis or vice versa have been controversial. We present here a case of a 25 years old lady who presented with severe frontal headache and neck pain associated with vomiting at her 12 weeks of pregnancy. At 20 weeks of pregnancy MRI was done which revealed an extramedullary placed SOL in right fronto temporal region. Craniotomy and excision done and histopathology report was compatible with tuberculosis. Anti TB drug therapy was started at her 26 weeks of pregnancy. Tuberculoma should be considered in differential diagnosis of eclampsia and brain mass particularly in women coming from endemic areas for this infection even in the absence of pulmonary involvement.*

### Key words

Central Nervous System; Tuberculoma; Pregnancy.

### Introduction

Tuberculosis is an infectious disease caused by Mycobacterium tuberculosis, which has high morbidity and mortality and represents a public

health problem, specially in developing countries. Its most common presentation is the pulmonary form. Infection of the central nervous system with tuberculosis may manifest as meningitis, abscess or tuberculoma [1]. Central Nervous System Tuberculomas (CNST) either multiple or single, usually presents as a diagnostic challenge because it has a similar appearance to many other non infectious and infectious conditions, specially in patients without constitutional symptoms or evidence of tuberculosis elsewhere in the body [2]. About one third of world population (Estimated to be about 1.75 billion) is infected with the Tubercle bacillus. As much as 75% of individuals with TB are within the economically productive age group of 15 to 54 years. This significantly impairs socioeconomic development, thereby perpetuating the poverty cycle [3]. Mycobacterium Tuberculosis (MT) infects about 2 billion people world wide and & 1 in 10 people infected with MT will have active tuberculosis in their lifetime. There were 9.2 millions new TB cases in 2006 & the total number of cases is still rising [4].

According to the revised estimates by WHO, the incidence & prevalence of all forms of tuberculosis in Bangladesh in 2014 were 227 & 404 per 100,000 people respectively. It is further estimated that about 51 per 100,000 people died of TB in the same year. The incidence of Tuberculosis in pregnancy ranges between 1-2% amongst the hospital deliveries in the tropics, being confined predominantly to the underprivileged sectors of society [5]. Tuberculosis is a common & deadliest disease in India (Accounting for 24% of total burden) & other developing nations of which more than half the cases (56%) were in the South East Asia & Western Pacific Regions. However there is a slow decline seen each year as most deaths from TB are preventable [6]. Tuberculosis involvement of the central nervous system continues to represent a serious problem, particularly in developing countries. It is an uncommon entity specially in the immunocompetent adult. Tuberculomas are granulomas of tuberculous origin which behaves

1. Assistant Professor of Gynaecology & Obstetrics  
Chittagong Medical College, Chittagong.

2. Lecturer of Community Medicine  
Chittagong Medical College, Chittagong.

3. Junior Consultant of Gynaecology & Obstetrics  
Upazila Health Complex, Dohazari, Chittagong.

4. Registrar of Medicine  
Chittagong Medical College Hospital, Chittagong.

5. Assistant Professor of Neurosurgery  
Chittagong Medical College, Chittagong.

\*Correspondence: Dr. Fahmida Shirin  
E-mail: fahmidashirin15@gmail.com  
Cell: 01779414006

as space occupying lesion & comprise 5%-30% of all intracranial masses. Although potentially curable, tuberculomas often present a diagnostic puzzle, & the diagnosis may not be considered early in a patient's course. The clinical diagnosis of this condition is difficult in practice, & a delay in the diagnosis of this curable disease contributes to significant neurological sequelae [7].

Eighty percent of TB deaths in women occur during their childbearing years & pregnant women are not spared from TB effects. Many of these at-risk women will seek health care only when pregnant, thus providing an opportunity for diagnosis & treatment.

### Case Report

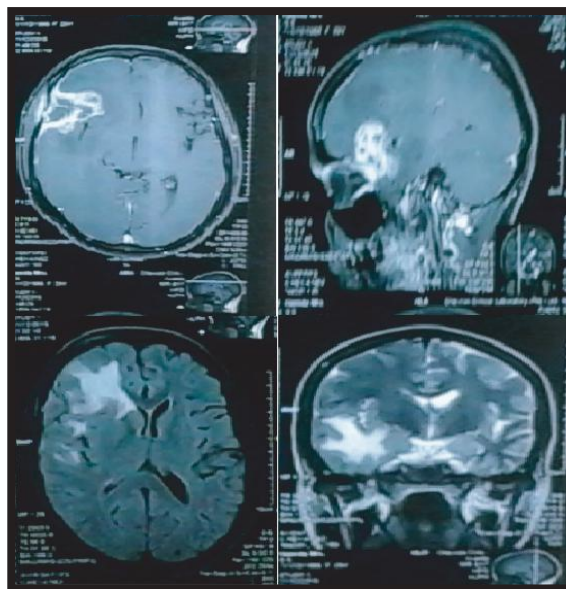
The patient was a 29 year old housewife of middle class urban dweller. She was 2<sup>nd</sup> gravida presented to a clinic at her 12 weeks of pregnancy with severe headache and low grade fever for last 4-5 months. Her headache was in right frontal region and throbbing in nature associated with vomiting. She was treated duely but her headache continued in an aggressive manner. She had no history of eye or limb problems or any infection. She had anorexia and weakness but no history of significant weight loss. She was non smoker, had not any medical problem, no history of TB or TB exposure, trauma or drug use.

On physical examination, she appeared pale, conscious, well oriented with raised temperature [100° F] and normal blood pressure and vital signs. She had no clinical sign of neurological deficit.

Laboratory tests showed mild anaemia [8.9gm/dl] raised ESR [104 mm/hour]. PPD skin test showed 02 mm induration after 72 hours. Serologic test for HIV [ELISA] was negative. MRI of brain disclosed an extradural peripheral enhancing lesion with central diffusion restricting component in the right basifrontal region.

After craniotomy and excision, final histopathologic diagnosis was extensive caseation necrosis with epitheloid granulomata compatible with tuberculosis. Anti TB drug therapy was initiated using CAT 1 [Isoniazide, Rifampicin, Pyrazinamide and Ethambutol along with vit B6. Unfortunately she developed drug induced hepatitis and was given another drug regimen [Isoniazide, Ethambutol and Vitamin B6].

Her pregnancy was monitored by USG and clinically and was uneventful up to term. Finally she delivered a healthy male baby per vaginally without any complication. After delivery chest X-ray was done and it was non significant. Patient is symptom free now and continuing her anti TB.



**Fig 1 :** MRI of Brain showing space occupying lesion in the right basifrontal region

### Discussion

The aim of this case report is to create awareness of cerebral tuberculoma, specially in patients who are pregnant & live in geographic areas where tuberculosis is endemic. Though preventable & curable, the disease still remains a major problem in developing countries.

Intracranial tuberculoma is an uncommon form of presentation of the infection by *Mycobacterium tuberculosis* in developed countries, but in developing countries they constitute 5-30% of all intracranial masses [4].

A definitive diagnosis could not be made using routine CSF tests & conventional MRI because similar findings are commonly found in other intracranial space occupying lesions [7].

It was reported that clinical manifestations of central nervous system tuberculoma usually present a period of week or months before diagnosis. Although it occurs at any age, 86% of the patients with CNST are under the age of 25 years in developing countries [8]. In pregnancy with cerebral tuberculoma symptoms are often

non-specific, such as, lethargy, alteration of bowel habit, vertigo or failure to gain weight appropriately- are interpreted as usual symptoms commonly occurring in pregnancy. And also up to 20% of pregnant women with tuberculosis remain asymptomatic [9].

In our case, the symptoms was excessive headache, which was not relieved by usual pain killer. She had weakness & low grade fever but no pulmonary symptoms. Her duration of symptoms was for 3-4 months before diagnosis. Usually clinical manifestations of intracranial tuberculoma present a period of weeks or months before diagnosis.

The variability in appearance of tuberculoma on MRI & CT, sometimes make them difficult to differentiate from neoplasms, pyogenic abscess & other granulomatous disease such as sarcoidosis [4]. Its diagnosis usually necessitates preferably a stereotactic brain biopsy followed by a histopathological examination [6]. PCR based tests may be much more helpful [4]. But neurologist should be aware of the limitations of "sensitivity & specificity" about MTB PCR tests [6].

Early diagnosis & treatment are essential as patient outcome depends on the clinical stage & on the age of the patient [7].

Eighty percent of TB deaths in women occur during their childbearing years. Many of these women will seek health care only when pregnant, thus providing an opportunity for diagnosis & treatment [10].

If the pregnant patient is adequately treated with antituberculous chemotherapy for active disease, tuberculosis generally has no deleterious effect, neither in pregnancy nor in puerperium or on fetus. So early diagnosis & prompt treatment in pregnancy are important in preventing mortality & reducing morbidity.

#### Conclusion

Cerebral tuberculoma should be suspected in patients with focal space-occupying lesion in brain who live in geographic areas where tuberculosis is endemic. Diagnosis is made by the combination of clinical presentation, imaging and response to treatment.

#### Disclosure

All the authors declared no competing interest.

#### References

1. Gasparetto EL, Tazoniero P, Neto A C. Disseminated Tuberculosis in a pregnant woman presenting with numerous Brain Tuberculomas. *Arq Neuropsiquiatr*. 2003 ; 61 (3-13) : 855-858.
2. Abuhamed M, Bo X, Yan C. Central Nervous system Tuberculoma : A Review Article. *American Journal of infectious disease*. 2008; 4(2) : 168-173.
3. Olabisi M. Loto & Ibraheem Awowole. Tuberculosis in Prenancy: A Review. *Journal of Pregnancy*. 2012;ID319271:7.
4. Ahmadi S A, Roozbeh H, Abbasi A, Bahadori M, Ketabchi S E et al. Cerebral Tuberculoma in Pregnancy : Overview of the literature and report of a case. *Acta Medica Iranica*. 2011;49(1):63-67.
5. Government of the People's republic of Bangladesh ,Ministry of Health and Family Welfare. *Health Bulletin* 2015.
6. Sharma P. Spectrum of Atypical Presentation of Tubercular infections of Central Nervous system : Case series and Review of Literature. *Journal of Tuberculosis Research*. 2015; 3: 90-96.
7. Guo N, Huang F, Chen X, Zheng M, Zhong D et al. Infratentorial Tuberculoma Mimics Tumour in immunocompetent Adults. An Analysis of 11 patients. *Open Journal of Modern Neurosurgery*, 2013;3:36-40.
8. Boluk A, Turk U, Aribas E. Intracranial Tuberculoma : Clinical and MRI finding. *Turget Ozal Tip Merkezi Dergisi*. 1998;5.
9. Lieulyn M, Coroply I, William RJ, Davidson R N. Tuberculosis diagnosed during pregnancy. A prospective study from London. Download from <http://thorax.bmj.com/> published by group. *bmj.com*. 2016;55:129-132.
10. Decherney A H, Nathan L, Laufer N, Roman A S. *Current Diagnosis & Treatment*. *Obstetrics & Gynaecology*. 2015;11:480-482.