

OUTCOME OF OPERATIVE TREATMENT OF DISPLACED MIDSHAFT CLAVICLE FRACTURE COMPARED WITH CONSERVATIVE TREATMENT

Chandan Kumar Das^{1*} Md. Iqbal Hossain¹ Abdur Rahman² Faisal Ahmed Siddiqui³

Background: Clavicles fracture accounts for 2.6%–5% of adult fractures. Fractures in the middle-third represent 69%–82% of all clavicle fractures. This prospective comparative study was done to evaluate the effectiveness of treatment options of conservative and operative method by plate for displaced midshaft of clavicle fractures in adult. **Materials and methods:** 76 patients between 18 to 70 years of age with a displaced midshaft fracture of clavicle were enrolled in this study. They were randomized in two groups to be treated with either triangular sling or operative fixation by anatomical plate. We analyzed the outcome of both groups by standard clinical and radiological follow-up at least one year with DASH score. **Results:** Mean age in conservative group was 52.2±13.2 years and 32.1±9.3 years in operative group. There was male predominance in both groups 71.7% (54). Mean time to radiographic union was 19.9±3.2 weeks in conservative group and 14.9±2.7 weeks in operative group. The total complications were 26.3% where 2.6% (01) nonunion in the operative group compared with 13.2% (05) in the conservative group. At one year of follow up, operative group were more likely to be satisfied with clinical and radiological outcome than conservative group by DASH score. **Conclusions:** Operative fixation of displaced mid shaft fracture of clavicle in adult showed improved functional outcome, faster return to daily activities and lower rate of complications compared with non-operative treatment.

1. Professor of Orthopaedic Surgery
Chattogram Medical College, Chattogram.

2. Registrar of Orthopaedic Surgery
Chattogram Medical College Hospital
Chattogram.

3. Classified Surgeon of Orthopaedic Surgery
Bangladesh Army Medical Core.

***Correspondence:** Dr. Chandan Kumar Das
E-mail: Chandan_ctgbd@yahoo.com
Cell : 01819 38 34 80

Submitted on : 29.06.2019

Accepted on : 22.07.2019

Key words

Mid shaft clavicle fracture; Plate and screw; DASH score; Anatomical plate.

Introduction

The clavicle is one of the most commonly fractured bones in children and adults specially those who participate in activities or sports where high speed falls or a direct blow to the shoulder are frequent. Fractures of the clavicle are common, accounting for 2.6% to 4% of adult fractures and 35% of injuries to the shoulder girdle¹⁻³. Displacement occurs in about 73% of all mid shaft clavicle fractures⁴. Among them 70% of the patients are male and the first and largest peak incidence is in males less than thirty years of age⁵.

Most shaft fractures are displaced, whereas the majority of lateral-end fractures are undisplaced. Despite the proximity of the brachial plexus and subclavian vessels, neurovascular injury is surprisingly rare, given the number of severely displaced clavicular shaft fractures seen in practice^{6,7}. The most common site of fracture is the middle third of the clavicle, representing approximately 80 % of all clavicle fractures⁸.

In 1960, Neer reported an astonishingly low rate of nonunion in conservatively treated middle-third clavicular fractures⁹. Recent studies, have emphasized the risk of nonunion or symptomatic malunion following conservative treatment. In 1997, Hill et al. reported a 15% nonunion rate in conservatively treated clavicular fractures and a relationship between shortening and the risk of nonunion¹⁰. In 2004, Nowak et al reported a 07% nonunion rate in conservatively treated clavicular fractures after six months as well as a risk of sequelae at the nine to ten-year follow-up. They also defined predictable risk factors, including lack of osseous contact at the fracture site, a transverse fracture and increased age that may cause complications in fracture-healing and overall recovery and considered indications for operative treatment¹¹.

The indications for surgery include open fracture, floating shoulder, patients with poly trauma, neurovascular deficit and the need for earlier functional mobilization in the patients. The available methods of conservative treatment are triangular sling, Figure of eight bandage while for operative treatment, the available of fixation with wire, Pins (Rush pins, TENS, Knowles pin, Rockwood pins) locking plate with screws and external fixators^{12,13}.

This prospective experimental study was designed to compare outcome and complications of conservative and operative treatment using anatomically precontoured locking plating in displaced mid shaft clavicular fractures.

Materials and methods

This prospective experimental study was conducted at Department of Orthopedic Surgery in Chattogram Medical College Hospital from June 2015 to December 2018. Ethical clearance was taken from the institutional committee. Purposive type of sampling technique was applied. Minimum follow up period was 01 (One) year with DASH score.

Inclusion criteria

- Age of 18 to 70 years
- Displaced fracture of the middle third of the clavicle
- Bilateral fracture of clavicle
- Fracture occurred less than two weeks.

Exclusion criteria

- Open fracture
- Pathological fracture
- Patients associated with head injury GCS less than 12 and poly trauma patient
- Pathological fracture other than osteoporosis
- Ipsilateral upper limb fractures and/or dislocation (Except of the hand and fingers)

Procedure

All patients are reviewed before surgery. Proper counseling was done about conservative and operative treatment and allowed the patients to choose the treatment option. According to their choice they are divided into Group A for conservative and Group B for operative Fixation. Conservative cases are managed with immediate triangular sling and discharged after proper assessment and preservation of radiological document and advised for follow up at schedule time.

For operative group general anesthesia given and then patients positioned on operation table as beach chair position with sand bag between shoulder blades. Fracture reduced and fixed with anatomical plate and screws. Triangular sling applied after dressing over affected extremity. Patient discharged from hospital on 2nd post operative day with triangular sling. Stitches removed after 12 days and physiotherapy started.

Post Operative Management

All patients taught exercises for shoulder movement after pain subsides. Weight bearing exercises deterred until 6 weeks follow up. Then after 6 weeks, gradual ROM (Range of Motion) exercises were encouraged. A routine check X-ray was done and patient condition assessed using DASH score recorded for future reference at 06 weeks, 12 weeks, 06 months and finally at 01 years.

Results

In this study over 3 years of duration we tried to find out the difference between conservative and operative treatment for midshaft fracture of clavicle in adult. In conservative group, mean age was 52.2±13.2years and 32.1 ±9.3 years in operative group where we found operative treatment were more preferred by young patients which was significant statistically (p= 0.025). Regarding gender in both group, male were predominant where 65.8% (25) and 76.3% (29) represented conservative and operative group respectively. For side determination both groups showed no significant difference which was shown in table I. There was significant difference (p=0.00012) in both groups regarding mean union time in weeks where operative group showed less time 19.9±3.2 weeks.

Regarding complications, 28(73.3%) in each group faced no complications. In conservative group, 05(13.2%) cases were end up with non-union and 01(2.6%) case in operative group where 04 cases treated operatively with bone graft and 02 case refused for operation. 04(10.5%) cases experienced shoulder stiffness in conservative group and 03(7.9%) cases in operative group which were treated by physiotherapy and end up with full function of shoulder 03 months later. 01(2.7%) patient had tenting of skin and advised for operative treatment but refused as his shoulder movements were full. In operative group, we faced 02(5.3%) cases with postoperative infection which was treated according to culture sensitivity

and regular dressing and subsequently healed up. Again in operative group, 03(7.9%) cases presented in follow up with implant failure and refracture due to separate RTA and were treated by reoperation with bone graft. 01(2.7%) case presented with ugly keloid scar and properly counseled.

Finally DASH score were assed at every follow up visit where operative group showed significantly higher statistically score. At 06 weeks of follow up, operative group showed 30.3 ± 3.7 than 45.4 ± 4.6 in conservative group ($p= 0.045$). Subsequently in 12 weeks and 06 months follow up period, operatively group showed statistically significant result where p value were 0.029 and 0.044 respectively. Final follow up at 01 year later, operative group showed 15.3 ± 2.9 than 28.2 ± 4.7 in conservative group ($p= 0.041$) which showed statistically significant difference between two groups.

Table I : Demographic and clinical outcome (n=76)

Criteria	Conservative (n=38)	Operative (n=38)	p value
Mean age (Years±SD)	52.2±13.2	32.1±9.3	0.025
Gender			
Male	65.8% (25)	76.3% (29)	
Female	34.2% (13)	23.7% (09)	0.318
Side			
Right	68.4%(26)	25.0%(19)	
Left	31.6%(12)	47.4%(18)	
Bilateral	0.0%(0)	2.6%(1)	0.193
Mechanism of injury			
Fall	50.0%(19)	31.6%(12)	
RTA	36.8%(14)	47.4%(18)	
Assault	13.2%(05)	21.1%(08)	0.250
Fracture type			
B1	57.9%(22)	55.3%(21)	
B2	42.1%(16)	44.7%(17)	0.820
Union of fracture			
Union	86.8%(33)	97.4%(37)	
Nonunion	13.2%(05)	2.6%(01)	0.200
Duration of union (Mean weeks±SD)	19.9±3.2	14.9±2.7	0.00012
Complications			
No complications	73.7%(28)	73.7%(28)	0.133
Non union	13.2%(05)	2.6%(01)	
Shoulder stiffness	10.5%(04)	7.9%(03)	
Tenting of skin	2.6%(01)	0.0%(0)	
Infection	0.0%(0)	5.3%(02)	
Implant failure with refracture	0.0%(0)	7.9%(03)	
Ugly scar	0.0%(0)	2.6%(01)	

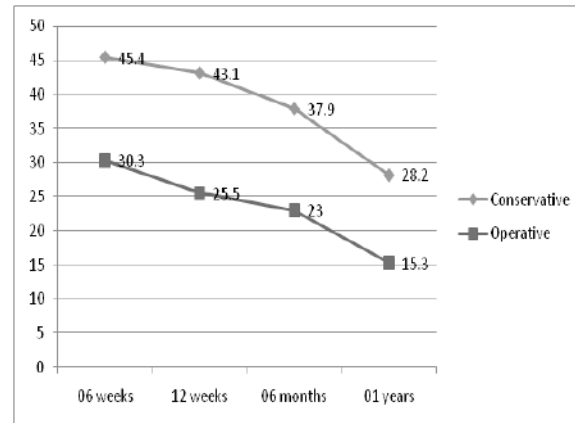


Fig 1 : DASH score of follow up

Case 1:

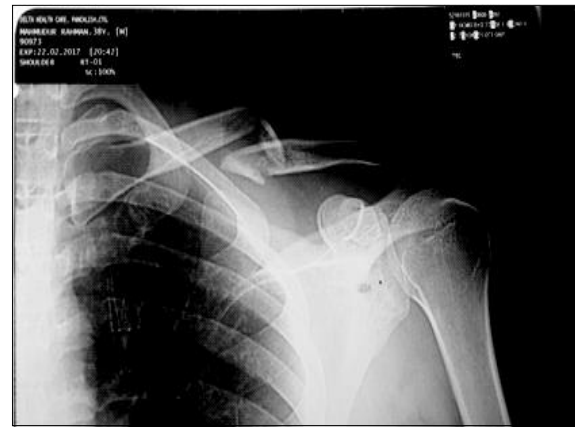

Fig 2 : Preoperative X-ray of 38-year-old male patient showing displaced midshaft clavicle fracture left side

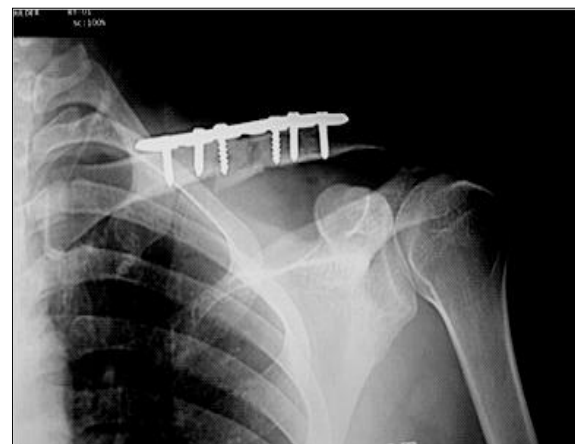

Fig 3 : Immediate postoperative X-ray showing plate osteosynthesis with anatomical precontoured 3.5-mm dynamic compression plate

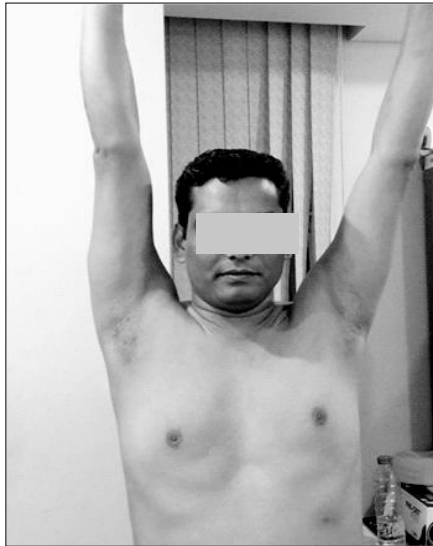

Fig 4 : Post-operative follow up 01 year later

Case 2: (Non union at follow up of 06 months later by conservative treatment)

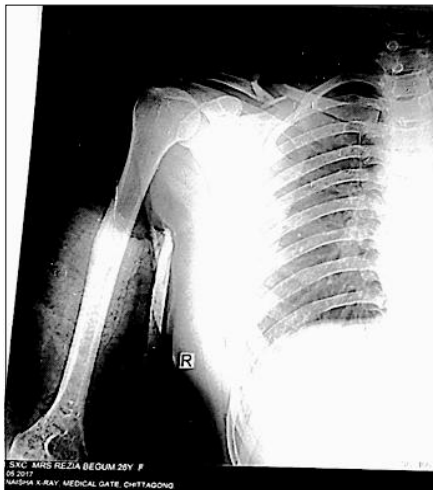

Fig 5 : Preoperative X-ray of 26 year old female patient showing displaced midshaft clavicle fracture right side

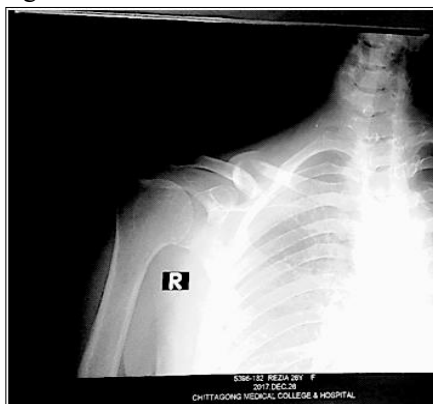

Fig 6 : Non united fracture of right clavicle at 06 months of follow up

Discussion

Traditionally, clavicle fractures have been treated non-operatively. In the 1960s, Neer and Rowe reported better results on non-operative treatment of clavicle fractures¹⁴⁻¹⁶. Although conservative method is mostly practicing method for clavicle in our country but more recent studies have shown that the non-union rate for displaced midshaft fractures of the clavicle are ranging from 10% to 15%. So in recent years, surgeons are preferred for operative treatment for displaced midshaft clavicle fracture in adult¹⁷⁻²⁰. For operative fixation, many methods were present. Biomechanically plate fixation is better than intramedullary nail because of better resists the bending and torsional forces that happened during overhead activity. So plate fixation is gold standard method for which we choose the procedure for this study.

Evaluation of the distribution of age and sex revealed operative interventions were more preferred in young and male predominance. Mean age in operative group was 32.1 ± 9.3 years than conservative group 52.2 ± 13.2 years ($p = 0.025$) which was significant as the young generation is more active and concerned about their outcome following fracture, older people preferred more for conservative management. In this study, the youngest patients were 18 years and oldest patient was 70 years. The average age was 42.2 years for both groups. In Bostman et al study, patients average age was 33.4 years and the youngest patient age was 19 years and oldest patient age was 62 years²¹.

If considering gender, male were more predominant in both groups 71.7% (54) as they were earning members of family. In Bostman et al series also, commonly, males were the most affected patients 73.8% (76) compared to females patients 26.2% (27)²¹.

Regarding mechanism of injury, total 40.8 % (31) on both groups were due to fall either directly or indirectly on outstretched hand. Incidences of outstretched hand occur as a simple fall in aged patients and sports in young patients. For RTA, 36.8% (14) patients were in conservative group than 47.4% (18) in operative group and for assault 13.2% (05) patients were in conservative group than 21.1% (08) in operative group. So, young patients were more victims of RTA and assault than aged patients in fall. In Bostman et al study, the mechanism of injury was due to fall from the two

wheeler in 38 patients (36.8%) slipping and fall in 24 patients (23.30%) motor vehicle accident in 19 patients (18.45%) and sports injury in 22 patients (21.36%).

Lazarus stated that radiological union occurred approximately between 6 and 12 weeks²². In this study, total 19.9±3.2 weeks required in conservative group and 14.9±2.7 weeks in operated group (p=0.00012).

When we considered complications, 7.9% (03) patients had implant failure with refracture, 7.9% (03) had shoulder stiffness, 5.3% (02) had postoperative infection and 2.6% (01) had ugly operative scar in operative group (p=0.133). In conservative group, 13.2% (05) had non-union, 10.5% (04) had shoulder stiffness and 2.6% (01) had tenting of skin which was accepted by the old patient. The total complication rate of Bostman et al study was 23% where it was 26.3% in our study. In Bostman et al study, 02 patients treated with semi-tubular plate had implant breakage at 2nd and 7th postoperative weeks respectively²¹. Both cases were treated by replating using dynamic compression plate with bone grafting.

Finally in this study, DASH score were statistically significant for operative group in all follow up (p= 0.041).

Limitation

The main weakness of the study were,

- Small sample size
- Shorter duration of follow up
- Uses of other implant for operative treatment

Conclusion

The study showed that early primary plate fixation of displaced midshaft clavicle fractures in adult has better results than conservative treatment which has less time of union, earlier returned to normal functions and decreased rates of nonunion.

Recommendations

Further study with larger sample size, long follow up period and using intra medullary versus extra-medullary fixation for displaced midshaft clavicular fracture in adult is required.

Acknowledgments

We would like to acknowledge those who have assisted us in the study all teachers of Institutional review board and Dept. of Orthopedic Surgery, Residents of Orthopedic Surgery, staffs of hospital and implants, respected Principle and Vice Principle sir. Finally we are grateful to all of our

patients who participate in the study and make this journey possible to improve our knowledge and help us and our future patients for better management. Lastly we are grateful to our family members for supporting us during the time period to continue our works and to God who make this possible in every step.

Contribution of authors

CKD-Conception, design, drafting and final approval.

MIH-Interpretation of data, critical revision, and final approval.

AR-Acquisition of data, drafting and final approval.

FAS-Analysis, interpretation of data, critical revision and final approval.

Disclosure

All the authors declared no competing interest.

References

1. Nordqvist A, Petersson CJ, Redlund-Johnell I. Mid-clavicle fractures in adults: End result study after conservative treatment. *J Orthop Trauma.* 1998;12:572-576.
2. Ven Denise JC, Timmers TK, Flikweert PE, Van Ijseldijk AL, Van Olden GD. Plate fixation versus conservative treatment of displaced midshaft clavicle fractures: Functional outcome and patients satisfaction during a mean follow-up of 05 years. *2015;46(11):2223-2229.*
3. Postacchini F, Gumina S, De Santis P, Albo F. Epidemiology of clavicle fractures. *J Shoulder Elbow Surg.* 2002;11:452-456.
4. Khan LA, Bradnock TJ, Scott C, Robinson CM. Fractures of the clavical, *J Bone Joint Surg Am.* 2009;91:447-460.
5. Parez EA. Fractures of the shoulder, Arm, and Forearm. In: Canale ST, Beaty JH, editor. *Campbell's operative orthopaedics.* 12th ed. St. Louis: Mosby Year Book. 2013;2829-2832.
6. Plate Fixation Compared with nonoperative Treatment for Displaced Midshaft Clavicular Fracture: A Multicenter Randomized Controlled Trial. Woltz S, Stegeman SA, Krijnen P, van Dijkman BA, van Thiel TP, Schep NW, de Rijcke PA, Frolke JP, Schipper IB. *2017; 99(2): 106-112.*
7. Zlowodzki M, Zelle BA, Cole PA et al. Treatment of acute midshaft clavicle fractures: Systematic review of 2144 fractures: On behalf of the Evidence-Based Orthopaedic Trauma Working Group. *J Orthop Trauma.* 2005;19(7):504-507.

8. Robinson CM, Goudie EB, Murray IR, Jenkins PJ, Ahkter MA, Read EO, Foster CJ, Clark K, Brooksbank AJJ, Arthur A, Crowther MA, Packhman I, Chesser TJ. *J Bone Joint Surg Am.* 2013;4;95(17);1576-1584.
9. Altamimi SA, Mckee MD. Nonoperative treatment compared with plate fixation of displaced midshaft clavicular fracures. *Surgical technique.J Bone Joint Surg Am.* 2008;90:1-8.
10. Hill JM, McGuire MH, Crosby LA. Closed treatment of displaced middle-third fractures of the clavicle gives poor results. *J Bone Joint Surg Br.* 1997;79(4):537-539.
11. Nowak J, Holgersson M, Larsson S. Can we predict long-term sequelae after fractures of the clavicle based on initial findings? A prospective study with nine toten years of follow-up. *J Shoulder Elbow Surg.* 2004;13:479-486.
12. Golish SR, Oliviero JA, Francke EI, Miller MD. A biomechanical study of plate versus intramedullary devices for midshaft clavicle fixation. *J Orthop Surg Res.* 2008; 16(3):28.
13. Nonoperative Treatment Compared with Plate Fixation of Displaced Midshaft Clavicular Fractures A Multicenter, Randomized Clinical Trial. *Jour of Canadian Orthopaedic Trauma Society.*2007; 12(2): 114-116.
14. Rowe CR. An atlas of anatomy and treatment of midclavicular fractures. *ClinOrthopRelat Res.* 1968;58:29-42.
15. Andersen K, Jensen PO, Lauritzen J. Treatment of clavicular fractures. Figure-of eight bandage versus a simple sling. *ActaOrthop Scand.* 1987;58(1):71-74.
16. Eskola A, VainionpaaS, Myllynen P, Patiala H, Rokkanen P. Outcome of clavicular fracture in 89 patients. *Arch Orthop Trauma Surg.* 1986;105(6): 337-338.
17. Huang JI, Toogood P, Chen MR et al. Clavicular anatomy and the applicability of precontoured plates. *J Bone Joint Surg Am.* 2007;89(10): 2260–2265.
18. Judd DB, Pallis MP, Smith E et al. Acute operative stabilization versus nonoperative management of clavicle fractures. *Am J Orthop.* 2009;38(7):341–345.
19. Rockwood and Green's fractures in adult, 8 th edition. 2015; 1(38):1427-1470.
20. Brinker MR, Edwards TB, O'Connor DP. Estimating the risk of nonunion following nonoperative treatment of a clavicular fracture [letter]. *J Bone Joint Surg Am.*2005;87:676-678.
21. Bostman O, Manninen M, Pihlajamaki H. Complications of plate fixation in fresh displaced mid clavicular fractures. *J Trauma.* 1997;43: 778–783.
22. Lazarus MD. Fractures of the clavicle. In: Bucholz RW, Heckman JD, eds. In: Rockwood and Green's Fractures in Adults 5th ed. Philadelphia: Lippincott Williams and Wilkins. 2001;26:1041-1078.