

## THE SHAPE OF THE HUMAN ADULT TRACHEA AMONG BANGLADESHI MALES

B M Ali Yousuf<sup>1</sup> K Begum<sup>2</sup> K M Shamim<sup>3</sup>

### Abstract

A total of 40 (forty) human specimens of adult trachea were used to study the cross-sectional shape of the trachea among Bangladeshi Bengali males of different ages ranging from 13 to 65 years, during 1996, in Anatomy Department of IPGMR (at present BSMMU), Dhaka. Four different varieties of cross-sectional shape of the tracheas were found : C – shaped, D – shaped, Elliptical and U – shaped; of them the most common was the C – shaped (45 %) and the least common was the U – shaped variety.

**Key Words:** trachea; cross-sectional shape; endotracheal; percentage; CT scan.

### Introduction

The size and shape of the trachea changes with change of intra-luminal pressure during respiration<sup>1</sup>. The cross-sectional shape of the adult trachea is variable<sup>2</sup> and has been classified by Mackenzie et al<sup>3</sup>. into six different types. Knowing the size and shape of the trachea has clinical implications. Endotracheal intubation and mechanical ventilation are indicated for the treatment of established pulmonary failure or prior to general anaesthesia<sup>4</sup>. The trachea is less than cylindrical<sup>5</sup> but the cuff of a freely inflated endotracheal tube is circular. To seal the airway this cuff must either conform to or deform the trachea<sup>6</sup>. A high compliance cuff should conform but damage to the trachea has been reported<sup>7</sup>. For proper endotracheal intubation the cross-sectional shape of trachea must be known. Because of anatomic differences there may be difficulty in endotracheal intubation<sup>8</sup>. In fact in some advanced medical centres the type of tracheal shape is conformed through CT scan prior to endotracheal intubation.

### Material and methods

40 (forty) human adult trachea were dissected at autopsy and specimens were collected from the Department of Forensic Medicine of Dhaka Medical

1. Professor of Anatomy  
Chittagong Medical College, Chittagong
2. Lecturer of Anatomy, Sir Salimullah Medical College, Dhaka
3. Professor of Anatomy  
Bangabandhu Sheikh Mujib Medical University, Dhaka

**Correspondence:** Dr B M Ali Yousuf

College and Cross- studied in Anatomy Department of IPGMR at present BSMMU, Dhaka.

Sections of the trachea should be taken between fourth and seventh cartilage rings at the point where the cuff of the tracheostomy or endotracheal tube would be expected to be positioned<sup>3</sup>. In the present study a cross-section of about 5 mm vertical thickness of the trachea was made at the level of the 5<sup>th</sup> cartilage ring to determine its shape. To prevent gravitational shape change these specimens were stored in individual 50 cc containers containing formol saline solution. The each specimen was classified regarding its shape considering the ratio of the transverse diameter to the antero-posterior diameter as well as the angle between the posterior membranous portion and the cartilage ring (following Mackenzie et al. 1978). The diameters were measured with Vernier calipers and the angles were measured with a protractor.

According to Mackenzie and colleagues six different tracheal shapes could be described as follows :

#### i) The C – shaped trachea

In this type the antero-posterior and transverse diameters would be equal and the cartilaginous portion would make obtuse angles with the membranous part.

#### ii) The U – shaped trachea

This type would have a larger antero-posterior than the transverse diameter, and the cartilaginous part would make obtuse or right angles with the membranous part.

#### iii) The D – shaped trachea

This type would have a smaller antero-posterior than the transverse diameter, and the cartilaginous part would make acute angles with the membranous part.

#### iv) The elliptical trachea

This type would have a smaller antero-posterior than the transverse diameter, and the cartilaginous part would make obtuse angles with the membranous part.

#### v) The triangular trachea

This type would have equal antero-posterior and transverse diameters, and the cartilaginous part would make acute angles with the membranous part.

**vi) The circular trachea**

This type would be almost complete ring of cartilage with a small, practically non-existent membranous part.

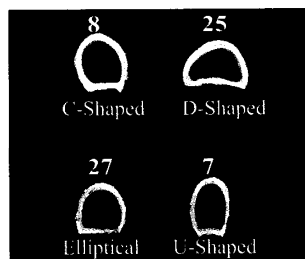
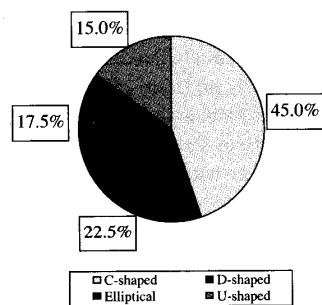
**Results**

As shown in Table-1 and Figure-1 & 2, no triangular or circular tracheal cross-sectional shape was found in the present study. Of the four different varieties found, the most common was the C- shaped (45 %) variety and the least common was the U - shaped (15 %) one. The general observation was that, the tracheal cross-sectional shape was not related with the age, height or neck circumference of the individual. However, no statistical analysis was done in these regards.

**Table 1 :** Shape of the tracheal cross-section at the level of the 5<sup>th</sup> cartilage ring (n = 40)

| Shape of the Tracheal cross-section | Frequency of cases | Percentage ( % ) |
|-------------------------------------|--------------------|------------------|
| C - shaped                          | 18                 | 45               |
| D - shaped                          | 9                  | 22.5             |
| Elliptical                          | 7                  | 17.5             |
| U - shaped                          | 6                  | 15               |
| Triangular                          | 0                  | 0                |
| Circular                            | 0                  | 0                |
| Total                               | 40                 | 100              |

**Fig 1 :** Pie diagram showing frequencies of different shapes of the tracheal cross-section



**Fig 2 :** Photographs of sections of the trachea representing different types of cross-sectional shapes.

**Discussion**

The specimens showed considerable variation in tracheal cross sectional shape. Four different shapes of tracheal cross-section were found. These were in order of frequency : C - shaped (45 %), D - shaped (22.5 %), Elliptical (17.5 %) and U - shaped (15 %). (Table 1 and Fig. 1 and 2).

Mackenzie et al. studied on 111 formalin-fixed trachea of American people and classified six different shapes of tracheal cross section : C- shaped (48.6 %), D-shaped (12.5 %), Elliptical (8.2 %), U-shaped (27 %), Triangular ( 1.6 %) and Circular (1.8 %). The authors also studied on 31 living patient through CT scan at the level of sterno-clavicular joint and found that there was no significant difference between the frequency of different shapes in anatomical and CT scan findings (X<sup>2</sup> test p > 0.05). They also found no evidence that these shapes were influenced by postmortem changes or formalin-induced shrinkage. Machenzie et al. finally considered CT scanning as the ideal method of identification of tracheal shape.

**References**

1. Griscom NT, Wohl ME. Tracheal size and shape: effects of change in intra- luminal pressure. *Radiology* 1983; 149 (1): 27-30
2. Campbell AH, Liddelow AG. Significant variations in the shape of the trachea and large bronchi. *Med J Aust* 1967; 1(20): 1017-1020
3. Mackenzie CF, McAslam TC, Shin B, Schellinger D, Helrich M. The shape of the human adult trachea. *Anaesthesiology* 1978; 49 (1): 48-50
4. Way LW. *Current surgical diagnosis and treatment*. 11<sup>th</sup> ed. Norwalk: Appleton and Lange, 2003: 196
5. Richard DL, Wayne V, Adam MMW. *Gray's Anatomy for student*. 1<sup>st</sup> ed. Edinburgh: Elsevier Churchill Livingstone, 2005: 145
6. Cooper JD, Grillo HC. Experimental production and prevention of injury due to cuffed tracheal tubes. *Surg Gynecol Obstet* 1969; 129: 1235-1241
7. Bradbeer TI, James MI, Sear JW. Tracheal stenosis associated with a low-pressure cuffed endotracheal tube. *Anaesthesia* 1976; 31: 504-507
8. Salem MR, Mathrubhutham M, Benett EJ. Difficult intubation. *N Engl J Med* 1976; 295 (16): 879-881