

ATHEROSCLEROTIC CHANGES IN THE DIAGONAL ARTERIES OF THE HEART OF BANGLADESHI MALE - A POST MORTEM STUDY

AKM Moinuddin¹ BM Ali Yousuf² Md Shaikul Islam³

Abstract

Luminal narrowing of coronary arteries due to atherosclerosis and subsequent ischemic heart disease is increasing in Bangladeshi people. Area of myocardium supplied by secondary epicardial coronary arteries is less than the primary epicardial coronary arteries, yet it is important to have an estimate regarding their involvement with atherosclerosis. To observe the structural changes, a study was carried out in the department of anatomy, BSMMU, Dhaka in the period between May 2002 and June 2003. A total of 32 hearts were collected from unclaimed dead bodies on which routine post mortem examination was done in the morgue of Dhaka Medical College hospital and Sir Salimullah Medical College Hospital, Dhaka. Age-at-death of the subjects ranged from 20 to 60 years. The diagonal branches of the anterior interventricular arteries were dissected out following their course. Macroscopic findings of the study found were that about one third of the diagonal arteries were involved with atherosclerosis. Both grade-I lesion (fatty streak) and grade-II lesion (fibrous plaque) were found, though none of the vessel showed grade III lesion (ulceration, hemorrhage, necrosis) or grade IV lesion (calcification). A significant positive correlation was found between age-at-death of the subject and atherosclerotic intimal surface area.

Key words: diagonal artery; age-at-death of subject; atherosclerosis.

Introduction

Atherosclerosis of coronary artery commonly causes angina pectoris & myocardial infarction. It causes more death and serious morbidity in the western world. The incidence of angina pectoris & ischemic heart disease is also increasing in Bangladeshi

people¹. Growing awareness about cardiovascular disorder, sophisticated laboratory equipment in diagnostic field, increasing number of cardiovascular specialist etc. are probably factors in detecting more cardiovascular related cases. The paucity of information regarding the structural changes in the coronary vessels, particularly in the secondary epicardial arteries is lacking. The evidence gathered by different investigative procedure is indirect. So a postmortem study to know the structural changes occurring in the coronary vessels is an alternative. But, still, as it is not possible to know the history of the cardiovascular status of the dead persons, a real picture of atherosclerotic condition is not possible to evaluate. It is known that atherosclerosis usually affect the male person more than female^{2,3}. Racial variation⁴ as well as geographic variation⁵ in the incidence of coronary atherosclerosis has also been reported. It is also well documented that initial atherosclerotic involvement in coronary vessels in the first two decade of life does not vary with age, sex, race or environment^{5,6,7,8}. A numbers of risk factors have been identified in famous Framingham (USA) study in 1988. Of various risk factors four are more significant e.g., (a) hypertension (b) hyperlipidemia (c) cigarette smoking and (d) the diabetes mellitus⁸.

Method

From 32 hearts, the diagonal arteries were dissected out, squeezed gently to remove blood clot, washed in tap water and put into 10% formol saline for fixation. Each vessel was cut longitudinally and flattened by placing it in between two glass-slides holding them together by rubber bands. Each segment of artery was stained with Sudan IV as it coloured the fatty lesion of intima red. The outline of the arterial wall and the different types of atherosclerotic lesion were marked with a black OHP marker pen on a transparent sheet placing the sheet over the arterial segment. Then the tracing were subjected to computer for scanning and auto CAD software to calculate the total surface area involved as well as area of different types of lesion

-
1. Assistant Professor of Anatomy
Chittagong Medical College, Chittagong
 2. Professor of Anatomy
Chittagong Medical College, Chittagong
 3. Associate Professor of Anatomy
Chittagong Medical College, Chittagong

Correspondence : Dr AKM Moinuddin

Results

About 35% of the diagonal arteries were affected with different grades of atherosclerosis. Age-at-death of the subjects ranged from 20 to 60 years. Though atherosclerotic grade-I lesion (fatty streak) occur early in the second decade, grade II lesion (fibrous plaque) was found beyond 45 years of age. No grade III or grade IV lesion was detected in the present study. Out of 11 affected diagonal arteries 27% of arteries showed more than 25% intimal surface involvement having both grade I and grade II lesion and 6.3% showed <50% intimal involvement with atherosclerosis. Maximal involvement of intimal surface area found in the present study in one case was 37.7% of which grade II lesion invasion was 27% (about 71.7% of the affected area). A significant positive correlation ($P<0.05$) was found when intimal surface area was correlated with age-at-death of the subject.

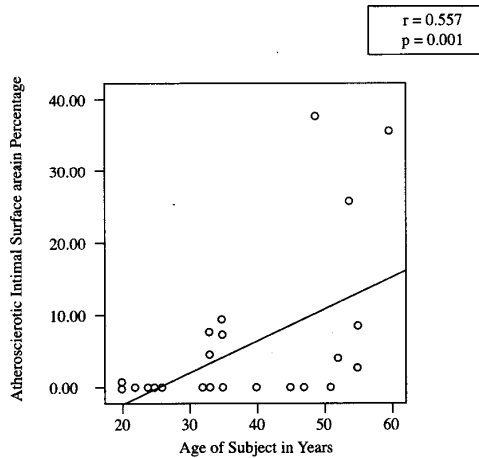


Fig 1 : Depicts a significant positive correlation ($p<0.05$) when internal surface area was correlated With age-at- death of subject.

Table I : Age-at-death of subject and percent intimal surface area affected with atherosclerosis

Value	Age (years)	Intimal surface area involved (%)
Range	20 – 60	0.0 – 37.7
Mean ± SD	35.5 ± 12.4	4.5 ± 9.9

Table II : Percent intimal surface area affected with different types (grades) of atherosclerosis

Value	Grade I (%)	Grade II (%)
Range	0 – 32.33	3.31 – 26.99
Mean ± SD	3.19 ± 6.59	1.31 ± 5.12

Grade I: Fatty streak, spot

Grade II: Fibrous plaque

Discussion

Atherosclerotic changes in the coronary arteries progress with age. Coronary atherosclerosis in the form of fatty streak (grade I) was found in the second decade & almost all coronary arteries showed atherosclerotic changes in the fifth decade⁹. In the present study, fatty streak was evident in the second decade and almost all vessels had shown atherosclerotic changes in the fifth decade. A general trend of increased percentage of atherosclerotic involvement with increasing age was observed in the present study. No vessel had shown involvement more than 50% intimal surface area even at the age of 60 in Bangladeshi male. Mathur et al. (1961) observed coronary atherosclerosis in the form of fatty streak in the second decade and fibrous plaque in appreciable amount in the fourth decade. Complicated and calcified lesion were seen in the fifth decade Observation in the present study had shown fatty streak changes in the second decade and fibrous plaque transformation of fatty streak at late part of the fifth decade. No complicated or calcified lesion was seen even at the end of fifth decade. It was also observed that different types of lesion ensue in different rates as age advanced which would vary in different races also^{3,7}.

Conclusion

In different studies, it was shown that among primary coronary arteries, the left anterior descending artery was involved more in atherosclerosis than that of the other primary arteries. The diagonal artery, being one of the branches of the left anterior descending artery, is perhaps involved more among the other secondary epicardial arteries. Risks factors contribute much to the extent and severity of coronary atherosclerosis. More studies, therefore, are recommended addressing various facets of the problem.

References

1. Islam MS. Postmortem study of atherosclerosis in the aorta and coronary arteries in Bangladeshi males [thesis]. Dhaka : University of Dhaka; 1996
2. Schoen FJ. The heart. In: Kumar V, Abbas AK, Fausto N. editors. Robbins pathologic basis of disease. 7th ed. Philadelphia: WB Saunders Company 2004; 571–587

3. Strong JP, Solberg LA, Restrepo C. Atherosclerosis in persons with coronary heart disease. *Lab Invest* 1968; 18: 527–537
4. Holman RL, McGill HC Jr, Strong JP, Geer JC. Techniques for studying atherosclerotic lesions. *Lab invest* 1958a; 7: 42–47
5. Gore I, Robertson WB, Hirst AE, Hadley GG, Koseki Y. Geographic differences in the severity of aortic and coronary atherosclerosis in the United States, Jamaica, W.I. South India and Japan. *Am J Pathol* 1960; 36: 559–573
6. Tejada C, Gore I, Strong JP, McGill HC Jr. Comparative severity of atherosclerosis in Costa Rica, Guatemala and New Orleans. *Circulation* 1958; 18: 92–97
7. Holman RL, McGill HC Jr, Strong JP, Geer JC. The natural history of atherosclerosis: the early aortic lesions as seen in New Orleans in middle of the 20th century. *Am J Pathol* 1958b; 34: 209 – 230
8. Berenson GS, Wattigney WA, Tracy RE, Newman III WP, Srinivasan SR, Webber LS, et al. Atherosclerosis of the aorta and coronary arteries and cardiovascular risk factors in persons aged 6 – 30 years and studied at necropsy (The Bogalusa Heart Study). *Am J Cardiol* 1992; 70: 851 – 858
9. Mathur KS, Patney NL, Kumar V. Atherosclerosis in India: an autopsy study of the aorta and the coronary, cerebral, renal and pulmonary arteries. *Circulation* 1961; XXIV: 68 – 75
10. Roberts WC, Jones AA. Quantification of coronary arterial narrowing at necropsy in acute transmural myocardial infarction: analysis and comparison of findings in 27 patients and 22 controls. *Circulation* 1980; 614: 786 – 790