

SALMONELLA NECK ABSCESS: A CASE REPORT

Mostafa Mahfuzul Anwar¹ Tareq Uddin Ahmed²

Abstract

Focal Salmonella infection in head neck region is very rare. It may develop in uncontrolled diabetic or immunocompromised patients without any preceding intestinal manifestation of the disease. Combined surgical drainage and medications are necessary to cure it. Early diagnosis and intervention are imperative to avoid mortality.

Key words : salmonella; abscess; neck

Introduction

Salmonella is a gram negative rod shaped organism belongs to enterobacteriaceae group. The organism enters via oral route with contaminated foods or drinks. The mean infective dose to produce clinical infection is 10⁵-10⁸ organisms, but in some species 10³ organisms are enough. Among the host factors that contribute to resistance to infection are gastric acidity, normal intestinal flora and immunity of the patient¹. In human beings Salmonella produces three main type of disease- a. Enteric fever b. Bacteraemia with focal lesions c. Enterocolitis. Focal lesion in head neck region is a rare finding. It usually develops in immunosuppressed states. Following oral infection, there is early invasion of blood stream with development of focal lesions in this group of patients. Intestinal manifestations are often absent here¹. Blood culture and specimens from focal lesions are positive. Here we present a case of Salmonella neck abscess in a diabetic patient.

Cases report

A 55 years old male patient from suburban area of the city was admitted to Chittagong Medical College Hospital with the complaints of painful neck swelling and fever for the last 7 days. The swelling was gradually enlarging in size with frequent local throbbing type of pain within the swelling. The fever was continuous, as high as 103°F and associated with chill and rigor. He also complains of painful swallowing for the same duration. His bowel habit was normal. There was no complaint regarding the

urinary system and there was no history of respiratory distress. The patient had type II diabetes for the last couple of years but the control was poor. On general examination, he was mildly anaemic, nondehydrated, body temperature was 102°F, pulse rate was 110/min, blood pressure was within normal limit. All other system revealed normal findings. On local examination, there was a tender, hot and inflamed swelling in upper part of the neck on left side denoting an abscess formation. In laboratory investigations, total WBC count was 11000, ESR was 50 mm, RBS was 320 mg, serum urea, and electrolytes were within normal limit. X-ray soft tissue neck and chest and ECG revealed normal findings. Immediately after admission, injectable antibiotics in the combination of Cephadrine, Flucloxacillin and Metronidazole were started. Soluble insulin was started to control diabetes. The patient underwent incision and drainage of neck abscess under local anaesthesia. The pus from abscess and blood was sent for C/S. Both the specimen revealed Salmonella as a causative agent of the disease and it was sensitive to Ceftriaxone and Ciprofloxacin. Injection Ceftriaxone was started after having the C/S report. But the patient gradually deteriorated and developed septicemia. He died on 8th day after admission.

Discussion

Salmonella is a gram negative rod shaped organism acquired by oral route. In human beings it causes enteric fever, systemic infection and enteritis. Very rarely it can cause focal infection like neck abscess, lung abscess, bone infection etc¹. The chance of developing focal infection is high when the patient is diabetic or immunocompromised^{2,3}. Chronic alcohol abuse and chronic liver disease also may be considered as precipitating factor in focal infection^{4,5}. Persons with sickle cell disease are exceedingly susceptible to salmonella infections particularly osteomyelitis¹. Salmonella may ferment glucose and produces gas. So, gas forming abscess may be a clinical presentation^{6,7}. Neck abscess may turn into necrotizing fasciitis in immunocompromised individuals which is invariably fatal⁸. Acute retropharyngeal abscess is a serious disease in children. Rarely Salmonella is a causative agent of this serious disease⁹. In head neck region, a carrier

1. Assistant Professor of Otolaryngology and Head-Neck Surgery Chittagong Medical College, Chittagong
2. Assistant Registrar of Otolaryngology and Head-Neck Surgery Chittagong Medical College Hospital, Chittagong

Correspondence : Dr Mostafa Mahfuzul Anwar

state of salmonella in parotid gland was postulated, which progressed to focal abscess and was subsequently complicated by bacteraemia and haematogenous spread to liver, spleen and lungs⁴. In neck infection, salmonella may act as an oxygen consumer in the infected tissue facilitating the growth of anaerobic cocci, hence the development of a devastating soft tissue infection¹⁰. Although serological tests are useful in diagnosing salmonella infection, but blood and pus or aspirate from neck abscess for culture must be taken to confirm the diagnosis. In bone infection, bone marrow culture may be useful¹¹. If an individual develops a neck swelling during enteric fever, fine needle aspiration should be done for culture to exclude focal infection.

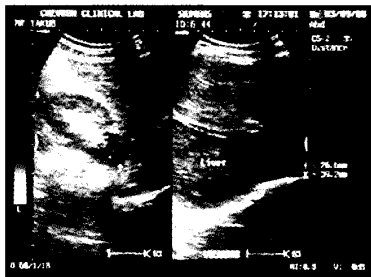


Fig 1 : Ultrasonography of whole abdomen showing mass possibility of colonic mass

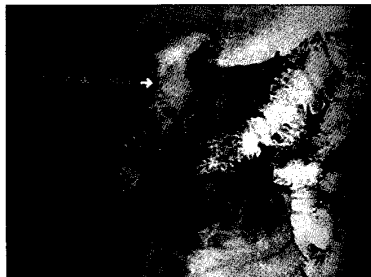


Fig 2 : Barium enema showing abnormal communication between right side of colon and duodenum

Combined surgical drainage and medical treatment is required to treat this condition. Medications effective against Salmonella infection are Ampicillin, Cephalosporins, Quinolones, Azithromycin etc. But multiple drug resistance transmitted genetically by plasmids among enteric bacteria is a problem in treating salmonella infections¹. Susceptibility testing is an important adjunct selecting a proper antibiotic. As the salmonella focal infections develop in

immunocompromised or in a poorly controlled diabetic case, mortality is quite high due to systemic dissemination. In our patient, Ceftriaxone and Ciprofloxacin were sensitive drugs to the organism. All other antibiotics were found to be resistant. The patient had uncontrolled diabetes mellitus as well as bacteraemia during admission to the hospital. When the culture report was available, the patient already developed septicaemia from which he could not recovered.

Conclusion

Salmonella infection should be suspected in neck abscess of diabetic or immunocompromised patients which does not respond to empirical antibiotic treatment. Blood sample as well as pus or aspirate from focal lesion should be sent for culture sensitivity testing. Early diagnosis and treatment are essential to save the patient.

References

1. Brooks GF, Butel JS, Morse SA. Enteric Gram-Negative Rods. In Jawetz, Melnick & Adelberg's Medical Microbiology. 23rd ed, Boston: McGraw-Hill companies, 2004; 248-260
2. Bahar G, Dansuk Z, Kocaturk S, Cakir T, Mert A. Abscess of the neck caused by Salmonella enteritidis. Otolaryngol Head Neck Surg. 2003; 129(4): 445-447
3. Ray J, Shotton JC, Lobo VJ. A rare case of Salmonella neck abscess. J Laryngol Otol. 1997; 111(5): 489-490
4. Reyes CV, Jensen JD. Parotid abscess due to Salmonella enteritidis: A case report. Acta Cytol. 2006; 50(6): 677-679
5. Yamagata K, Takeda M, Onizawa K, Yoshida H. Submandibular abscess caused by Salmonella. Int J Oral Maxillofac Surg. 2006; 35(10): 969-971
6. Shen CH, Lin YS, Chang FY. Gas forming parotid abscess in a diabetic patient: An unusual complication of Salmonella enteritidis bacteraemia. Am J Med Sci. 2008; 336(6): 504-507
7. Jasmi AY, Rohaizak, Meah FA, Sulaiman BT. Typhoid thyroiditis. Med J Malaysia. 1998; 53(1): 109-111
8. Luo CW, Liu CJ. Neck abscess and necrotizing fasciitis caused by salmonella: a report of 2 cases. J Oral Maxillofac Surg. 2007; 65(5): 1032-1034

9. Su FH, Chen PT, Chiu YC, Chen JW. Salmonella retropharyngeal abscess in a child: case report and literature review. *Pediatr Infect Dis J.* 2003; 22(9): 833-836
10. Leiberman A, Tovi F, Barki Y, Alkan M. Salmonella neck abscess associated with jugular vein thrombosis. *J Laryngol Otol.* 1991; 105(11): 966-967