

## PAPILLARY CARCINOMA OF THE THIRD PART OF THE DUODENUM : A CASE REPORT AND REVIEW OF LITERATURE

Abu Sayeed <sup>1</sup> Dilruba Siraji <sup>2</sup> Mamtaz Begum <sup>3</sup> S M Ashraf Ali <sup>4</sup>

### Abstract

Papillary carcinoma of the third part of the duodenum is rare and difficult to diagnose.

A middle aged man presented with intractable vomiting for six months with mild anemia. Repeated upper GI endoscopy was reported normal. Subsequent Endoscopy revealed a 3cm x 3cm protruding tumor in the posterior wall of the third part of duodenum. Endoscopic tissue histopathology was inconclusive. C T scan revealed a low attenuated soft tissue mass in the third part of the duodenum. Duodenotomy and local excision of the tumor was performed. Histopathology of the tumour detected it as a papillary carcinoma. The patient showed no sign of recurrence and has been disease free for more than 24 months after surgery.

The rarity and its non-specific symptoms often lead clinicians and patients to suspect other more benign differential diagnoses. Critical endoscopic examination and imaging have enabled more of these cases to be unearthed.

**Key words:** distal duodenal tumour; intractable vomiting; resection

### Introduction

Although the small bowel comprises 75% of the total length of the gastrointestinal tract, it gives rise to merely 2-6% of all primary gastrointestinal malignancies <sup>1,2</sup>. The duodenum constitutes only the first 25 cm of the small bowel, yet duodenal neoplasia accounts for 35% of all benign and 17% of all malignant small bowel tumours <sup>3,4</sup>.

The surgical management of duodenal pathology is challenging because of its retroperitoneal position and shared blood supply with the pancreas. For

supra ampullary and peri-ampullary neoplasms, the conventional surgical option is pancreatoduodenectomy (PD), even if the pancreas is not involved and even in premalignant disease.

A less radical procedure is local resection of the papilla (ampullectomy) with the adjacent pancreatic tissue containing the terminal bile and pancreatic ducts <sup>5</sup>. More recently, pancreas-sparing total duodenectomy (PSTD) has been described, generally referring to total resection of the duodenum including the papilla but not the adjacent pancreatic tissue or the terminal biliary and pancreatic duct <sup>6-11</sup>. Authors emphasized the advantages over local resection that the dissection is carried out in a defined tissue plane a long-term solution for diffuse duodenal disease (e.g. in familial adenomatous polyposis) and simpler ductal anastomoses<sup>12-16</sup>. One report describes a pancreas-sparing suprapapillary duodenectomy for an exophytic hepatocellular carcinoma directly invading the duodenum<sup>17</sup>. Reports of the surgical management of infrapapillary duodenal pathology are largely limited to case reports and small series<sup>18-20</sup>. For neoplasms that arise in the third and fourth parts of the duodenum (D3, D4), a conservative duodenectomy that preserves the pancreas and papilla can provide adequate tumour clearance while avoiding the additional dissection and risk associated with the biliary and pancreatic anastomoses implicit in the common alternative PD or PSTD<sup>21-24</sup>. Other advantages of this procedure include a shorter operative time and the preservation of more normal anatomy and function allowing postoperative endoscopic surveillance<sup>21-24</sup>. We describe our experience with duodenotomy and excision of the tumor in the 3rd part.

### Case presentation

A 40-year male presented with a six month history of vomiting after meals. He had no history of abdominal pain, jaundice, melaena or features suggestive of raised intracranial pressure. Physical examination revealed mild anemia, abdominal tenderness without a palpable mass. Hb was 9 gm%, S bilirubin 23.0 micromol/dl, plasma glucose random 6.0 mmol/l, renal status and electrolytes

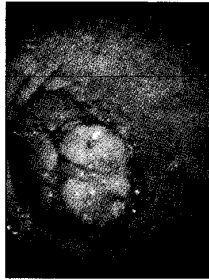1. Professor of Medicine  
Chittagong Medical College, Chittagong
2. Associate Professor of Physiology  
Chattagram Maa-O-Shishu Hospital, Agrabad, Chittagong
3. Lecturer of Physiology  
Chittagong Medical College, Chittagong
4. Associate Professor of Surgery  
Chittagong Medical College, Chittagong

**Correspondence :** Dr Abu Sayeed

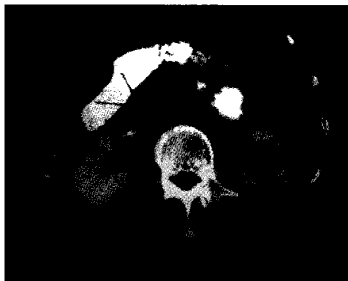normal. Ultrasonography of abdomen, chest X-ray and ECG were normal.

Upper GI endoscopy was reported normal two times. Subsequent endoscopy revealed a cauliflower like growth at the third portion of the duodenum with a smooth surface and no ulceration (Fig-1).


Biopsy revealed a duodenal tissue showing dysplastic changes in gland epithelial cells and evidence of overt malignancy was absent, an abdominal CT scan revealed a nodular mass (Fig-2). Operative findings were that the tumor was in the posterior wall of the third part of duodenum. Duodenum was kokerized, duodenotomy performed, growth removed along with the attached duodenal wall. Duodenal wall closed in layer. No regional or metastasis enlarged lymph node was noted. Liver, hepatoduodenal ligament was found normal. The resected margins were free. Histopathology of the resected specimen revealed a well differentiated papillary adenocarcinoma (Fig-3). He had an uneventful postoperative course. He has been followed up for 2 years and remains recurrence free.



**Fig 1 :** Showing single nodular mass in the third part of the duodenum



**Fig 2 :** Showing CT of the abdomen detecting a mass in the duodenum



**Fig 3 :** Histopathological picture of resected duodenal tumour

### Discussion

Adenocarcinoma of the duodenum is an exceedingly rare disorder. The most frequent symptoms found are jaundice (11.1-55.8%), nausea/vomiting (21-51.8%), pain (11.1-59.1%), weight loss (10.1-57.6%) and anemia (22.5-60.6%)<sup>2,4</sup>. In fact, several authors pointed out that on the average symptoms were present before the diagnosis for a minimum of 3 months, but in the most important case studies the duration of the symptomatology was around 6-8 months<sup>2,3,4</sup>.

The nonspecific clinical presentation, which often mimics benign conditions, is the main pitfall for an early diagnosis of duodenal cancer<sup>2,3,4</sup>. The index of suspicion for the tumor remains very low, and the lack of specific symptoms or physical signs substantially delays diagnosis and treatment<sup>25,26</sup>. The present case presented with intractable vomiting and rather absent jaundice took 6 months time to establish the diagnosis.

For predominantly anatomical reasons, upper GI endoscopy has limitations in the diagnosis of tumors located in the third and fourth portions of the duodenum. When there is clinical suspicion of tumour in these sites, CT, MRI, ultrasonography is warranted.

Papillary tumors are uncommon before the age of 45 years; 80% of papillary tumors occur between the ages of 60-80 years<sup>4,25</sup>. At diagnosis, the average person is aged 62 years (range of 4 months to 79 years)<sup>5</sup>. No gender predilection exists. A slight male predominance exists in the incidence of papillary tumors, although this may be beginning to change<sup>4</sup>. Our patient was male and of 40 years age. As endoscopic biopsy material showed dysplastic change and even low grade malignancy like neuroendocrine carcinoma duodenotomy and local

excision is suggested<sup>27</sup>. Although the best treatment of papillary carcinoma of duodenum is, Whipple's operation to avoid risk of biliary and pancreatic anastomosis we performed duodenotomy and local excision.

The significance of the primary location in regard to prognosis remains controversial<sup>25, 26</sup>. Lowell et al.<sup>28</sup> reported longer survival among patients with distal tumors, whereas Sohn et al.<sup>20</sup> reported longer survival in patients with proximal tumors. Other authors did not find statistically significant differences in survival based on site, even though it is evident that there is a more favorable prognosis for distal duodenal adenocarcinoma. Patient selection and stage probably account for such differences<sup>28</sup>. The role of postoperative adjuvant therapy is still unclear, and efforts are underway with 5-fluorouracil based chemotherapy regimens<sup>29</sup>. We performed duodenotomy and local excision. We have not applied chemotherapy in our patient.

#### Conclusion

Although carcinoma of the duodenum, other than of the ampulla of Vater region, is very rare and diagnosis is often late. The disease should be suspected, even if symptomatology is poor. It is sometimes needed and possible to visit the distal duodenum to evaluate symptomatic patients with intractable vomiting. However, this requires careful observation of the mucosa, including that of the distal duodenum, at duodenoscopy. PSTD is an acceptable option of treatment, duodenotomy and local excision of the tumour is one step advancement and safe procedure.

#### References

1. Williamson RC, Welch CE, Malt RA. Adenocarcinoma and lymphoma of the small intestine. Distribution and etiologic associations. *Ann Surg* 1983; 197: 172-178
2. Ciccarelli O, Welch JP, Kent GG. Primary malignant tumors of the small bowel. The Hartford Hospital experience, 1969-1983. *Am J Surg* 1987; 153: 350-354
3. Cooper MJ, Williamson RC. Enteric adenoma and adenocarcinoma. *World J Surg* 1985; 9: 914-920
4. Manier MM, Bockus HLR. Duodenal neoplasms. In: *Gastroenterology*. Philadelphia, PA: Saunders, 1985; 1428-1438
5. Chappuis CW, Divincenti FC, Cohn IJ. Villous tumors of the duodenum. *Ann Surg* 1989; 209: 593-598
6. Chung RS, Church JM, van Stolk R. Pancreas-sparing duodenectomy: indications, surgical technique, and results. *Surgery* 1995; 117: 254-549
7. Ryu M, Kinoshita T, Konishi M, Kawano N, Arai Y, Tanizaki H et al. Segmental resection of the duodenum including the papilla of Vater for focal cancer in adenoma. *Hepatogastroenterology* 1996; 43: 835-838
8. Tsiotos GG, Sarr MG. Pancreas-preserving total duodenectomy. *Dig Surg* 1998; 15: 398-403.
9. Nagai H, Hyodo M, Kurihara K, Ohki J, Yasuda T, Kasahara K et al. Pancreas-sparing duodenectomy: classification, indication and procedures. *Hepatogastroenterology* 1999; 46: 1953-1958
10. Alarcon FJ, Burke CA, Church JM, van Stolk RU. Familial adenomatous polyposis: efficacy of endoscopic and surgical treatment for advanced duodenal adenomas. *Dis Colon Rectum* 1999; 42: 1533-1536
11. Farnell MB, Sakorafas GH, Sarr MG, Rowland CM, Tsiotos GG, Farley DR et al. Villous tumors of the duodenum: reappraisal of local vs. extended resection. *J Gastrointest Surg* 2000; 4: 13-21
12. Kalady MF, Clary BM, Tyler DS, Pappas TN. Pancreas-preserving duodenectomy in the management of duodenal familial adenomatous polyposis. *J Gastrointest* 2002; 6: 82-87
13. Konsten JL, Kazemier G, Dees J, van Eijck CH. [Pancreas-preserving total duodenectomy due to familial adenomatous polyposis in 4 patients]. *Ned Tijdschr Geneesk* 2002; 146: 621-624
14. Lundell L, Hyltander A, Liedman B. Pancreas-sparing duodenectomy: technique and indications. *Eur J Surg* 2002; 168: 74-77
15. Sarmiento JM, Thompson GB, Nagorney DM, Donohue JH, Farnell MB. Pancreas-sparing duodenectomy for duodenal polyposis. *Arch Surg* 2002; 137: 557-562
16. Takagi H, Miyairi J, Hata M, Tuboi J, Kamijou T, Nakajima K et al. Multiple somatostatin- and gastrin-containing carcinoids of the duodenum:

- report of a case treated by pancreas-sparing duodenectomy. *Hepatogastroenterology* 2003; 50: 711-713
17. Cho A, Ryu M, Ochiai T. Successful resection, using pancreas-sparing duodenectomy, of extrahepatically growing hepatocellular carcinoma associated with direct duodenal invasion. *J Hepatobiliary Pancreat Surg* 2004; 9: 393-396
  18. Kawano N, Ryu M, Kinoshita T, Konishi M, Iwasaki M, Furuse J et al. Segmental resection of the duodenum for treating leiomyosarcoma associated with von Recklinghausen's disease: a case report. *Jpn J Clin Oncol* 1995; 25: 109-112
  19. Maher MM, Yeo CJ, Lillemoe KD, Roberts JR, Cameron JL. Pancreas-sparing duodenectomy for infra-ampullary duodenal pathology. *Am J Surg* 1996; 171: 62-67
  20. Sohn TA, Lillemoe KD, Cameron JL, Pitt HA, Kaufman HS, Hruban RH et al. Adenocarcinoma of the duodenum: factors influencing long-term survival. *J Gastrointest Surg* 1998; 2: 79-87
  21. Suzuki H, Yasui A. Pancreas-sparing duodenectomy for a huge leiomyosarcoma in the third portion of the duodenum. *J Hepatobiliary Pancreat Surg* 1999; 6: 414-417
  22. Orda R, Sayfan J, Wasserman I. Surgical treatment of leiomyosarcoma of the distal duodenum. *Dig Surg* 2000; 17: 410-412
  23. Ammori BJ. Laparoscopic pancreas-preserving distal duodenectomy for duodenal stricture related to nonsteroidal antiinflammatory drugs (NSAIDs). *Surg Endosc* 2002; 16: 1362-1363
  24. Eisenberger CF, Knoefel WT, Peiper M, Yekebas EF, Hosch SB, Busch C et al. Pancreas-sparing duodenectomy in duodenal pathology: indications and results. *Hepatogastroenterology* 2004; 51: 727-731
  25. Tocchi A, Mazzoni G, Puma F, Miccini M, Cassini D, Bettelli E, Tagliacozzo S: Adenocarcinoma of the third and fourth portions of the duodenum: results of surgical treatment. *Arch Surg* 2003, 138: 80-85
  26. Delcore R, Thomas JH, Forster J, Hermreck AS: Improving resectability and survival in patients with primary duodenal carcinoma. *Am J Surg*, 1993; 166: 626-630
  27. Naohiro S, Munitoshi T, Masunu K: Primary Small cell neuroendocrine carcinoma of the duodenum- a case report and review of literature. *World Journal of surgical oncology* 2004; 2: 28
  28. Lowell JA, Rossi RL, Munson JL, Braasch JW: Primary adenocarcinoma of third and fourth portions of duodenum. Favorable prognosis after resection. *Arch Surg* 1992, 127: 557-560
  29. Ryder NM, Ko CY, Hines OJ, Gloor B, Reber HA: Primary duodenal adenocarcinoma: a 40 year experience. *Arch Surg* 2000, 135: 1070-1075