

## INTRAVESICAL FOREIGN BODY: A CASE REPORT

Mohammed Monowar-Ul-Haque<sup>1</sup> Md Nizamuddin<sup>2</sup>

### Summary

*Foreign body in the urinary bladder is not very common. It may occur by self insertion or migration from neighboring organs. It represents a urologic challenge which requires prompt management and should be treated as emergencies. Most of the foreign bodies in the urinary bladder can be successfully removed endoscopically. Sometimes open surgical procedure may require in removing the foreign body. Removal of foreign body from urinary bladder may be quite challenging requiring imaginations & high level surgical skills. Here we reported a case of 29 years old mentally retarded man with an intravesical foreign body. We successfully removed the foreign body by endoscopic procedure under general anesthesia. In post operative follow up there was no voiding problem & patient was advised for psychiatric consultation.*

### Key words

Foreign body; urinary bladder; urological emergency; endoscopic removal

### Introduction

The presence of foreign bodies in the urinary bladder has always been an interesting topic. Every urologist occasionally comes across such patients in his practice. A large number of cases have been reported in the literature, and they have now become an important part of the study of urological diseases [1]. A foreign body in the urinary bladder, according to Jung et al is a rare occurrence [2]. It describe the condition as being exceptional and not a common emergency [3]. Foreign bodies in the urinary bladder may occur by self-insertion or migration from the neighboring organs [4]. They vary from tissue originating from adjacent organs to metallic objects such as electric wires [5]. The reasons for their presence in the urinary bladder also vary from sexual and erotic manipulation to iatrogeny and complementary and alternative medicine practice [6-8].

1. Assistant Professor of Urology  
Chittagong Medical College, Chittagong
2. Assistant Professor of Anesthesia  
Chittagong Medical College, Chittagong

**Correspondence:** Dr Mohammed Monowar-Ul-Haque  
e-mail: shamimuro@gmail.com

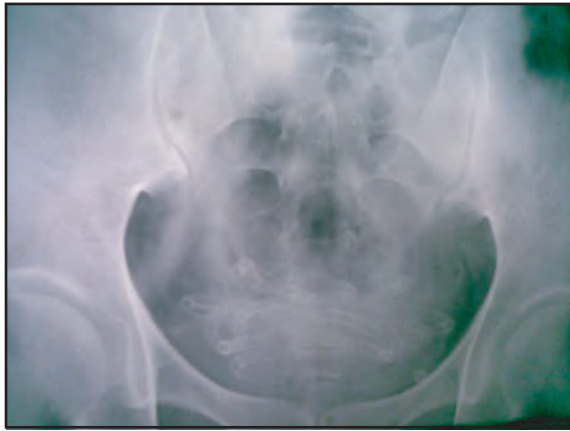Objects that have been reported in the urinary bladder include electrical wires, chicken bones, wooden sticks, thermometers, bullets, intrauterine contraceptive devices (IUCDs), encrusted sutures, surgical staples with stones, ribbon gauze, pieces of Foley catheter, broken pieces of endoscopic instruments, knotted suprapubic catheter and many other items [9].

Not all patients volunteer their history of insertion, especially those who have inserted the objects for sexual gratification. Many patients do not seek advice for months due to embarrassment. The presenting features usually include urinary tract infection, pain and haematuria [10]. The physical examination is almost always unremarkable, and urine microscopy usually reveals pus cells and red blood cells. Radiopaque objects can easily be seen on radiographs, while others are identified by the sonologist. Cystoscopy is rarely required for diagnosis [1].

A wide variety of complications may follow the presence of foreign bodies in the urinary bladder. Foreign bodies in the urinary tract increase the risk of urinary tract infection [11]. Such infections are often recurrent as a result of bacterial persistence within or on the foreign body and sometimes as a result of poor drainage. The risk of endotoxemia should always be borne in mind in the process of extraction of the foreign body [9].

Foreign bodies in the urinary bladder represent a urologic challenge that requires prompt management and should be treated as emergencies [7]. The wide variety of techniques for removal of intravesical foreign bodies indicates the ingenuity with which urologists have approached the subject. Broadly, these are classified into endoscopic and open surgical approaches, the method used usually depending on the nature and the size of the object and the available expertise and equipment [7]. Endoscopic and minimally invasive techniques should be encouraged. Most of the foreign bodies in the urinary bladder can be successfully removed endoscopically using grasping forceps, stone punch, glass syringe, basket or cutting loop. Smaller foreign bodies can be retrieved intact, whereas bigger ones require fragmentation. Care must be taken to avoid bladder mucosal injury during removal.

Endoscopic removal is associated with minimal morbidity and hospital stay. Sometimes open surgical procedure may require removing the foreign body. With the advent of a variety of modern endoscopic instruments, open surgery is rarely required [1].



**Fig 1 :** X-ray shows PVC pipe coiled in urinary bladder

#### Case report

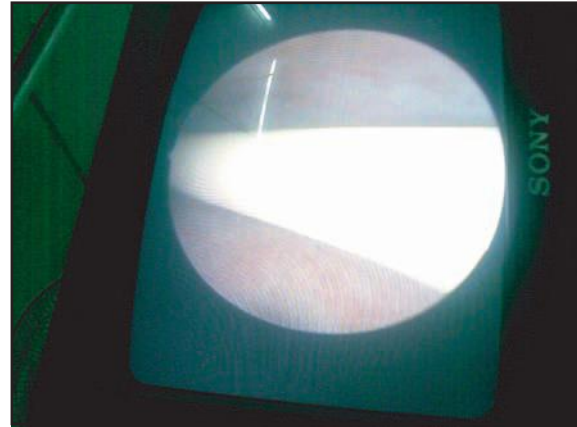
29 years mentally retarded man presented with a 2-week history of frequency, urgency and dysuria. The diagnosis of UTI was made initially and then placed on empirical antimicrobial therapy by community physician. He subsequently presented with severe suprapubic tenderness, fever and near retention.

On examination urinary bladder was palpable with slight tenderness, genitalia & perineal region was normal with normal DRE findings.

Ultrasonography was supplied to us, which suggested multiple irregular bright echogenic structure in urinary bladder, casting strong posterior acoustic shadow & moves with the change of posture. One of the stone covers the internal urethral orifice. The bladder wall was shown to be thickened & irregular.

We were not convinced with the report and asked the patient to repeat the USG with a plain x-ray KUB region. This time USG suggested multiple elongated worms like coiled structure in UB. The X-ray showed a radiopaque smooth tube like substance fully coiled in the bladder without a urethral extension.

Patient or his mother failed to give any history of self introduction of foreign body in the UB. But his mother gave a history of treatment of urinary problem by a village quack at his childhood. But failed to mention whether anything introduced or not in the urinary bladder during treatment.




**Fig 2 :** Endoscopic view of PVC pipe in urethra during removal

An urgent cystoscopy under general anesthesia was done and found a long knotted smooth plastic pipe almost blocking the internal urethral meatus and endoscopic removal of the pipe was done by a grasping forceps without any injury to mucosa of urinary bladder and urethra. It was a 125 cm long smooth PVC pipe with about 10 Fr diameters. A biluminal foley's catheter was introduced.

Post operative period was uneventful. The catheter was removed on the next day and patient was discharged.

The patient reported no voiding problem in follow-up and he was advised for psychiatric consultation.



**Fig 3 :** PVC pipe after removal from urinary bladder

#### Discussion

Foreign bodies may reach the urinary bladder by one of the following modes: iatrogenic, perforation from adjacent organs, via the urethra by self insertion or the traumatic route [12].

This patient did not volunteer a reasonable history to enable a fair assertion of the method of insertion.

That is not unusual, as, according to him most patients are usually too ashamed to admit they had inserted an object for autoerotic, psychiatric, therapeutic, or any other reasons. Patients present when symptoms develop or there are complications [13]. The length of the male urethra makes it impossible to assume that a foreign body found its way into the bladder unknown to the patient, unlike in females in a primitive agricultural setting.

According to them the most common motive associated with the insertion of foreign bodies into the genitourinary tract is sexual or erotic in nature [12]. In adults, they opine that it is commonly caused by insertion of objects used for masturbation, which is frequently associated with a mental health disorder [14]. Such patients are also known to be prone to genital self-emasculation injuries, so they need to be identified and have psychiatric assessment [15].

The variety of foreign bodies inserted into, or attached externally to, the genitourinary tract defies imagination and includes all types of objects [16]. They vary with societies, levels of development, the aim of insertion, and cause. There is clearly a remarkable variation in objects in relation to intravesical foreign bodies and their causes in different societies.

In our case the foreign body may be introduced by the village doctor who treat him in his childhood for urinary problem or may introduce by patient himself for sexual gratification. As the patient is mentally retarded getting a correct history was difficult.

#### Conclusion

Presence of foreign body in the urinary bladder is rare and exceptional and therefore requires a high index of suspicion for diagnosis. Presentation may be delayed which may be complicated and life threatening. It should be managed as urological emergency.

#### Disclosure

All the authors declared no competing interestes.

#### References

1. Mannan A, Anwar S, Qayyum A, Tasneem RA. Foreign body in the urinary bladder and their management: a Pakistani experience. *Singapore Med J*. 2011;52(1):24 - 28.
2. Jung US, Lee JH, Kyung MS, et al. Laparoscopic removal of an intravesical foreign body after laparoscopically assisted vaginal hysterectomy, a case report and review of the literature. *Surg Laparosc Endosc Percutan Tech*. 2008; 18(4):420-427.
3. Martinez-Valls PL, Honrubia VB, Rodriguez TA, et al. Voiding symptoms as presentation of an intravesical foreign body. *Arch ESP Urol*. 2008; 61(7):781-785.

4. Sharma UK, Rauniyar D, Shar WE. Intra vesical foreign body: case report. *KathMandu Univ Med J*. 2006; 4(3):342-344.
5. Osca JM, Broseta E, Server G, et al. Unusual foreign bodies in the urethra and bladder. *Br J Urol*. 1991; 68(5):510-512.
6. Trehan RK, Haroon A, Memon S, Turna D. Successful removal of a telephone cable, a foreign body through the urethra into the bladder: a case report. *J Med case Reports*. 2007; 1:153.
7. Rafique M. Intravesical foreign bodies: review and current management strategies. *Urol J*. 2008; 5(4):223-231.
8. Izumi K, Takizawa A, Udagawa K, et al. Bladder stone secondary to migration of an acupuncture needle. *Hinyokika Kiyo*. 2008; 54(5): 365 - 367.
9. Eshioho Irekpita, Peter Imomoh, Emeka Kesieme, Vincent Onuora. Intravesical foreign bodies: a case report and a review of literature. *International Medical Case Reports Journal*, 2011; 4 35-39.
10. Tanagho EA. Disorders of the bladder, prostate and seminal vesicles. Tanagho EA, McAninch JW, eds. *Smith's general urology*. 15th edi. In Singapore: Mcgraw Hill, 2004;576-89.
11. Jensen CS, Walter S. Urinary tract infections: occurrence, causes and prevention. *Ugeskr Laeger*. 2007; 169(49):4265-4268.
12. Van Ophoven A, deKernion JB. Clinical management of foreign bodies of the genito-urinary tract. *Urology*. 2000; 164(2):274-287.
13. Aliabadi H, Cass AS, Gleich P, Johnson CF. Self-inflicted foreign bodies involving lower urinary tract and male genitals. *Urology*. 1985; 26(1):12-16.
14. Garcia RV, Varel SM, Fernandez GL. Urethra foreign bodies: 2 cases. *Arch Esp Urol*. 1999; 52(1):74-76.
15. Patel SR, Tharasechan S, Handel LN, et al. Bilateral manual externalization of testis with self castration in patient with prion disease. *Urology*. 2007; 70(3):590.e15-e16.
16. Osca JM, Broseta E, Server G, et al. Unusual foreign bodies in the urethra and bladder. *Br J Urol*. 1991; 68(5):510-512.