

ORBITAL AND OCULAR MANIFESTATIONS OF ACUTE LEUKEMIA: CLINICAL ANALYSIS IN A TERTIARY CARE HOSPITAL

Ahmed Tanjimul Islam¹ Mohammad Golam Rabbani² Subrata Dey³

Summary

To determine the prevalence of orbital and ocular manifestations in acute leukemia at the time of presentation, sixty (60) patients diagnosed with acute leukemia were examined for ocular lesions by within two weeks of diagnosis before starting chemotherapy. The detailed ocular examination of both eyes was carried out by the ophthalmologist irrespective of the presence or absence of eye symptoms in all cases. Only 3 out of 60 patients presented with eye symptoms (5%). However, ocular changes were found in 16 patients (26%), 11 with lymphoblastic and 5 with myeloid leukemia. The ocular lesions observed were Intraretinal hemorrhages, decreased Visual acuity, Proptosis, Macular hemorrhage, Cotton wool spots, Papilloedema, Vitreous hemorrhage and Sixth nerve palsy. In view of the high prevalence of asymptomatic ocular lesions in acute leukemia, routine Ophthalmic Examination should be included as a part of evaluation at the time of diagnosis.

Key words

Leukemia; Ocular manifestations; Orbital infiltration.

Introduction

Leukemia is a malignant proliferative disorder of leucopoietic bone marrow stem cells characterized by over-crowding of the bone marrow by immature neoplastic leucocytes and widespread infiltration of organs, tissues, and peripheral blood by immature leucocytes [1,2]. Knowledge of the ocular manifestations of Acute leukemia is important not only because of the frequency with which changes are seen, but because the eye often reflects the disease state of the body [3].

1. Medical Officer of Hematology
Chittagong Medical College Hospital, Chittagong
2. Associate Professor of Hematology
Chittagong Medical College, Chittagong
3. Resident Surgeon of Ophthalmology
Chittagong Medical College Hospital, Chittagong

Correspondence: Dr. Ahmed Tanjimul Islam.

Email: drovesomch@gmail.com

Cell: 01554333026

They may be the initial mode of presentation or the first manifestation of relapse of the systemic illness. The spectrum of ocular involvement in acute leukemia can be divided into three groups: (i) Direct infiltration (in iris, choroid, retina, optic nerve) (ii) Vascular abnormalities in Retina (Intraretinal hemorrhages, cotton wool spots, macular hemorrhage, vitreous hemorrhage) which reflect changes in hematological status and (iii) Neuro-ophthalmic signs (papilloedema secondary to raised intracranial pressure and isolated cranial nerve palsies) of CNS disease [4,5]. The aim of this study was to find out the spectrum of orbital and ocular manifestations in acute leukemia.

Materials & methods

Patients admitted and diagnosed as acute leukemia in department of Hematology, Chittagong Medical College Hospital in over a period of nine months (January 2014 to September 2014) were included in this study. Co-existing ocular or systemic disease with leukemia-like ocular manifestations e.g. HIV, Diabetes, Systemic Hypertension, Sickle cell disease and retinal vascular disease were excluded for this study.

The diagnosis of leukemia was based on examination of peripheral blood and bone marrow using morphological criteria, cytochemistry and immunophenotyping. Ophthalmic examination was done within two weeks of diagnosis of acute leukemia before starting chemotherapy. All patients were examined by the ophthalmologist irrespective of the presence or absence of eye symptoms. Ophthalmic evaluation included clinical examination of the eyelids, conjunctiva, cornea, anterior chamber, iris, pupil and lens with a torch light . Fundus examination was done with a direct ophthalmoscope, after dilating the pupils with 1% tropicamide eye drops. Recording of visual acuity was done using Snellen's chart, Exophthalmometry, Slitlamp biomicroscopy, tonometry and indirect ophthalmoscopy were carried out when indicated.

Results

Sixty (60) patients diagnosed as acute leukemia were examined for ocular involvement by an ophthalmologist. 38 were men (63%) and 22 were

women. 32 patient were suffering from Acute Lymphoblastic Leukemia (ALL) (53%) and 28 from Acute Myeloid Leukemia (AML) (47%). The average age was 36 years with a range of 12 years to 65 years. Ocular involvement was seen in 16 patients. So, we found the prevalence of ocular involvement in acute leukemia was 26% (16 out of 60 cases). 11 with ALL and 5 with AML. However, the ocular involvement was slightly less in lymphoblastic leukemia (34.3%, 11 out of 32 cases) than in myeloid leukemia (17.3%, 5 out of 28 cases) (Fig 1).

In our study only 4 patients (6.6 %) presented with eye symptoms (blurred vision, decreased vision, mild eye pain) 3 patients presented with proptosis. The rest of the patients did not have any eye symptoms. The patients with macular hemorrhage in both eye (No. 1) did not complain of any visual symptoms. The clinical profile of patients of acute leukemia with ocular lesions at the time of diagnosis is shown in Table I.

We also found multiple ocular findings in acute leukemia. Of the total 16 cases of acute leukemia, 9 cases had more than one ocular finding (56%) (Fig 2).

Our study revealed that, there were eight types of orbital and ocular findings in acute leukemia. The ocular lesions observed were intraretinal hemorrhages in 8 cases (50%) decreased visual acuity 4, macular hemorrhage in 3, cotton wool spots in 3, proptosis 3, papilloedema 2, vitreous hemorrhage in 1, unilateral sixth nerve palsy in 1 patient (Fig 3).

A majority of the patient with ocular manifestations did not survive for a longer period when compared to those without eye changes. The mortality was higher in patient with ocular involvement than in patients without eye changes. Our study showed in Table I that, 2 patients who presented with proptosis revealed myeloid leukemia (Case 4 and 10). CT scan of Orbit showed a soft tissue mass in the lateral wall of the orbit in both cases. Proptosis disappeared completely during the course of chemotherapy in both of them. In case No. 2 the proptosis (Orbital infiltration) was noted at the time of diagnosis and it disappeared during the course of chemotherapy. Retinal hemorrhages were observed in 6 cases of lymphocytic and 2 cases of myeloid leukemia. There was simultaneous macular hemorrhage in 2, decreased visual acuity in 2, cotton wool spots in 1, papilloedema in 1 patients. More than one ocular lesion was noted in 9 patients.

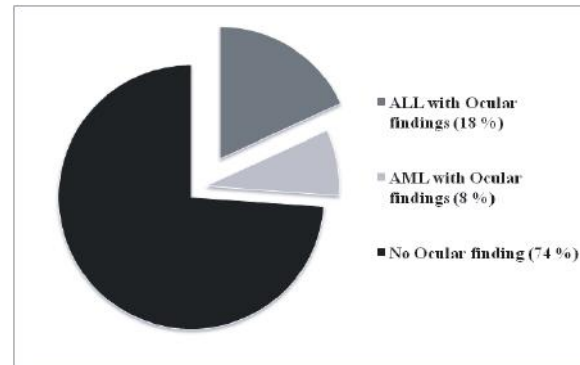


Fig 1 : Percentage of ocular positive findings in Acute leukemia

Table I : Clinical profile of patients with ocular involvement at the time of diagnosis

Serial	Age	Sex	Leukemia type FAB	Hb %	WBC X 10 ⁹ / L	Platelet X 10 ⁹ / L	Ocular Findings
1	27	F	ALL L2	7.3	86	19	Intraretinal Hemorrhage, Macular Hemorrhage (Both eyes)
2	12	M	ALL L2	8.4	142	53	Proptosis (Both eyes)
3	52	M	AML M5	9.1	19	95	Intraretinal Hemorrhage, Vision: 6/36 (Rt)
4	45	F	AML M5	10.3	28	245	Proptosis (Both eyes) Vision: 6/9 (Left)
5	13	M	AML M4	7.9	38	177	Vitreous Hemorrhage (Both eyes)
6	14	M	ALL L2	8.5	55	65	Intraretinal Hemorrhage (Both eyes) Vision: 6/36 (Rt) 6/9 (left)
7	14	M	ALL L2	9.3	62	77	Intraretinal Hemorrhage, Vision 6/9 (Left)
8	17	F	ALL L1	7.1	132	56	Intraretinal Hemorrhage, Macular Hemorrhage (Both eyes)
9	34	F	ALL L2	8.3	88	44	6 th Nerve Palsy (Left)
10	32	F	AML M2	10.6	22	110	Proptosis (Rt)
11	52	F	ALL L3	6.9	48	25	Intraretinal Hemorrhage (Both eyes)
12	36	M	AML M3	8.9	33	93	Cotton Wool Exudates Macular Hemorrhage (Both eyes)
13	53	F	ALL L2	8.1	73	80	Intraretinal Hemorrhage, Papilloedema (Both eyes)
14	25	M	ALL L3	7.8	39	55	Papilloedema (Both eyes)
15	57	F	ALL L2	9.3	19	84	Intraretinal Hemorrhage Cotton Wool Exudate (both eyes)
16	42	M	ALL L3	8.8	16	62	Cotton Wool Exudates, Macular Hemorrhage (Both eyes)

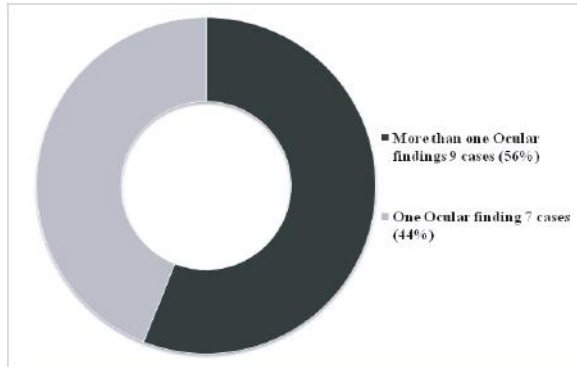


Fig 2 : Frequency of multiple Ocular findings in Acute Leukemia

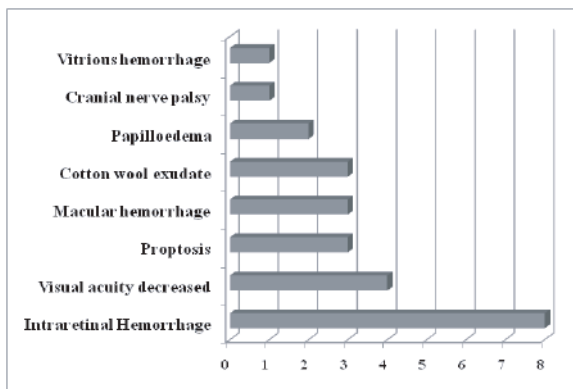
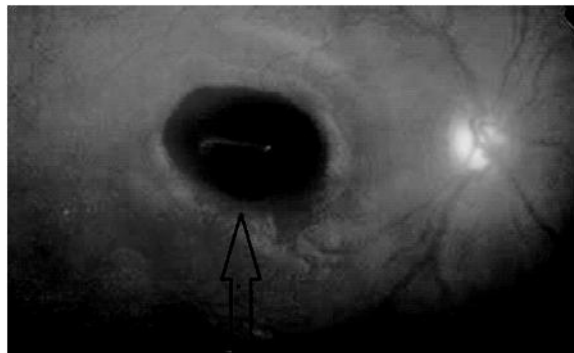


Fig 3 : Types and number of cases of ocular involvement in acute leukemia patients



Picture 1 : Intraretinal Hemorrhage in a case of Acute Leukemia (Ophthalmoscopic Examination)

Discussion

Orbital and ocular manifestations in acute leukemia is of different types. Orbital infiltration presents with proptosis, lid edema and chemosis [1,2]. Biopsy may be necessary, especially when the underlying systemic disease presents first in the orbit and is otherwise unsuspected [3]. This may appear before, after or concurrently with

hematological manifestations of leukemia. The orbital mass of cells formed in myeloid leukemia has been called granulocytic sarcoma. It is also known as chloroma due to its greenish appearance on gross examination [7]. This may occur as the terminal event of disease and has been associated with a poor prognosis. The retina shows leukemic involvement clinically more often than any other ocular tissue [2,3]. Tortuous dilated retinal vessels due to development of hyperviscous state, perivascular sheathing and cotton wool spots due to collections of leukemic cells, hemorrhages in the retina have been reported in leukemic patients. The hemorrhages are mostly flame shaped [4,6]. Vitrious hemorrhages are also found.

Robb et al. (2000) showed no correlation between retinal hemorrhage and blood profile in acute leukaemia, but it was found that an increased white cell level predisposed to leukaemic retinal infiltration [5]. Some of the hemorrhages may have a white center which may be due to accumulation of leukemic cells. Eye symptoms and signs include blurring of vision, diplopia, extraocular muscle palsies due to involvement of cranial nerves, and papilloedema secondary to raised ICP [8,9]. Neuro-ophthalmic signs were noted in one case of lymphoblastic leukemia (No. 9) at presentation. In our study 16 out of 60 cases (26%) showed one or more ocular lesions in acute leukaemia. However, only 3 patients presented with eye symptoms (5%) and the rest did not have any eye symptoms. The ocular lesions were detected on routine examination of eyes by the ophthalmologist.

Conclusion

Since patients often do not complain of visual symptoms, and in view of the high prevalence of asymptomatic ocular lesions we suggest that ophthalmic examination should be included as a part of the routine evaluation at the time of diagnosis in all patients with acute leukemia. This will help in early diagnosis, and to predict the prognosis of acute leukemia cases.

Disclosure

All the authors declared no competing interest.

References

1. Gordon KB, Rugo HS, Duncan JL, Irvine AR, Howes EL, O'Brein JM, et al. Ocular Manifestations of leukemia: Leukemic infiltration versus infectious process. *Ophthalmology*. 2001;108:2293–300.
2. Reddy SC, Jackson N, Menon BS. Ocular involvement in Leukemia: A study of 288 cases. *Ophthalmologica*. 2003;217:441–445.
3. Zimmerman LE & Font RL: Ophthalmologic manifestations of granulocytic sarcoma (myeloid sarcoma or chloroma). *Am J Ophthalmol*. 2004;80: 975–990.
4. Ohkoshi K & Tsiaras WG : Prognostic importance of ophthalmic manifestations in childhood leukaemia. *Br J Ophthalmol*. 2005;76: 651–655.
5. Robb RM, Ervin LD & Sallen SE : A pathological study of eye involvement in acute leukaemia of childhood. *Trans Am Ophthalmol Soc*. 2000; 76: 90–101
6. Rahman MJ. Clinical presentation and Morphological variants of childhood leukaemia in Bangladesh. *Bang. Paed*. 2001; 6: 22 – 24.
7. Faiz MA, Das KK, Kasem A, et al. The pattern of haematological Malignancies in adults in Dhaka, Bangladesh. *Bang. J. Med*. 1999; 1: 9 – 12.
8. Moula QM, Hossain A, Yunus EB & Mannan MA. Childhood leukaemia: A study of 93 cases. *Bang. J. ch. Health*. 1999; 12: 21 – 24.
9. Charif-Chefchaoui M, Belmeki M, Hajji Z, Tahiri H, Amrani R, Bakkali M, et al. Ophthalmic manifestations of acute leukemia. *J Fr Ophtalmol*. 2008;25:62–65.