

PLEURAL EFFUSION: A RARE COMPLICATION OF HEPATITIS A INFECTION IN CHILDREN

Sanat Kumar Barua^{1*} Basana Rani Muhuri¹ Pranab Kumar Chowdhury²
 Mohammad Shameem Hasan² Abdur Razzak Sikder³

Summary

Hepatitis A virus is a very common infection in the pediatric age group, especially in developing countries and pleural effusion is one of its rare extra-hepatic complications. Here we are reporting a case of acute hepatitis A infection, complicated with pleural effusion.

Key words

Hepatitis A; Pleural effusion; Children.

Introduction

Hepatitis A Virus (HAV) infection occurs throughout the world but is most common in developing countries [1]. In these countries with high endemicity, 90% of the population is infected by 10 years of age which are mostly asymptomatic [2]. However, its clinical presentation may occur over a large spectrum from non-icteric to a fulminating hepatic failure form. After 2-6 weeks of incubation period, weakness, loss of appetite and nausea appear early, jaundice and darkness in urine color usually added later on as clinical findings. Clinical recovery occurred first, followed by biochemical and histopathological recovery. Complete recovery is achieved over 6-12 months [3]. Complications of hepatitis A infection are as follows: fulminant hepatic failure (0.1%), cholestatic hepatitis, Guillain Barre syndrome and pleural effusion [3-5]. The pleural effusion is a rare and benign complication of hepatitis A, and its appearance doesn't seem to correlate with seriousness of illness in children and resolves spontaneously regardless of illness [3]. To the best of our knowledge, the first case was reported

in 1971 and thereafter, only ten cases of pleural effusion associated with HAV have been reported previously [5,6]. In this article, we present a case of HAV complicated by pleural effusion.

Case Report

A 22 months old male child of non-consanguineous family was admitted to a clinic in Chittagong with a history of anorexia, vomiting, fever and cough for 7 days and yellowish coloration of sclera and urine for 2 days. He had been previously well, and was immunized with three doses of Pentavalent, three doses of Oral Polio Vaccine (OPV) along with Measles and Rubella (MR) vaccine and no history of taking hepatitis-A vaccine. The patient came from a middle class family and had no history of similar illness in the family within last six weeks. On physical examination, the boy was ill-looking, temperature was 101.5°F, and heart rate was 104/min, respiratory rate 55/min, and moderate jaundice of skin and sclera was present. The abdomen was mildly distended. The liver was palpable 3 cm below the costal margin in right mid-clavicular line and tenderness was present. The spleen was not palpable. No ascites was present. Breath sound had decreased predominantly at the base of right lung. All other physical examination findings were normal.

On admission, the laboratory studies showed WBC count 13,000/cmm, with 58% lymphocyte, haemoglobin 11g/dl, ESR 10 mm in first hour. Rapid test for malaria, Immunochromatography for Salmonella and dengue IgM (On 7 day of fever) were negative. The blood urea nitrogen, Serum creatinine and electrolytes were normal. Serum SGPT (ALT) and serum alkaline phosphatase were 231 U/L and 656 U/L respectively, total bilirubin 7 mg/dl, and conjugated bilirubin 3.5 mg/dl. Total protein was 6 g/dl and albumin was 2.6 g/dl. Prothrombin time was 28 seconds (Control- 13 seconds, ratio-2.15 and INR-2.1). The result of urine analysis showed

1. Associate Professor of Pediatric Nephrology
Chittagong Medical College, Chittagong.

2. Associate Professor of Pediatrics
Chittagong Medical College, Chittagong.

3. Consultant of Pediatrics, Chittagong.

*Correspondence: Dr. Sanat Kumar Barua
 Email: sanat.barua@yahoo.com
 Cell: 01819-819106

albumin (+), pus cells 3-5/ HPF, and urine bilirubin was not done. Anti HAV IgM antibodies was detected (Cut off value= 0.157, sample rate= 0.801). Hepatitis B virus surface antigen and anti hepatitis C virus were negative. Chest radiograph showed right sided pleural effusion (Fig 1). Abdominal ultrasound revealed mild hepatomegaly with normal parenchyma echogenicity, no ascites but right sided pleural effusion. The boy was treated symptomatically and chest X-ray on the tenth day of hospitalization demonstrated the pleural effusion was resolved completely (Fig 2).

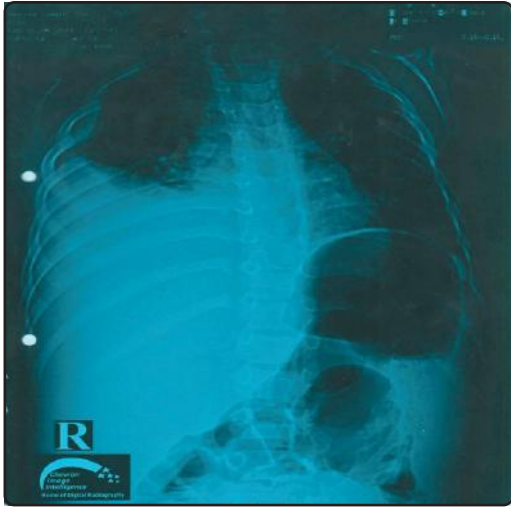

Fig 1 : Pleural effusion (Right side)

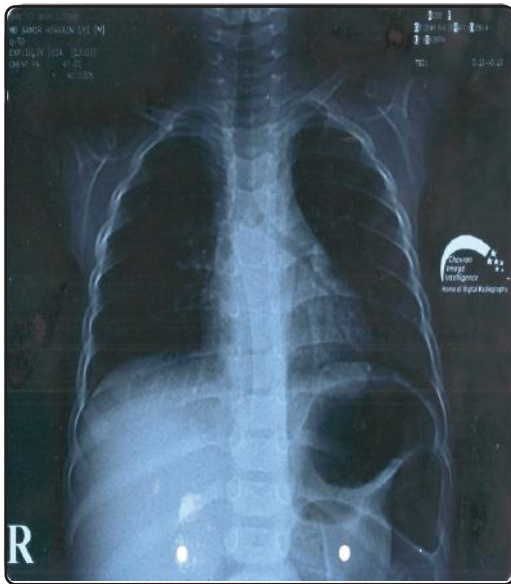


Fig 2 : Resolved pleural effusion spontaneously after 10 days

Discussion

Though common presentation of hepatitis A in children are fever, vomiting and jaundice, atypical manifestations such as ascites, splenomegaly and liver cell failure have been noted in older children [7]. Several extra hepatic complications have been described in children with hepatitis A, however, Pleural effusion due to hepatitis A infection is a rare complication during childhood. The pathogenesis of pleural effusion is not known though immune complexes as well as infectious inflammation of the hepatic parenchyma have been suggested as likely mechanisms [8]. The pleural effusion in these patients is usually a transudate and requires no tapping. However in an adult with hepatitis A, eosinophilic pleural effusion two weeks following recovery from viral hepatitis has been reported that resolve spontaneously, however in all children with pleural effusion; it is found early in course of disease and resolve on its own as was seen also in this patient where child had icteric hepatitis and pleural effusion resolved spontaneously [9,7].

The elevation of alkaline phosphatase in this case, can also be present in acute hepatitis due to cholestasis. Hypoalbuminemia may also lead to pleural effusion but it would be associated with edema and ascites. In this child, serum albumin was lower limit of normal and there was no associated ascites, thus hypoalbuminemia as a cause of pleural effusion seems unlikely in this child. Similarly, dengue can lead to hepatitis like illness and plasma leak causing pleural effusion and ascites [10]. However it is usually associated with thrombocytopenia and haemoconcentration. In the present case, platelet count was normal, and dengue IgM was negative, thus it was unlikely to be dengue related pleural effusion.

Conclusion

With this case, we want to emphasize that even though pleural effusion is rarely seen during the course of hepatitis A, it should be considered in differential diagnosis in the patients who are admitted for pleural effusions. Pleural effusion accompanying hepatitis A infection tends to resolve spontaneously.

Disclosure

All the authors declared no competing interest.

References

1. Pickering LK, Synder JD. Viral hepatitis. In: Kliegman RM, Berhman RE, Lenson HB, Stanton BF, editors. Nelson Textbook of pediatrics. saunders Elsevier. New delhi. 2004; 17:1324-32.
2. Mahmud S, Karim B ASM, Alam J, Saha SK, Ahmed SS, Begum JA . Age specific prevalence of antibodies to Hepatitis A virus among Bangladeshi children. DS(Child) H J. 2012; 28 (1): 31-34.
3. Akarsu S, Yilmaz E, Poyrazoglu G. Pleural effusion associated with hepatitis A. J Pediatr Inf. 2008; 2: 25-26.
4. Emre A, Dincer Y, Hancer Y, aksaray N. pleural effusion associated with acute hepatitis A infection. Ped Inf Dis. 1999; 18: 1111-1112.
5. Azuri J, Lerman-sagie T, Mizarahi A, Bujanover Y. Guillian Barre syndrome following serological evidence of hepatitis a in a child. Eur j Pediatr. 1999; 158: 341-342.
6. Gross PA, Gerding DN. Pleural effusion associated with viral hepatitis. Gastroenterology. 1971; 117: 224-225.
7. Bukulmez A, Koken R, Melek H, Dogru O, Ovali F. Pleural effusion: A rare complication of hepatitis A. Indian J Med Microbiol 2008; 26: 87-88.
8. Kamanth SR, Sathiyasekaran M, Raja TE, Sudha L. Profile of viral hepatitis a in Chennai. Indian Pediatr. 2009; 46: 642-643.
9. Simmons WW, Warren RE. Eosinophilic pleural effusion associated with recovery from viral hepatitis A. J Clin Gastroenterol 1994; 19: 143-145.
10. Giri S, agarwa MP, Sharma V, Singh A. Acute hepatic failure due to dengue: A case report. Cases J. 2008; 1: 204.