

## ATYPICAL FEATURES OF CHIKUNGUNYA INFECTION

Pradip Kumar Dutta<sup>1\*</sup> Arup Dutta<sup>2</sup> Md Mamunur Rashid<sup>3</sup> Sudipa Dutta<sup>4</sup>

### Abstract

Typical chikungunya virus (CHIKV) infection results in an acute febrile illness characterized by fever, severe joint pain and rash. Although chikungunya is generally not considered life threatening, atypical clinical manifestations resulting in significant morbidity have been documented, especially during epidemics. Our review is intended to elicit clinicians awareness of the atypical and severe forms of the disease in our region, as a way to potentially improve the outcomes of such life-threatening conditions.

### Key words

Chikungunya; Atypical features; Genotype; Biomarkers and encephalitis.

### Introduction

Chikungunya virus (CHIKV) an arbovirus belonging to the family *Togaviridae*, genus *Alphavirus*, was first isolated in Tanzania in 1953<sup>1</sup>. It has a 12,000-nucleotides linear, positive-sense, single-stranded RNA genome containing two large Open Reading Frames (ORF). The first, ORF1, encodes 4 non-structural proteins (nsP1, nsP2, nsP3 and nsP4) while ORF2 encodes structural proteins that include 1 capsid protein (C) 2 major envelope surface glycoproteins (E1, E2) and 2 small proteins (E3, 6K)<sup>2,3</sup>. Chikungunya fever (CHIKF) is an acute self limiting illness with abrupt fever, skin rash, headache, myalgia, arthralgia, arthritis and tenosynovitis<sup>4</sup>. Although unlike dengue it causes causality but occasional involvement of the nervous system, heart, kidney

and liver leads to significant worse prognosis<sup>5</sup>. CHIKF is now one of emerging virus infections in Southeast Asia<sup>6</sup>. Atypical manifestations of CHIKV infection especially in immunocompromised patients may cause a major threat if we don't think of it especially during epidemics<sup>7</sup>.

Three genotypes of Chikungunya virus (CHIKV) called West African, East/Central/South African (ECSA) and Asian have been defined. Atypical and lethal cases of CHIKF have been almost exclusively associated with infections by the ECSA genotype. But Asian strain was also found to be associated with atypical manifestation in venezulean outbreak in 2013-2015<sup>8</sup>.

### Search Strategy

A literature search was performed in pubmed using the search words "Chikungunya AND Atypical features, Chikungunya AND Encephalitis, Chikungunya AND Biomarkers." Internet resources assessed were "National Guideline for Clinical Management of Chikungunya 2016, Director General of Health Service, Ministry of Health and Family Welfare, Govt of India." and "WHO Chikungunya fact sheet updated April 2017".

### Atypical Manifestations

An atypical case is one in which a patient with laboratory-confirmed Chikungunya virus infection developed symptoms other than fever and arthralgia. A severe atypical case is one which required maintenance of at least one vital function<sup>9</sup>.

Atypical clinical manifestations can be due to the direct effects of the virus, immunologic response to the virus, drug toxicity, or diseases unrelated to chikungunya virus infection. Some atypical feature are more common in certain groups like age >65 years, diabetic and hypertensive patients. For example, vesiculobullous lesions, febrile seizures, and meningo-encephalitis have been reported in infants and young children<sup>10</sup>.

1. Professor of Nephrology  
Chittagong Medical College, Chittagong.

2. Associate Professor of Paediatrics  
Chittagong Medical College, Chittagong.

3. Student of MD (Nephrology-Third Part)  
Chittagong Medical College, Chittagong.

4. Honorary Medical Officer (Medicine Unit)  
Dhaka Medical College Hospital, Dhaka.

\*Correspondence: Dr. Pradip Kumar Dutta  
E-mail: [duttaprd@gmail.com](mailto:duttaprd@gmail.com)  
Cell : 01819 314623

Received on : 11.08.2017

Accepted on : 13.08.2017

### Atypical Clinical Manifestations<sup>10</sup>.

#### Neurological

Meningoencephalitis, Encephalopathy, Seizures, Guillain-Barré syndrome, Cerebellar syndrome, Paresis, Palsies, Optic neuritis, Iridocyclitis, Episcleritis, Retinitis, Uveitis.

#### Cardiovascular

Myocarditis, Pericarditis, Heart failure, Arrhythmias, Hemodynamic instability.

#### Dermatological

Photosensitive hyperpigmentation, Intertriginousaphthous-like ulcers, Vesiculobullousdermatosis.

#### Renal

Nephritis, Acute Renal Failure.

#### Miscellaneous

Bleeding dyscrasias, Pneumonia, Respiratory failure, Hepatitis, Pancreatitis, Syndrome of Inappropriate Secretion of Antidiuretic Hormone (SIADH) Hypoadrenalism.

### Reported Series of Atypical Manifestations of CHIKF

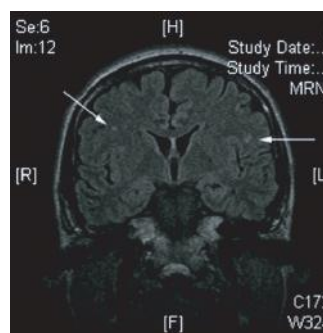
First detection of atypical cases were done In April 2005 during an outbreak of Chikungunya fever on the island of Réunion in the Indian Ocean<sup>9</sup>. They found patients with meningoencephalitis and acute hepatitis due to Chikungunya virus.

They recorded 610 atypical cases of Chikungunya fever 222 were severe cases, 65 affected patients died. Five hundred and forty-six cases had underlying medical conditions (of which 226 suffered from cardiovascular, 147 from neurological and 150 from respiratory disorders). Clinical features that had never been associated with Chikungunya fever were recorded, such as bullous dermatosis, pneumonia, and diabetes mellitus. Hypertension, and underlying respiratory or cardiological conditions were independent risk factors for disease severity. The overall mortality rate was 10.6% and it increased with age. This is the first time that severe cases and deaths due to Chikungunya fever have been documented.

CHIKV infection may on rare occasions in immunocompromised patients are reported to be associated with peritonitis, encephalitis, and secondary bacterial infections. In Singapore in 2008

two immunocompromised patients were reported to have atypical features of Chikungunya<sup>7</sup>. One of them was a patient of Chronic renal failure presented with abdominal pain, vomiting, and fever for 1 day but no joint symptoms but clinical features of systemic inflammatory response syndrome. His blood count showed leukocytosis with neutrophilia (rather than lymphopenia) and thrombocytopenia (like Dengue fever). Initial blood and urine cultures and serologic results were negative for dengue virus, but serum reverse transcription-PCR (RT-PCR) and indirect immunofluorescent assay for immunoglobulin G (IgG) and IgM were positive for CHIKV<sup>3,11</sup>. Interestingly his Computed tomographic scans of the abdomen showed dilated small bowel loops. An urgent laparotomy and peritoneal cultures yielded Klebsiella, Pneumoniae, Escherichia coli and Candida glabrata, and RT-PCR from the concentrated peritoneal fluid was positive for CHIKV<sup>3</sup>. The peritonitis may be due to secondary infection rather as patient responded to antibiotics. Another patient with diabetes mellitus with a cadaveric liver transplant for hepatitis B liver cirrhosis and receiving immunosuppressants (Azathioprine and Prednisolone) experienced fever, headache, and abdominal bloating but no joint manifestation. Results of serum RT-PCR were negative for CHIKV, but IgG and IgM tests were positive for CHIKV. Brain magnetic resonance imaging showed bilateral frontoparietal white matter lesions with restricted diffusion suggesting early sign of viral encephalitis (Fig 1).

However, in a retrospective series only 5 patients out of 30 patients with neurological features demonstrated abnormalities on magnetic resonance imaging<sup>12,13</sup>.



**Fig 1 :** Magnetic Resonance Imaging (MRI) of the brain of the patient, showing several nonspecific areas of enhancement (Arrows) which suggests encephalitis, given the clinical scenario

Another series reported that 6 patients with CHIKV infection had perforated jejunal diverticula while receiving long-term nonsteroidal antiinflammatory drugs and steroids. The perforations were likely secondary to prolonged steroid use rather than CHIKV infection. Whether these infections were linked to CHIKV infection or to the underlying chronic immunosuppressed state was unclear<sup>14</sup>.

#### **ARF in Chikungunya<sup>15</sup>**

In Al- Hodeida Governorate, Yemen, an outbreak of CHIKV with severe presentation including acute renal failure was reported characterized by fever, severe arthralgia, headache and rash in early 2011. After surveillance Sera was collected and tested for CHIK and dengue viruses from these patients. Out of 5773 suspected CHIK cases, 220 (4%) had Acute Renal Failure (ARF). Of these, 78 (35%) were admitted to renal dialysis center, and 59 (27%) died. There were more males 132 (60%) than females and most patients were 21-40 years of age 86 (39%). Clinical features and laboratory results reported included fever 99%, headache 92%, arthralgia 82 %, higher level of serum creatinine 100%, lower level of platelets 73%, high levels of WBC 78%, and 70% neutrophil . Out of 7 blood sera tested, 5 (71%) were positive for CHIK virus by rT-PCR, 2 (29%) were positive for dengue by IgM ELISA, 7(100%) were positive for dengue by IgG. More suspected CHIK cases presented with severe symptoms including renal failure and death. Infection and co-infection with other viral diseases especially dengue fever may have contributed to severe presentation of CHIKV.

#### **Atypical Cases in Western Hemisphere<sup>8</sup>**

Chikungunya fever in the Western hemisphere were associated with atypical and severe manifestations. Some patients experience a life-threatening, aggressive clinical course, with rapid deterioration and death due to multisystem failure. A large epidemic of Chikungunya fever affected the Caribbean, Central and South America in 2013-2015. In a series four Venezuelan patients with a severe and/or lethal course who exhibit unusual manifestations of the disease were described.

First case was a 75 year-old man with rapid onset of septic shock and multi-organ failure. 2<sup>nd</sup> and 3<sup>rd</sup> cases were two patients with rapid aggressive clinical course who developed shock, severe purpuric lesions and a distinct area of necrosis in the nasal region. Last case was a splenectomized woman with shock, generalized purpuric lesions, bullous dermatosis and acronecrosis of an upper limb. In this series necrotic Cutaneous nasal lesion is unique which was not found in other series.

#### **Miscellaneous Case Reports**

Ramos R et al described a case where the infant born of a mother with CHIKV infection presented with severe encephalitis that evolved with postnatal-onset microcephaly, bilateral optic atrophy, epilepsy and cerebral palsy<sup>16</sup>.

Lucena-Silva N et al reported a case of encephalitis caused by CHIKV infection associated with an atypical presentation of syndrome of inappropriate antidiuretic hormone secretion, evolving to cognitive impairment and apraxia of speech<sup>17</sup>.

Guri LA and others reported a case of post chikungunya reversible demyelinating encephalitis with vertigo, dysarthria and ataxia who responded with complete clinical and radiological improvement with steroids<sup>18</sup>.

A Case of Diabetic Ketoacidosis Following Chikungunya Virus Infection was reported by Tolokh in Puerto Rico<sup>19</sup>.

#### **Biomarkers of Atypical Manifestations of CHIKV Infection**

Biomarkers are not studied prospectively in immunocompromised patients. In one series profiles of 30 cytokines, chemokines, and growth factors were able to discriminate the clinical forms of Chikungunya from healthy controls, with patients classified as non-severe and severe disease. Levels of 8 plasma cytokines (IL-2R, IL-5, IL-6, IL-7, IL-8, IL-10, IL-15 and IFN- $\alpha$  ) and 4 growth factors (HGF, FGF-basic, VEGF and EGF) were significantly elevated. Statistical analysis showed that an increase in IL-1 $\beta$ , IL-6 and a decrease in RANTES (Regulated on activation, normal T cell expressed and secreted) were associated with disease severity<sup>5</sup>.

#### **Novel Therapies of Atypical Infection**

At present, no drug or vaccine is available for the treatment and therapy of CHIKV infections, but the non-structural protein, nsP3, is a potential target for the design of potent inhibitors that fit at

the adenosine-binding site of its macro domain. It provides useful information to further assist in drug design and development for this virus<sup>20</sup>. Another interesting feature is the discovery of silico-lead compound targeting nsP3 micro domains<sup>21</sup>.

Steroid was tried in some Indian cases of encephalitis with some success<sup>18</sup>. Immunoglobulin was tried in Bazalian cases<sup>22</sup>.

### Conclusion

Although most cases of CHIKV infection are self-limiting, clinicians should be alert to atypical presentations and severe complications in immunosuppressed patients especially during epidemic. Early detection to allow timely cases management will improve outcome. Since many atypical and severe clinical manifestations will be unrelated to chikungunya virus infection, healthcare providers should consider and evaluate for other etiologies as well. Genotyping of the CHIKV may explain the severity. Further molecular studies will hopefully discover antiviral drug.

### Disclosure

All the authors declared no competing interests.

### References

1. Robinson MC An epidemic of virus disease in Southern Province, Tanganyika Territory, in 1952–53. Clinical features. *Trans R Soc Trop Med Hyg.* 1955;49:28–32.
2. Pialoux G, Gaüzère BA, Jauréguiberry S, Strobel M. Chikungunya, an epidemic arbovirolosis. *Lancet Infect Dis.* 2007;7(5):319-327.
3. Leo YS, Chow AL, Tan LK, Lye DC, Lin L, Ng LC. Chikungunya outbreak, Singapore. 2008. *Emerg Infect Dis.* 2009;15:836–837.
4. Lemant J, Boisson V, Winer A, Thibault L, André H, Tixier F et al. Serious acute chikungunya virus infection requiring intensive care during the Reunion Island outbreak in 2005–2006. *Crit Care Med.* 2008;36:2536–2541.
5. Ng LF, Chow A, Sun YJ, Kwek DJ, Lim PL, Dimatatac F et al. IL-1beta, IL-6, and RANTES as biomarkers of chikungunya severity. *PLoS ONE.* 2009;4:e4261.
6. World Health Organisation Chikungunya in South-East Asia-Update, New Delhi: Regional Office for South-East Asia 2008. Outbreak and spread of Chikungunya. *Weekly Epidemiological Record.* 2007; 82 (47): 409-415.
7. Adrian C.L. Kee, Samantha Yang, and Paul Tambyah. Atypical Chikungunya Virus Infections in Immunocompromised Patients. *Emerg Infect Dis.* 2010; 16(6): 1038–1040.
8. Jaime R. Torres, Leopoldo Códova G, Julio S. Castro, Libsen Rodríguez, Víctor Saravia, Joanne Arvelaez, Antonio Ríos-Fabra, María A. Longhi, and Melania Marcano. Chikungunya fever: Atypical and lethal cases in the Western hemisphere. A Venezuelan experience. *IDCases.* 2015; 2(1): 6–10. Published online 2014 Dec 18. doi: 10.1016/j.idcr.2014.12.002.
9. Economopoulou A, Dominguez M, Helynck B, Sissoko D, Wichmann O, Quenel P, Germonneau P. Atypical Chikungunya virus infections: Clinical manifestations, mortality and risk factors for severe disease during the 2005-2006 outbreak on Réunion. *Epidemiol Infect.* 2009;137(4):534-541.
10. Rajapakse S, Rodrigo C, Rajapakse A. Atypical manifestations of Chikungunya infection. *Trans R Soc Trop Med Hyg.* 2010; 104(2):89-96.
11. Thein S, La Linn M, Aaskov J, Aung MM, Aye M, Zaw A et al. Development of a simple indirect enzyme-linked immunosorbent assay for the detection of immunoglobulin M antibody in serum from patients following an outbreak of chikungunya virus infection in Yangon, Myanmar. *Trans R Soc Trop Med Hyg.* 1992;86:438–442.
12. Ganesan K, Diwan A, Shankar SK, Desai SB, Sainani GS, Katrak SM. Chikungunya encephalomyeloradiculitis: Report of 2 cases with neuroimaging and 1 case with autopsy findings. *AJNR Am J Neuroradiol.* 2008;29:1636–1637.
13. Robin S, Ramful D, Le Seach F, Jaffar-Bandjee MC, Rigou G, Alessandri JL. Neurologic manifestations of pediatric chikungunya infection. *J Child Neurol.* 2008;23:1028–1035.
14. Palanivelu C, Rangarajan M, Rajapandian S, Maheshkumaar GS, Madankumar MV. Perforation of jejunal diverticula in steroids and nonsteroidal anti-inflammatory drug abusers: A case series. *World J Surg.* 2008;32:1420–1424.
15. Presenter (s): Dr. Ali Bin break Conference: Eastern Mediterranean, Egypt. 2011.

- 16.** Ramos R, Viana R, Brainer-Lima A, Florêncio T, Carvalho MD, van Der Linden V, Amorim A, Rocha MÂ, Medeiros F. Perinatal Chikungunya Virus-Associated Encephalitis Leading to Postnatal-Onset Microcephaly and Optic Atrophy. *Pediatr Infect Dis J.* 2017. doi: 10.1097/INF.0000000000001690. [Epub ahead of print].
- 17.** Lucena-Silva N, Assunção MELSM, Ramos FAP, Azevedo F, Lessa R Junior, Cordeiro MT, Brito CAA. Encephalitis associated with inappropriate antidiuretic hormone secretion due to chikungunya infection in Recife, State of Pernambuco, Brazil. *Rev Soc Bras Med Trop.* 2017;50(3):417-422.
- 18.** Gauri LA, Ranwa BL, Nagar K, Vyas A, Fatima Q. Post chikungunya brain stem encephalitis. *J Assoc Physicians India.* 2012;60:68-69.
- 19.** Tolokh I, Laux T, Kim D. A Case of Diabetic Ketoacidosis Following Chikungunya Virus Infection. *Am J Trop Med Hyg.* 2015;93(2):401-403. doi: 10.4269/ajtmh.14-0840. Epub 2015 Jun 1.
- 20.** Rungrotmongkol T, Nunthaboot N, Malaisree M, Kaiyawet N, Yotmanee P, Meeprasert A, Hannongbua S. Molecular insight into the specific binding of ADP-ribose to the nsP3 macro domains of chikungunya and Venezuelan equine encephalitis viruses: Molecular dynamics simulations and free energy calculations. *J Mol Graph Model.* 2010;29(3):347-353.
- 21.** Nguyen PT, Yu H, Keller PA. Discovery of in silico hits targeting the nsP3 macro domain of chikungunya virus. *J Mol Model.* 2014;20(5):2216.
- 22.** Scott SSO, Braga-Neto P, Pereira LP, Nóbrega PR, de Assis Aquino Gondim F, Sobreira-Neto MA, Schiavon CCM. Immunoglobulin-responsive chikungunya encephalitis: Two case reports. *J Neurovirol.* 2017. doi: 10.1007/s13365-017-0535-y. [Epub ahead of print].