

GLAUCOMATOCYCLITIC CRISIS - AN ELUSIVE DISEASE: OUR EXPERIENCE IN MANAGEMENT AND OUTCOMES

S M Masud Parvez^{1*} Shams Mohammed Noman²

Abstract

Background: The purpose of the current study is to describe clinical manifestations, management and its outcome of patients who were diagnosed as glaucomatocyclitic crisis at the Glaucoma Department Chittagong Eye Infirmary and Training Complex (CEITC) Chattogram and Eye Department, Chittagong Medical College.

Materials and methods: It is a hospital based observational case series study. Study period was from 1st July 2010-to 30th June 2012. Unilateral ocular hypertension cases of unexplained origin referred to glaucoma clinic from outpatient department of CEITC and Eye Department, Chittagong Medical College Hospital (CMCH) were included in this study. Detail history taking and ocular examinations were done that included slit lamp biomicroscopy, applanation tonometry, gonioscopy, funduscopy and visual field analysis. Glaucomatocyclitic Crisis (GCC) was diagnosed according to mentioned criteria. Management detail was recorded. Patients were followed up after one week, 1 month, 3 months of initial visit. Examination and investigation findings were documented as much as possible. Sample size was 45.

Results: A total numbers of 45 patients with GCC were included. For the better understanding the results, the total patients (N=45) were categorized into 2 age groups that are 20-49 and 50+. Percentage of patients into these groups are 51.1% (n=23) and 48.9% (n=22) respectively. In total 45 patients, 37 were male and 8 were female. 53.3% patients (n=24) presented with decreased visions, 15.6% patients (n=7) with both pain and occasional redness, 13.3% patients (n=6) with mild

discomfort, 11.1% patients (n=5) with recurrent redness, 8.9% patients (n=4) with occasional halos, 4.4% patients (n=2) with occasional eye ache and 2.2% patient (n=1) with loss of vision. Mean IOP of affected eyes was 30mm hg before treatment and 15mm hg after treatment. Angles were open in all cases. At presentation 81.2% patients (n=37) presented with glaucomatous optic disc C:D ratio(0.8-1):1. 77.77% patients(n=35) needed flumetholone, 4.44% cases (n=2) needed dexamethasone and 4.44% patients (n=2) needed prednisolone acetate topical eye drop to control inflammation. 13.33% patients (n=6) were not treated with any steroid as they resolved spontaneously. 91% patients needed anti glaucoma medications 9% needed filtration surgery with **Ologen** implantation to control IOP.

Conclusion: Early diagnosis with meticulous examinations and investigations are needed to manage a GCC case. As it is an elusive disease, proper explanation of the disorder to the patient to get good compliance from them is necessary to achieve good medical treatment outcome. Good filtration surgery with Ologen implantation is still successful to control IOP. But regular careful monitoring to the patient is mandatory to perfectly manage and prevent the irreversible visual consequences of recurrence of the disease.

Key words

GCC (Glaucomatocyclitic Crisis); Inflammation; Open-angle; Trabeculectomy.

Introduction

Glaucomatocyclitic crisis, is an uncommon form of secondary open angle glaucoma. It is a condition with self-limited recurrent episodes of markedly elevated intraocular pressure (IOP) with mild idiopathic anterior chamber inflammation^{1,2}. In 1948, Posner and Schlossmann published a series of 9 patients and described the features of this syndrome as unilateral, recurrent episodes of mild non-granulomatous uveitis, with elevated IOP during the acute attack, which persists for a few hours

1. Associate Professor of Ophthalmology
Chittagong Medical college, Chattogram.
2. Senoir Consultant of Glaucoma Clinic
Chittagong Eye Infirmary and Training Complex (CEITC) Chattogram.

***Correspondence: Dr. S M Masud Parvez**
E-mail: drmasudparvez_eye@yahoo.com
Cell : 01842 33 16 28

Submitted on : 13.07.2020

Accepted on : 04.08.2020

to several weeks, corneal edema with a few keratic precipitates; heterochromia with anisocoria, open angles, normal visual fields and normal optic discs. In between the attacks, the IOP, outflow facility and provocative tests were within normal limits¹. Since this original description, other cases attributed to Posner schlossman syndrome have been found to deviate from these criteria³. Additional features that are now recognized are, this condition affects individuals aged 20-50 years; both eyes may be involved at different times but rarely simultaneously^{4,5,6}. The rise of IOP is out of proportion to the severity of the uveitis, and this rise in IOP precedes the less identifiable inflammatory reaction, often by several days. A significant number of patients with GCC develop glaucoma overtime⁴. Filtration surgery is needed to prevent damage from high IOP with frequent attacks. Anti-glaucoma agents and surgery do not prevent recurrences of GCC. In most of the cases, it remains undiagnosed or sometimes over-diagnosed. Few symptoms and signs which are self remitting, respond to steroid but the recurrent attack of high IOPs leads to glaucomatous damage. Loss of vision from glaucoma is an important factor in the management of these patients.

The aim of the current study is to describe and establish clinical manifestations and proper management of patients who were diagnosed as glaucomatocyclitic crisis. The study was conducted at the Glaucoma Department of Chittagong Eye Infirmary and Training Complex and Department of Ophthalmology, Chittagong Medical College.

Materials and methods

This is a hospital based observational case series study. A total number of 45 patients with GCC were included in the study. Study period: 1st July 2009 to 30th June 2011. In this period, old cases of previously diagnosed GCC and newly diagnosed cases were included. New cases were followed up for at least 3 visits (1 week, 1month, 3 months and/or 6 months). The following data were recorded: age of the patient at onset, gender, presenting complaints, mean IOP, visual acuity, grade of inflammation before and after treatment, optic disc appearance, medications, glaucoma surgery if needed and post operative follow up. Diagnosis of glaucomatocyclitic crisis was made by the following criteria (Inclusion criterion): mild anterior chamber inflammation with small

non-pigmented kps, open angle and absence of posterior synechiae. There was never any occurrence vitreous activity and cystoid macula edema. The attacks usually resolved by 2 to 3 weeks, sometimes spontaneously, and sometimes it was recurrent. Between attacks, the eyes were normal. IOPs were measured using Goldmann applanation tonometry. Patients were diagnosed as developing glaucoma from attacks of GCC as follows:

- i) The IOP in the affected eye was >21 mmHg.
- ii) The affected eye had glaucomatous optic disc and/or visual field changes.

Details of anterior segment with slit lamp biomicroscopy were examined. Optic disc examination was done by indirect ophthalmoscope with 90D and 78D lens.

Results

A total number of 45 patients with GCC were included during the study period. The mean age of the patients was 48 years. The age of the patients ranged from 20 years to 50 years and above. For better understanding of the results, the total patients (n=45) were categorized into 2 age-groups: 20 to 49 yrs and >50 yrs. Percentage of patients in these groups are 51.1% (n=23) and 48.9% (n=22) respectively. Of the total 45 patients, 37 were male and 8 were female. Numbers of male and female were almost equal in both age groups. 53.3% patients (n=24) presented with decreased vision, both pain and occasional redness were complaints of 15.6% patients (n=7) 13.3% patients (n=6) presented with mild discomfort. 11.1% patients (n=5) presented with recurrent redness, and 8.9% patients(n=4) with occasional halos. 4.4% patients (n=2) and 2.2% patient (n=1) presented with occasional redness and loss of vision respectively (Table I). Mean IOP of affected eye was 30 mmHg and 15 mmHg before and after treatment respectively.

Table I : Presenting complaints.

Complaints	Responses n=56	Percent of Cases
Pain	7	15.6%
Decrease Vision	24	53.3%
Occasional Redness	7	15.6%
Occasional Haloes	4	8.9%
Occasional eye ache	2	4.4%
Recurrent redness	5	11.1%
Discomfort	6	13.3%
Loss of vision	1	2.2%

Of the 45 patients, 42.2% (n=19) had VA of 6/6-6/18, 20% (n=9) had VA less than 6/18-6/60 and 37% patients(n=17) presented with VA less than 6/60 before treatment. After treatment 80% patients(n=36) had VA of 6/6-6/18, 13.3% (n=6) had VA <6/18-6/60 and 6.7% patients (n=3) had VA <6/60 (Table II).

Table II : Visual acuity of affected eye.

Visual acuity of affected eye before treatment		
VA	n	Percent
6/6-6/18	19	42.2
<6/18-6/60	9	20.0
<6/60	17	37.8
Total	45	100.0

Visual acuity of affected eye after treatment		
VA	n	Percent
6/6-6/18	36	80.0
<6/18-6/60	6	13.3
<6/60	3	6.7
Total	45	100.0

Mild anterior chamber reaction (That is cell 1+) was found in 80.39% (n=41) of patients and 7.84% (n=4) patients had cells 2+ in anterior chamber. At presentation 81.2% patients (n=37) presented with glaucomatous optic disc (C:D ratio 0.8-1), 13.4% presented (n=6) with C:D ratio 0.6 to 0.7. Only 4.4% patients (n=2) had C:D ratio between 0.3-0.4.

Intraocular pressure was controlled by medical treatment in 91% cases. 9% cases needed surgery. 31.1% (n=14) patients were treated with one anti-glaucoma medication (Timolol maleate 0.5%) and 68.9% (n=31) patients needed combination therapy (Timolol maleate and brimonidinetartrat 0.1%). 77.77% of patients (n=35) needed fluoro-methalone, 4.44% of cases(n=2) needed dexamethasone and 4.44% patients (n=2) were treated with prednisolone to control inflammation. 13.33% patients (n=6) were not treated with any steroid as they spontaneously resolved (Fig 1 and 2, Tables III).

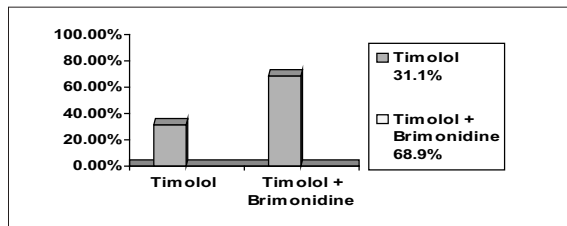


Fig 1 : Bar chart for different anti-glaucoma medications.

Table III : Anti-glaucoma medication therapy.

Medicine	n	%
Timolol	14	31.1%
Timolol + Brimonidine	31	68.9%
Total	45	100%

Topical steroid therapy

Medicine	n	%
Fluorometholone	35	77.77%
Dexamethasone	2	4.44%
Prednisolone	2	4.44%
No steroid	6	13.33%
Total	45	99.98%

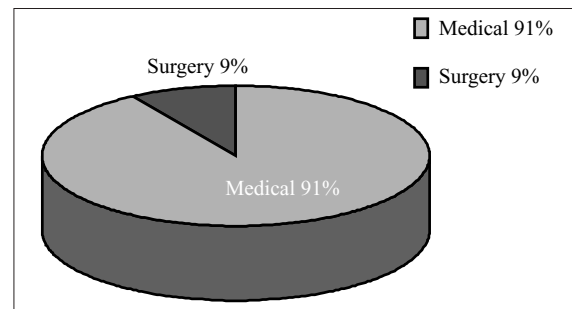


Fig 2 : Pie chart showing treatment modalities.

Discussion

Glaucomatocyclitic crisis is an uncommon form of secondary open angle glaucoma. Diagnosis of glaucomatocyclitic crisis is difficult and in most cases it is misdiagnosed as it mimics other ocular conditions⁷. Here we reported 45 cases of Glaucomatocyclitic crisis within two years. This indicates it is not so uncommon in Bangladesh. Glaucomatocyclitic crisis typically affects individuals aged 20–50 years^{8,9}.

In our study 51.1% patients were in the 20 to 49 yrs age group and 48.9% patients belonged to the above 50 years old age group. Thus, older patients should also be carefully monitored. Males were predominant in both age groups. 53.3% of patients came into hospital with the complaints of decrease vision.

As GCC is self remitting with minimal symptoms, repeated attacks are not noticed in most of the patients¹⁰. When vision decreased, patients then visited the hospital. Pain and redness were the second most common symptoms (15.6%). Some patients visited with typical features of GCC like discomfort, occasional halos, recurrent redness etc. Intraocular pressures in GCC are usually high ranging from 40 to 60 mmHg^{11,12}.

In our study, the mean IOP before treatment was 30 mmHg and after treatment IOP was controlled. Before treatment 37.8% patients visited with VA <6/60 and 42.2% with 6/6-6/18. After treatment 80% patients retain their vision within 6/6-6/18. Blurred vision in acute attacks is due to high IOP which induces corneal edema. After treatment 19.7% patients reported VA <6/18 visual acuity due to glaucomatous damage of the disc. 81.2% of patients presented with glaucomatous optic disc in which the cup disc ratio is 0.8 to 0.9. Thus, GCC is not always benign as previous thought to be described by Posner. The repeated attacks of high IOP causes permanent damage to the disc. In this observational case series study, every patient was asked to return earlier if they had an attack but all patients were not interested to come for every attack due to the self limiting and short lived nature of the disease, so it is difficult to determine the duration of elevated IOP during each episode and the numbers of attacks. So in this study we could not explore the possibility of duration of the attack and number of attacks as being factors responsible for causing glaucoma in these patients. The aim of medical treatment is to control inflammation and IOP elevation. The favored initial treatment is a combined regimen of a topical Non-steroidal Anti-Inflammatory Drug (NSAID) and an anti-glaucoma drug (Topical beta-blockers and/or carbonic anhydrase inhibitors). In our study, Fluorometholone was used to control inflammation in 77.77% patients. Timolol maleate was used as first line treatment for IOP control. Combination therapy was necessary in 68.9% patients. Topical carbonic anhydrase inhibitors were not given as it is costly and not available in all places in Bangladesh. Topical NSAIDs like Bromofenac was used in 11% patients. Surgical intervention was indicated when increase frequency of attacks and high fluctuation of IOP which may result in progressive optic nerve damage. 9% of cases needed filtration surgery (Trabeculectomy) due to IOP not being controlled by only medical treatment and also when patient had nerve damage. Post-operatively, IOP remained controlled after 1 week, 1 month and 3 months. However, again in a short period case series study, there may have been missed episodes of follow up. Both Medical and surgical treatment does not prevent recurrences but glaucoma filtration surgery is able to control high rise of IOP even during

the cyclitic attacks⁵. It may decrease the numbers of attacks⁵. Good functioning filtering bleb may decrease the inflammatory cells from the anterior chamber and ultimately prevent the bleb failure. Hence filtration surgery should be advised when any glaucomatous change has occurred. Because patients may miss follow ups, high spikes of IOP in every attack are not always noticed. The underlying cause of GCC still remains a debate. Cytomegalovirus seems to be the most likely infectious cause¹³. New insights into possible infectious etiologies of PSS may lead to the development of effective treatment strategies to prevent recurrence for this elusive disease. In our study we did not attempt to investigate causative factors.

Limitation

Number of case is small, inclusion centre need to be increased.

Conclusion

Glaucomatocyclitic crisis is an uncommon but not rare disease. Early diagnosis with meticulous examination and investigations are needed. Proper explanation of the disorder to the patient to get good compliance is necessary to achieve good treatment outcomes as it is an elusive disease (since the course of disease is not well understood). Good filtration surgery is still successful to control IOP but regular careful monitoring of the patient is mandatory to perfectly manage and prevent the irreversible visual consequences of recurrent attacks.

Recommendations

Further study with larger number of cases are recommended.

Acknowledgement

All the patients and their family members for kind cooperation. Doctors, nurses and other support staffs of Eye Department of CMCH and Glaucoma clinic of CEITC.

Contribution of authors

SMMP-Conception, design, acquisition of data, critical revision and final approval.

SMN- Acquisition of data, data analysis, interpretation of data, manuscript writing and final approval.

Disclosure

Both the authors declared no competing interests.

References

1. Posner A, Schlossman A. Syndrome of unilateral recurrent attacks of glaucoma with cyclitic symptoms. *Arch Ophthalmol.* 1948;39:517–535.
2. Raitta C, Vannas A. Glaucomatocyclitic crisis. *Arch Ophthalmol.* 1977;95:608–612.
3. Kass MA, Becker B, Kolker AE. Glaucomatocyclitic crisis and primary open-angle glaucoma [case report]. *Am J Ophthalmol.* 1973;75:668–673.
4. Hung PT, Chang JM. Treatment of glaucomatocyclitic crises. *Am J Ophthalmol.* 1974;77:169–172.
5. Caprioli J. Automated perimetry in glaucoma. In: Walsh TJ, ed. *Visual Fields: Examination and Interpretation.* San Francisco: American Academy of Ophthalmology. Ophthalmology Monograph. 3. 1990;71-106.
6. Sommer A, Pollack I, Maumenee AE. Optic disc parameters and onset of glaucomatous field loss. II. Static screening criteria. *Arch Ophthalmol.* 1979;97:1449–1454.
7. Pederson JE, Anderson DR. The mode of progressive disc cupping in ocular hypertension and glaucoma. *Arch Ophthalmol.* 1980;98:490–495.
8. Zeyen TG, Caprioli J. Progression of disc and field damage in early glaucoma. *Arch Ophthalmol.* 1993;111:62–65.
9. Yamada N, Mills RP, Leen MM, et al. Probability maps of sequential Glaucoma-scope images help identify significant changes. *J Glaucoma.* 1997;6:279–287.
10. Weinreb RN. Adjusting the dose of 5-fluorouracil after filtration surgery to minimize side effects. *Ophthalmology.* 1987;94:564–570.
11. Stavrou P, Murray PI. Does trabeculectomy influence the course of uveitis? *Ocul Immunol Inflamm.* 1999;7:103–108.
12. Hill RA, Nguyen QH, Baerveldt G et al. Trabeculectomy and Molteno implantation for glaucomas associated with uveitis. *Ophthalmology.* 1993;100:903–908.
13. Hana L. Takusagawa, MD; Yao Liu, MD; Janey L. Wiggs, MD, PhD. Infectious theories. Theories of Posner-Schlossman Syndrome. 1998.