

COMPERATIVE STUDY OF LASER HAEMORRHOIDOPLASTY AND MILIGAN-MORGAN HAEMORRHOIDECTOMY IN 2ND AND 3RD DEGREE HAEMORRHOID

Md. Nur Hossain Bhuiyan^{1*} Pradip Kumar Nath² Emon Kalyen Shaha³ Hussain Ahmed Khan³

Abstract

Background : Arterial overflow in the superior hemorrhoidal arteries would lead to dilatation of the hemorrhoidal venous plexus, according to the “vascular” theory. Hemorrhoid laser procedure (LHP) is a new laser procedure for outpatient treatment of hemorrhoids in which hemorrhoidal arterial flow feeding the hemorrhoidal plexus is stopped by laser coagulation. Compare the hemorrhoid laser procedure with Miligan-Morgan open surgical procedure for outpatient treatment of symptomatic hemorrhoids.

Material and methods: This study was conducted at Chittagong Medical College Hospital (CMCH) and Private Hospital in Chittagong . Patients with symptomatic grade II or grade III hemorrhoids with minimal mucosal prolapse were eligible for the study: 30 patients treated with the laser hemorrhoidoplasty, and 30 patients—with Miligan-Morganhemorrhoidectomy. Operative time and postoperative pain with visual analog scale, were evaluated.

Results: A total number of 60 patients (33 men and 27 women, mean age 45 years) entered the trial. Significant differences between laser hemorrhoidoplasty and Miligan-Morgan surgical procedure were observed – i) Operative time ii) Early postoperative pain. There was a statistically significant difference between the two groups regarding peri-operative and the early postoperative period: 1 week, 2 weeks, 3 weeks and 1 month after respective procedure.

Conclusions: Laser hemorrhoidoplasty procedure is more preferred in comparison with conventional

open surgical hemorrhoidectomy. Postoperative pain is significantly lesser in laser procedure compared with surgical procedure

Key words

Haemorrhoid; Laser Haemorrhoidoplasty; Miligan-Morgan Haemorrhoidectomy.

Introduction

Haemorrhoidal disease is ranked first amongst diseases of the rectum and large intestine and the estimated worldwide prevalence ranges from 2.9% to 27.9%, of which more than 4% are symptomatic^{1,2}. Approximately, one third of these patients seek physicians for advice. Age distribution demonstrates a Gaussian distribution with a peak incidence between 45 and 65 years with subsequent decline after 65 years^{3,4}. Men are more frequently affected than women⁵. The anorectal vascular cushions along with the internal anal sphincter are essential in the maintenance of continence by providing soft tissue support and keeping the anal canal closed tightly. Hemorrhoids are considered to be due to the downward displacement suspensory (Treitz) muscle^{6,7}. The treatment options for symptomatic hemorrhoids have varied over time. Measures have included conservative medical management, non-surgical treatments and various surgical techniques. The various non-surgical treatments include Rubber Band Ligation (RBL) injection sclerotherapy, cryotherapy, infrared coagulation, laser therapy and diathermy coagulation; all of which may be performed as out patient procedures with or without anaesthesia. These nonsurgical methods are considered to be the primary option for grades one to three (Grade I-III) hemorrhoids⁸. If conservative measures fail to control symptoms, patients may be referred to a surgeon for operative management. The indications for the surgical treatment include the presence of a significant external component, hypertrophied papillae, associated fissure, extensive thrombosis or recurrence of symptoms after repeated RBL. The technique employed may be open (Milligan–Morgan) or closed (Ferguson) and

1. Associate Professor of Surgery
Chittagong Medical College, Chattogram.

2. Junior Consultant of Surgery
Chittagong Medical College Hospital, Chattogram.

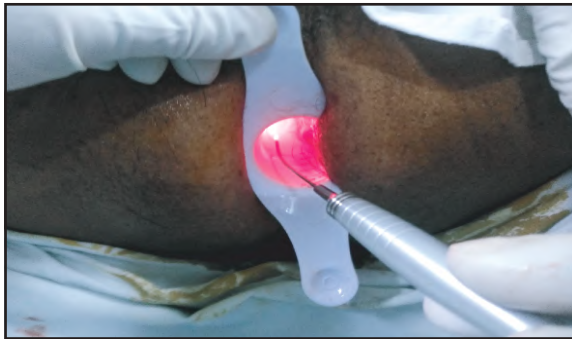3. Registrar of Surgery
Chittagong Medical College Hospital, Chattogram.

***Correspondence:** Dr. Md. Nur Hossain Bhuiyan
E-mail: dr.nurhossain@yahoo.com
Cell : 01712 46 73 17

Submitted on : 07.08.2020

Accepted on : 14.08.2020

the instruments used are scalpel, scissor, electrocautery or laser. Milligan-Morgan hemorrhoidectomy is the gold standard and frequently performed procedure in the United Kingdom⁹. Post hemorrhoidectomy pain is the commonest problem associated with the surgical techniques. The other early complications are urinary retention (20.1%), bleeding (Secondary or reactionary) (2.4%–6%) and subcutaneous abscess (0.5%). The long-term complications include anal fissure (1%–2.6%), anal stenosis (1%), incontinence (0.4%), fistula (0.5%) and recurrence of hemorrhoids^{10,11}. The aim of this study was to compare post operative pain and duration time of intervention between of the two methods, laser hemorrhoidoplasty (LHP) and surgical open hemorrhoidectomy.



Materials and methods

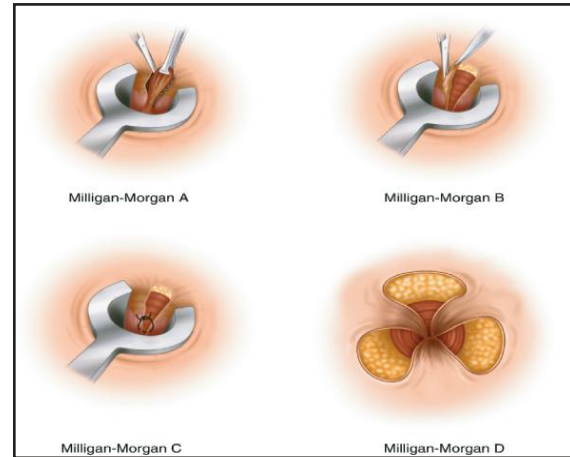
In this comparative and prospective study 60 patients were included, of which, 30 patients were treated with laser hemorrhoidoplasty method and 30 patients were treated with open surgical hemorrhoidectomy. Patients were allocated in different groups: A) patients with stage II and III and minimal prolapse of mucosa were treated with LHP B) patients with stage II and III and with mucosal prolapse, with open surgical method. This study was performed in Chittagong Medical College Hospital and Private Hospital in Chittagong from November 2019 to May 2020. After a detailed physical examination and proctoscopy, the laser procedure was performed with Lasotrenix.

Inclusion criteria

- i) Patients age above 18 years
- ii) Symptomatic haemorrhoid 2nd and 3rd degree
- iii) Willing to include in this study.

Exclusion criteria

- i) Patients age less than 18 years
- ii) 4th degree haemorrhoid
- iii) Any co-morbidity
- iv) Not willing to include in this study.



Procedure

With the patient in the lithotomy position, after spinal anaesthesia a dedicated disposable proctoscope with a diameter of 23 mm was inserted in the anal canal. Laser shots were delivered with a 980-diode laser through a 1000-nm optic fiber in a pulsed fashion to reduce undesired degeneration of periarterial normal tissue. The depth of shrinkage can be regulated by the power and duration of the laser beam. Through a 1000-micron optic fiber, five laser shots generated at a power of 13 W with duration of 1.2 s each and a pause of 0.6 s caused shrinkage of tissues to the depth of approximately 5 mm. This procedure was performed as an outpatient procedure. No bowel preparation was required. Others, 30 patients were treated with open surgical hemorrhoidectomy. Both this procedure done under spinal anaesthesia. Both group of patients discharged after 6-8 hours, and were followed for 1 week, 2 week, 3 week and 1 months for healing progress and complications. The patients were followed for the level of post-operative pain and duration of operation. Postoperative pain was recorded by using a 10-point Visual Analog Scale (VAS) on which 0 represents no pain and 10 represents the worst pain imaginable. VAS protocol was followed up after 1 week, 2 weeks, 3 weeks, 1 month. The duration of intervention was recorded in minutes. The data were analyzed with statistical tests and presented with respective tables and graphics.

Results

The LHP procedure was performed on 30 consecutive patients which had symptomatic grade II and III hemorrhoids with minimal mucosal prolapse at proctoscopy and a medical history of rare episodes of prolapse manual reduction, with mean

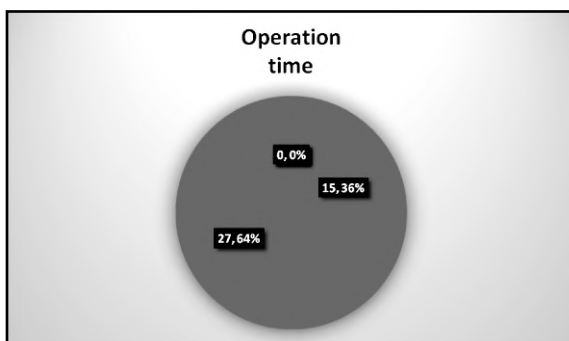
age 47 ± 12.6 (Range, 24–70) years. There were 18 men and 9 women. The open surgical procedure was performed on 30 patients which had symptomatic grade II and III hemorrhoids and with minimum prolapse and with mean age 49 ± 12.3 (Range 28-72) years. There were 15 men and 8 women. As far as pain is concerned, early postoperative pain is dominantly lower in the LHP group compared with surgical group. The same values also resulted for the period of one month. These results are presented in tables 1,2 and in figures 1, 2. The mean operative time was 15.36 ± 3.5 min in the LHP group and 26.64 ± 5.8 min ($p < 0.01$).

Table I : Pain presentation by VAS score in the LHP group.

VAS Score	Day 1	Day 7	7 Day	1 Month
0-1	5/20	19/20	19/20	20/20
2-5	15/20	1/20	1/20	0/20
>5	0/20	0/20	0/20	0/20

Table II : Pain presentation by VAS score in the surgical group.

VAS Score	Day 1	Day 7	Day 14	1 Month
0-1	0/20	0/20	8/20	15/20
2-5	18/20	20/20	12/20	5/20
>5	2/20	0/20	0/20	0/20



No major adverse effects or complications were reported. Bleeding was observed in one case (The patient was taking aspirin). In one case surgical hemostasis was necessary. Minor pain that required medication was reported in three cases, one in the LHP group and two in open surgery. No blood transfusions were needed in any of cases.

Discussion

The need for treatment for hemorrhoids is primarily based on the subjective perception of severity of symptoms and the assignment of treatment is decided on the traditional classification of hemorrhoids, which is not connected to the severity of symptoms¹². Multiplicity of treatment modalities has added confusion in decision about the treatment method. The question of the optimal treatment technique remains unanswered despite most of the techniques in use being subjected to randomized evaluation. Generally an uncomplicated hemorrhoidectomy is satisfactory on non-surgery or operation for both, patient and surgeon¹³. In a study of the university of Sao Paulo, Brazil, they stated that laser hemorrhoidectomy had the advantages of being haemostatic, bactericidal, fast healing, not affecting neighboring structures, less postoperative complications and less hemorrhage and stenosis^{14,15}. Open surgical hemorrhoidectomy is the most widely used procedure in the surgical management of hemorrhoids. However, hemorrhoidectomy is associated with significant complications including pain, bleeding and wound infection which can result prolonged hospital stay¹⁶. We found that the pain scores were significantly lower in the LHP group compared with open hemorrhoidectomy procedure group, in the early postoperative period after VAS score was 5 vs. 0 for score 0-1, 15 vs. 18 for score 2-5 and 0 vs. 2 for score above 5 in the respective groups. Postoperative pain is the most important complication that disturbs our patients and makes them reluctant to surgery. In our study, postoperative pain during the first month after both procedures, was significantly lesser in the laser hemorrhoidectomy compared with conventional open surgical hemorrhoidectomy ($p < 0.01$).

Limitation

- i) Sample is small
- ii) Single center Randomized Controlled Trial (RCT)
- iii) Cost is very high in our socioeconomic aspect
- iv) Sample size not representing whole country.

Conclusion

Laser hemorrhoidoplasty procedure is more preferred in comparison with conventional open surgical hemorrhoidectomy. Postoperative pain is significantly lesser in laser procedure compared with surgical procedure ($p < 0.01$).

Recommendation

- i) Multi center Randomized Controlled Trial (RCT) needed with a large sample size to declare that procedure is standard
- ii) Good anatomical knowledge required about vascular theory of anal canal
- iii) Specialized training needed to perform this procedure
- iv) Long term follow up.

Acknowledgments

We would like to acknowledge those who have assisted us the study and preparation of this article, all surgical faculty of Chittagong Medical College Hospital, trainees of Department of Surgery, CMCH.

Contribution of authors

MNHS- Conception, design, data analysis, drafting and final approval.

PKN- Acquisition of data, interpretation of data and final approval.

EKS – Acquisition of data, critical revision and final approval

HAK – Data analysis, drafting and final approval.

Disclosure

All the authors declared no competing interests.

References

1. Johanson JF, Sonnenberg A. The prevalence of hemorrhoids and chronic constipation: An epidemiological study. *Gastroenterology*. 1990; 98(2): 380-386.
2. Rogozina VA. Hemorrhoids. *Ekspierimental'Naia i Klinicheskaia Gastroenterologia*. 2002; 4: 93-96.
3. Johanson JF, Sonnenberg A. The prevalence of hemorrhoids and chronic constipation: An epidemiological study. *Gastroenterology*. 1990; 98(2): 380-386.
4. Parks AG. De Hemorrhoids. A study in surgical history. *Guy's Hospital Report*. 1955; 104: 135-150.
5. Keighley MRB. *Surgery of Anus, Rectum and Colon*. 1. Vol. 1, WB Saunders publishers. 1993: 295-298.
6. Haas PA, Fox TA Jr, Haas GP. The Pathogenesis of hemorrhoids. *Diseases of the colon and rectum*. 1984; 27 (7): 442-450.
7. Thomson WHF. The nature of Hemorrhoids. *British Journal of Surgery*. 1975; 62(7): 542-552.
8. MacRae HM, McLeod RS. Comparison of Hemorrhoidal Treatment Modalities. A meta-analysis. *Dis Colon Rectum*. 1995; 38(7): 687-694.
9. Monson JRT, Mortenson NJ, Hartley J. Procedures for Prolapsing Hemorrhoids (PPH) or Stapled Anopexy. Consensus Document for Association of Coloproctology of Great Britain and Ireland. ACPGBI. 2003.
10. Bleday R, Pena JP, Rothenberger DA, Goldberg SM, Buls JG. Symptomatic Hemorrhoids: Current Incidence and Complications of Operative Therapy. *Diseases of the colon and rectum*. 1992; 35 (5): 477-481.
11. Sardinha TC, Corman ML. Hemorrhoids. *The Surgical clinics of North America*. 2002; 82(6): 1153-1167.
12. Goligher J, Duthie H, Nixon H. *Surgery of the Anus Rectum and Colon*. 5. London: Baillière Tindall, 1984.
13. Salfi R. A new technique for ambulatory hemorrhoidal treatment Doppler-guided laser photocoagulation of hemorrhoidal arteries. *Coloproctology*. 2009; 31: 99-103.
14. Chia YW, Darzi A, Speakman CT, Hill AD, Jameson JS, Henry MM, Department of Surgery, Central Middlesex Hospital, London, UK, *Int. J Colorectal Dis*. 1995; 10(1): 22-24.
15. Laurie Barclay. Best option for evaluating and treating hemorrhoids. *BMJ*. 2008; 336: 380-383.
16. Milligan ET, Morgan CN, Jones LE, Officer R. Surgical anatomy of the anal canal and the operative treatment of hemorrhoids. *Lancet*. 1937; 2: 1119-1124.