

Functional Outcome of Proximal Fibular Osteotomy in Medial Compartment Osteoarthritis of The Knee Joint

Chandan Kumar Das¹ Md. Mizanur Rahman Chowdhury² Saikat Ghosh^{3*}
 Mohammad Qausarul Matin² Md Nazrul Islam Choudhuri² Md Somirul Islam²

Abstract

Background: Proximal Fibular Osteotomy (PFO) has been proposed as a new surgical option for pain relief in patients with medial compartment knee osteoarthritis. It is simple, safe and affordable. To assess functional outcome of proximal fibular osteotomy in medial compartment osteoarthritis of knee joint.

Materials and methods: This prospective hospital based clinical trial was carried out in the Department of Orthopedic Surgery Chittagong Medical College Hospital (CMCH) Chattogram from July 2019 to June 2020. A total of 30 patients with knee osteoarthritis were enrolled through inclusion and exclusion criteria by purposive sampling. Proximal fibular osteotomy was done after taking written informed consent. Data was recorded in a predesigned case record form. All the patients were followed up to 6 months when final outcome was assessed by Oxford Knee Score. All the data were analyzed statistically by using Statistical Package for Social Sciences (SPSS-25). The result was expressed as frequency, percentage and mean \pm SD. Level of significance was calculated at $p < 0.05$.

Results: In this study, out of 30 cases, majority of the cases (57.7%) was in 55-64 years of age group. Mean \pm SD pre-operative and post-operative VAS score were 7.13 ± 1.408 and 2.10 ± 0.803 respectively. According to Oxford Knee Score (OKS) pre-operative and post-operative mean \pm SD were, 18.00 ± 2.117 and 36.53 ± 2.403 . Mean \pm SD pre-operative and post-operative Tibio Femoral Angle were 182.97 ± 1.810 and 178.63 ± 1.377 respectively. Mean \pm SD pre-operative and post-operative Medial Joint Space (mm) were 1.223 ± 0.378 and 3.816 ± 0.982 respectively. Mean \pm SD pre-operative and post-operative Lateral Joint Space (mm) were 6.640 ± 1.209 and 5.050 ± 0.897 respectively.

Conclusion: After analyzing the results of present study, it can be concluded that proximal fibular osteotomy is a new,

simple procedure in the management of medial compartment osteoarthritis of the knee which may delay the need for definitive knee procedures like unicompartmental knee arthroplasty or total knee replacement.

Key words: Arthroplasty; Knee; Osteoarthritis; Pain; Proximal fibular osteotomy.

Introduction

Knee Osteoarthritis (OA) is a major public health problem causing chronic pain and work incapacity in the elderly population.¹ The incidence of Knee Osteoarthritis (KOA) is on the rise and is affecting the geriatric people and also the younger population.² It manifests as joint pain, limitation of joint mobility, reduction in physical functioning and diminishes the quality of life. Increasing age and obesity are considered to be significant risk factors, for development of knee OA.³ Previous knee injuries and occupational activities are also found to be associated with development of OA knee. Joint space narrowing, development of osteophytes and subchondral sclerosis are the characteristic radiological features.^{3,4}

The pathological characteristics of Knee Osteoarthritis (KOA) include joint structure degradation, cartilage destruction with joint pain, dysfunction and joint deformity as the main clinical symptoms. KOA affects about 50% of >60-year-old individuals, especially women and it is associated with post-menopausal osteoporosis. Surgical methods for KOA include arthroscopic debridement, High Tibial Osteotomy (HTO) proximal fibular osteotomy and unicompartmental or artificial total knee arthroplasty.⁵

It is a chronic disorder having multifactorial etiology which ultimately leads to joint failure.^{6,7} Most of the patients have idiopathic OA of knee which leads to varus deformity of knee having reduced medial joint space and mechanical tibiofemoral axis of less than 180 degree on standing antero-posterior radiograph.⁸

The cause of OA remains unknown, though there is clear evidence for major risk factors, such as age, obesity, joint trauma and heavy work load.⁹

1. Professor of Orthopedic Surgery
Chittagong Medical College, Chattogram.
2. Associate Professor of Orthopedic Surgery
Chittagong Medical College, Chattogram.
3. Resident of Orthopedic Surgery (MS-Orth-Phase-B)
Chittagong Medical College Hospital, Chattogram.

***Correspondence:** Dr. Saikat Ghosh
 Cell : 01866 47 24 64
 E-mail: saikatbd84@gmail.com

Submitted on : 04.09.2021

Accepted on : 11.12.2021

Total Knee Arthroplasty (TKA) is the main surgical alternative in the developed countries. However, TKA is expensive, complex and some patients need a second knee revision after the first surgery.^{10,11} In the low and middle income countries, lacking of appropriate healthcare infrastructure or inability to fund expensive treatment of arthroplasty for osteoarthritis can hardly afford to benefit from such advanced method. Although, High Tibial Osteotomy (HTO) is the first choice treatment for young patients with osteoarthritis of the medial compartment of the knee, there are some potential disadvantages after surgery such as non-union of the osteotomy.¹²⁻¹⁴ PFO is an alternative treatment to HTO.¹⁵ It is a surgical procedure for medial compartment knee osteoarthritis (KOA). PFO has several advantages.¹¹ First, the surgical technique is simple and easily performed. Second, it is less invasive with a very short incision, requires limited tissue dissection and no internal fixation is implanted. The postoperative recovery period is also shorter. In addition, the complications associated with HTO can be a major problem that contributes to a poor prognosis.¹⁶ In contrast, PFO is associated with few complications.¹⁷

The PFO also helps in the correction of a varus deformity in KOA, which shift the loading force from the medial compartment more laterally. It, therefore, helps in decreasing the pain and satisfactory functional recovery. The existing literatures were critically reviewed to evaluate the usefulness of PFO.^{18,19} So this study has been designed to evaluate functional outcome of proximal fibular osteotomy in medial compartment osteoarthritis of the knee joint.

Materials and methods

It was a prospective hospital base clinical study, carried out in the Department of Orthopaedic Surgery, CMCH, Chottogram from July 2019 to June 2020. In this study total 30 samples of medial compartment knee osteoarthritis were included and exclusion criteria includes tricompartmental osteoarthritis, varus deformity greater than 12 degrees, fixed flexion deformity above 15 degrees, post traumatic osteoarthritis, inflammatory joint disease of knee and history of previous operations or fractures. History, physical examination and personal information were recorded using questionnaire and medical chart

review. The length of fibular segment resected was 1.5 to 2 cm, and the distance from fibular head to the proximal cut was 6 to 9 cm. The idea here was to remove the two fibular cortices, converting the knee to a more balanced joint, with unicortical support on either side, allowing correction of mechanical axis. The resection was high enough to cause a mechanical axis shift, but not too high to damage the lateral popliteal nerve. The size of the resected segment and its distance from fibular head depends on the patient's height. Shorter patients had a 1.5 cm segment resected 6 cm below fibular head, tall patients had a 2 cm resection, some 8 to 9 cm below the fibular head. The wound was washed, closed in layers and a light compression bandage given. The patient was mobilized as soon as tolerated which in most cases was within a few hours. All but three cases were performed as a day care surgery. All the data were analyzed statistically by using Statistical Package for Social Sciences (SPSS-25). The result was expressed as frequency, percentage and mean \pm SD. Level of significance was calculated at $p < 0.05$. Approval from Ethical review committee of CMCH was duly taken.

Results

This prospective hospital based clinical trial was conducted between the periods of July 2019 to June 2020 for duration of twelve months in the Department of Orthopaedic Surgery, Chittagong Medical College Hospital. In this study, a patient >45 years of age presented with knee osteoarthritis was the study sample. Total 30 samples were included. Follow up was given on day fifteen, after two month and six months. Pain relief measured by VAS, functional recovery by Oxford knee score and radiological evaluation by measurement of tibiofemoral angle, medial joint space and lateral joint space. Only one patient developed paresthesia on dorsum of foot which recovered after six weeks.

Table I Distribution of the study population by their age (n=30)

Age (Years)	Frequency	Percentage (%)
45-54	10	33.3%
55-64	17	57.7%
65	03	10.0%
Total	30	100%
Mean \pm SD		56.83 \pm 5.742
Range		45-69 years

Majority of the cases (57.7%) was in 55-64 years of age group. The mean \pm SD age of the cases was 56.83 ± 5.742 years (Range: 45-69 years) (Table I).

In this study mean \pm SD pre-operative and post-operative VAS score were 7.13 ± 1.408 (Range: 5-9) and 2.10 ± 0.803 (Range: 1-3) respectively. p value shows statistically very highly significant changes before and after operation.

Table II Pre-operative and post-operative OKS of the cases (n=30)

Oxford Knee Score	Pre-operative	Post-operative	p value
Mean \pm SD	18.00 ± 2.117	36.53 ± 2.403	<0.001***
Range	15-22	32-41	

According to Oxford Knee Score (OKS) Pre-operative and post-operative mean \pm SD were, 18.00 ± 2.117 (Range: 15-22) and 36.53 ± 2.403 (Range: 32-41). p value shows statistically very highly significant changes before and after operation (Table II).

In this study, mean \pm SD pre-operative and post-operative Tibio Femoral Angle ($^{\circ}$) were 182.97 ± 1.810 (Range: 180-186) and 178.63 ± 1.377 (Range: 176-181) respectively. p value shows statistically very highly significant changes before and after operation.

Table III Pre-operative and post-operative MJS (mm) of the cases (n=30)

Medial Joint Space (mm)	Pre-operative	Post-operative	p value
Mean \pm SD	1.223 ± 0.378	3.816 ± 0.982	<0.001***
Range	0.30-1.70	1.40-5.10	

Above Table III shows that, mean \pm SD pre-operative and post-operative Medial Joint Space (mm) were 1.223 ± 0.378 (Range: 0.30-1.70) and 3.816 ± 0.982 (1.40-5.10) respectively. p value shows statistically very highly significant changes before and after operation (Table III).

In this study, mean \pm SD pre-operative and post-operative Lateral Joint Space (mm) were 6.640 ± 1.209 (Range: 4.20-8.00) and 5.050 ± 0.897 (range: 3.40-6.40) respectively. p value shows statistically very highly significant changes before and after operation.

Discussion

In low and middle income countries like Bangladesh, Proximal Fibular Osteotomy (PFO) for osteoarthritis of knee joint has developed as an alternative procedure to high-tibial osteotomy and unicompartmental knee arthroplasty. It is simple, safe and affordable. PFO helps relief pain in almost all patients.²⁰

In this present study, Majority of the cases (57.7%) were in 55-64 years of age group. The mean \pm SD age of the cases were 56.83 ± 5.742 years (Range: 45-69 years) (Table I). A recent study by Khanna et al the age distribution ranged from 40 years to 72 years of age with a mean age of 57.68 ± 9.22 years.²¹ Another recent study conducted by Laik et al stated that in their study, a maximum number of patients were found to be in the 6th decade of life with a mean (Standard Deviation (SD) age of $55.80 (\pm 4.41)$ years.²² The mean age of patients was 51.8 ± 4.1 years (Ahmed et al).¹⁹ Similarity was found with all the studies.

In present case series, mean \pm SD pre-operative and post-operative VAS score were 7.13 ± 1.408 (Range: 5-9) and 2.10 ± 0.803 (Range: 1-3) respectively. p value shows statistically very highly significant changes before and after operation. Similarly, mean recorded levels of VAS for pain postoperatively were 2.32 ± 0.792 , which improved significantly from 7.90 ± 0.79 .¹⁹ The Mean VAS Score pre-operatively was 6.83 which showed a significant post-operative reduction to 3.20. (p = 0.004).²¹ Pre-operative and post-operative mean visual analog score was improved from 8.02 ± 0.50 to 2.74 ± 0.23 .²³

According to Oxford Knee Score (OKS), pre-operative and post-operative mean \pm SD were, 18.00 ± 2.117 (Range: 15-22) and 36.53 ± 2.403 (Range: 32-41). p value shows statistically very highly significant changes before and after operation. The recorded mean preoperative Oxford knee score was 20.82 ± 1.97 mm.¹⁹ Similarly, the Oxford Knee Score, with a range of 16 to 36 preoperatively and a mean of 27.53 increased to average of 36.93 at post operatively, which was found to be statistically significant (p = 0.001).²¹

Khanna et al found the medial joint space measured pre-operatively ranged from 2 mm to 3.5 mm with the mean being 2.81 mm and the postoperative values ranged from 2.6 mm to 4.9 mm with the mean being 3.74 mm. (p = 0.001).²¹ Medial joint space was measured on plain AP X-ray of the knee after adjusting the magnification factor. The preoperative mean (SD) value of 30 patients was 5.63 mm (± 0.21) and the mean (SD) postoperatively was 6.05 (± 0.27). To test the statistical significance, paired t-test was used and p value of < 0.0001 was considered statistically highly significant. Present study showed, mean \pm SD

pre-operative and post-operative Medial Joint Space (mm) were 1.223 ± 0.378 (Range: 0.30-1.70) and 3.816 ± 0.982 (1.40.5.10) respectively. p value shows statistically very highly significant changes before and after operation.

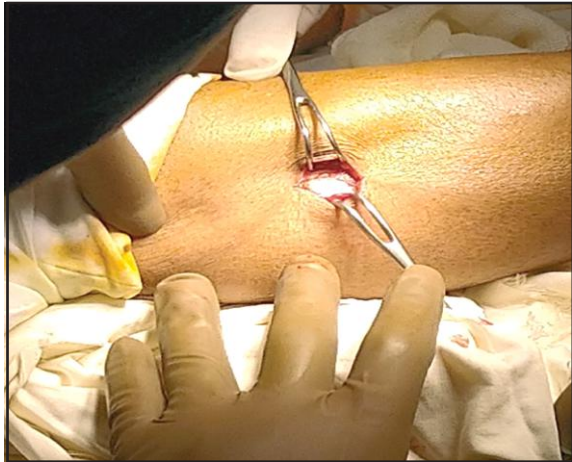


Fig 1 Skin Incision was given 7cm distant from fibular head

The lateral joint space showed uniform reduction post operatively from 7.2 ± 1.2 mm to 5.2 ± 1 mm ($p < .001$)⁵ Khanna et al noticed that the average lateral joint space reduced from 5.93 mm to 5.34 mm after the procedure.⁵ ($p = 0.001$). In this study, mean \pm SD pre-operative and post-operative Lateral Joint Space (mm) were 6.640 ± 1.209 (Range: 4.20-8.00) and 5.050 ± 0.897 (Range: 3.40-6.40) respectively. p value shows statistically very highly significant changes before and after operation.

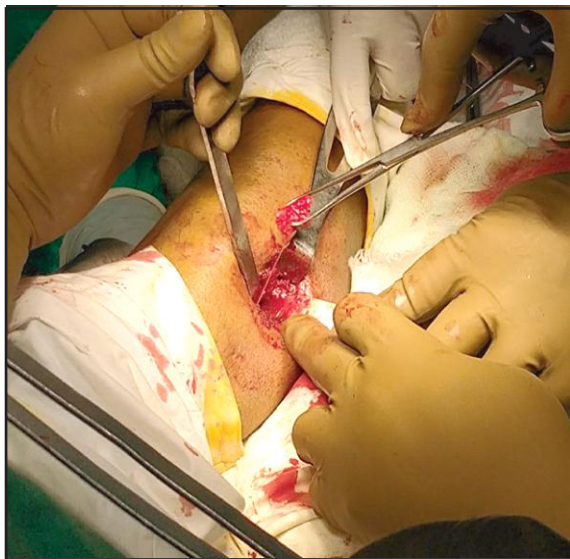


Fig 2 2cm of sectioned Fibula was removed

Principle of PFO: Non-uniform settlement or stress imbalanced syndrome: The fibula bone is mostly a non-weight bearing bone which takes 6.4% of the body weight and serves mainly as the attachment site for various muscles of the leg and foot. As a normal aging process, the bone mass decreases. In healthy individuals, the weight transmission from femoral condyle to the tibia is equal in both condyles, but in case of osteoporosis, the subchondral bone of the tibia becomes weak. The support of fibula over lateral condyle helps lateral condyle tibia transmit weight but medial condyle tibia has no such support which therefore leads to non-uniform settlement. Therefore, non-uniform settlement occurs, due to increasing the load distribution in the medial compartment. The lateral support of the fibula to the tibial plateau is considered as the crucial factor that leads to the non-uniform settlement. It results in a medial shift of the mechanical axis, which results in varus deformity and degeneration of the knee joint.¹⁸

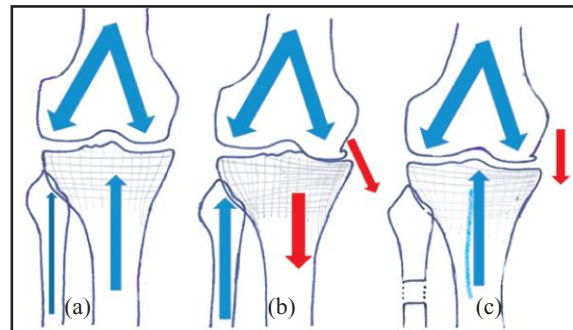


Fig 3 Mechanism of action of Proximal Fibular Osteotomy (PFO)

Limitations

Short duration of follow up to evaluate long term changes in disease progression.

Conclusion

The present study concludes that PFO is a new procedure in the management of medial compartment knee osteoarthritis. It is a simple, easy procedure and gives pain relief postoperatively. It is associated with little or no complications. It may delay the need for definitive knee procedures like unicompartmental knee arthroplasty or total knee replacement.

Recommendation

Future studies are needed to compare the effects of PFO with HTO or UKA to evaluate the role of PFO as a standard surgical option for isolated medial compartment OA knee.

Acknowledgement

We the authors acknowledge the patients and patient's guardian including the official staff of Orthopaedic department.

Contribution of authors

CKD-Design, interpretation of data, critical revision & final approval.

MMRC-Data analysis, interpretation of data, drafting & final approval.

SG-Conception, acquisition of data, drafting & final approval.

MQM-Data analysis, critical revision & final approval.

Disclosure

All the authors declared no competing interests.

References

1. Fransen M, McConnell S, Harmer AR, Van der Esch M, Simic M, Bennell KL. Exercise for osteoarthritis of the knee. *Cochrane Database of Syst Rev.* 2015 (1): CD004376.
2. Fooladi S, Vaish A, Nigam Y, Vaishya R. Joint preservation in a middle-aged man with knee osteoarthritis, using novel techniques. *Apollo Medicine.* 2019;16(2):124.
3. Cooper C, McAlindon T, Coggon D, Egger P, Dieppe P. Occupational activity and osteoarthritis of the knee. *Annals of the rheumatic diseases.* 1994;53(2):90-93.
4. Coggon D, Croft P, Kellingray S, Barrett D, McLaren M, Cooper C. Occupational physical activities and osteoarthritis of the knee. *Arthritis & Rheumatism: Official Journal of the American College of Rheumatology.* 2000;43(7):1443-1449.
5. Prakash, L. A beginner's guide to total knee replacement. CBS Publications, New Delhi, ISBN 978-93-86217. 2016;48-56.
6. Silman, A. J. and Hochberg, M. C. *Epidemiology of the Rheumatic Diseases.* 2nd ed. Oxford: Oxford University Press. 2001;377.
7. Akinpelu AO, Alonge TO, Adekanla BA, Odole AC. Prevalence and pattern of symptomatic knee osteoarthritis in Nigeria: A community-based study. *Internet Journal of Allied Health Sciences and Practice.* 2009;7(3):10.
8. Shiozaki H, Koga Y, Omori G, Yamamoto G, Takahashi HE. Epidemiology of osteoarthritis of the knee in a rural Japanese population. *The Knee.* 1999;6(3):183-188.
9. Nuki G, Salter D. The impact of mechanical stress on the pathophysiology of osteoarthritis. *Osteoarthritis.* Philadelphia: Mosby. 2007:33-52.
10. Burnett RS, Bourne RB. Indications for patellar resurfacing in total knee arthroplasty. *JBJS.* 2003;85(4):728-745.
11. Zhang YZ. Innovations in orthopedics and traumatology in China. *Chinese medical journal.* 2015;128(21):2841.
12. Duivenvoorden T, Brouwer RW, Baan A, Bos PK, Reijman M, Bierma-Zeinstra SM, Verhaar JA. Comparison of closing-wedge and opening-wedge high tibial osteotomy for medial compartment osteoarthritis of the knee: A randomized controlled trial with a six-year follow-up. *JBJS.* 2014;96(17):1425-1432.
13. LaPrade RF, Spiridonov SI, Nystrom LM, Jansson KS. Prospective outcomes of young and middle-aged adults with medial compartment osteoarthritis treated with a proximal tibial opening wedge osteotomy. *Arthroscopy: The Journal of Arthroscopic & Related Surgery.* 2012;28(3):354-364.
14. Sprenger TR, Doerzbacher JF. Tibial osteotomy for the treatment of varus gonarthrosis: survival and failure analysis to twenty-two years. *JBJS.* 2003;85(3):469-474.
15. Yang ZY, Chen W, Li CX, Wang J, Shao DC, Hou ZY, Gao SJ, Wang F, Li JD, Hao JD, Chen BC. Medial compartment decompression by fibular osteotomy to treat medial compartment knee osteoarthritis: a pilot study. *Orthopedics.* 2015;38(12):e1110-e1114.
16. Ghinelli D, Parma A, Baldassarri M, Olivieri A, Mosca M, Pagliuzzi G, Buda R. High tibial osteotomy for the treatment of medial osteoarthritis of the knee with new iBalance system: 2 years of follow-up. *European Journal of Orthopaedic Surgery & Traumatology.* 2016;26(5):523-535.
17. Wang X, Wei L, Lv Z, Zhao B, Duan Z, Wu W, Zhang B, Wei X. Proximal fibular osteotomy: A new surgery for pain relief and improvement of joint function in patients with knee osteoarthritis. *Journal of International Medical Research.* 2017;45(1):282-289.
18. Vaish A, Kathiriya YK, Vaishya R. A critical review of proximal fibular osteotomy for knee osteoarthritis. *Archives of Bone and Joint Surgery.* 2019;7(5):453.
19. Ahmed M, Bux M, Kumar M, Ahmed N, Hussain G, Ishtiyaque Sr M. Proximal fibular osteotomy in the management of osteoarthritis of medial compartment of knee joint. *Cureus.* 2020;12(6).
20. Misra RK, Batra AV. Clinical and functional outcomes of proximal fibular osteotomy on varus deformity and medial compartment knee osteoarthritis. *Journal of Arthritis.* 2019;8(3):1-4.
21. Khanna, G., Dewan, A., Singh, A. R. and Attri, R. Evaluating the role of proximal fibular osteotomy in medial compartment osteoarthritis of Knee. *International Journal of Medical and Health Research.* 2020;6(1):01-04.
22. Laik JK, Kaushal R, Kumar R, Sarkar S, Garg M. Proximal fibular osteotomy: Alternative approach with medial compartment osteoarthritis knee-Indian context. *Journal of Family Medicine and Primary Care.* 2020;9(5):2364.
23. Reddy, V., Raghav, T. S., Panapana, S. R., Burma, S. S., Burma, S. M., Koduru, S. K. Proximal fibular osteotomy for medial compartment osteoarthritis of knee. *Indian J Orthop Surg.* 2019;5(4):263-266.