

Femoral Neck Fracture Treated with Dynamic Hip Screw System with De-rotation Screw Versus Cannulated Hip Screws

Shantonu Kumar Saha¹ Hasina Momotaj Hira^{2*} Javed Jahangir³
Ajoy Deb⁴ Mamun Mustafa⁵ S. Ripon Kumar Ghosh⁶

Abstract

Background : Fracture neck of femur has always presented a great challenge to orthopedic surgeons due to its nature of going into non-union and osteonecrosis of femoral head even with the best fixation method and adequate reduction. Treatment of fracture neck of femur varies according to patient's age and fracture pattern. Purpose of this study was to compare the outcome of DHS with side plate and de-rotation screw with multiple cannulated hip screws in fracture neck of femur in adult.

Materials and methods: This quasi-experimental study was carried out in the Department of Orthopedic Surgery, Chittagong Medical College Hospital from July 2017 to June 2019. Sixty patients age limit between 18 to 55 years, with (AO/OTA 31-B) fracture was taken by purposive sampling technique as per set criteria and were treated either by DHS with side plate and de-rotation screw or by cannulated hip screws. Harris Hip Score was used for evaluation of functional outcome of surgery.

Results: In this study, out of 60 patients, male (83%) were more than female (17%), maximum age incidence was found in 26-36 years age group (30%), left side involvement was 51.7% and right side was 48.3%. Over 60% incidence was due to RTA. Functional outcome was 68% excellent and 24% good in DHS with de-rotation screw group and 55.6% good and 25.9% excellent in cannulated hip screw group according to Harris Hip Score. Only 6.7% had soft tissue infection, 13.3% had deep seated infection and delayed union, 10% had non-union and hip stiffness and 6.7% had AVN in DHS with de-

rotation screw group and 10% had soft tissue infection, 6.7% had deep seated infection and delayed union, 13.33% had non-union and hip stiffness and 10% had AVN in cannulated hip screw group. Mean \pm SD radiological union time in DHS with de-rotation screw group was 12.5 ± 1.225 weeks and in cannulated hip screw group was 13.61 ± 1.559 weeks.

Conclusion: The functional outcome of fixation by DHS with de-rotation screw was better than fixation by cannulated hip screw for femoral neck fracture in adults.

Key words: Cannulated hip screw; Dynamic hip screw; Femoral neck fracture; Internal fixation.

Introduction

Worldwide hip fracture is a serious and rising public health problem. In many countries treatment expense associated with hip fracture already exceed those from all other fractures.¹ As Raaymakers expressed, 'about half of the fractures of the proximal femur are located in the femoral neck.'² The occurrence of femoral neck fracture, accounting for 3.6% of all fractures and 53-56% of hip fractures.^{3,4} Early surgical interventions, which are of benefit to early restoring limb function and reducing post-operative complications, have gradually become the optimal solution to treat femoral neck fractures.⁵ It is advocated that fracture reduction and fixation should be performed as a surgical emergency in an attempt to recover the insecure blood supply to the femoral head and prevent complications such as non-union and avascular necrosis, the incidence of these complications being 10-20% and 10-30% respectively.^{6,7}

Numerous surgical procedures and implants have been developed and used for the management of femoral neck fracture, including dynamic hip screw system blade and cannulated compression screw.⁸ Treatment protocol varies according to fracture pattern, patient's age, bone quality and pre-existing comorbidities.^{9,10} Various treatment modalities including cannulated hip screw and dynamic hip screw with side plate and de-rotation screw, nail and pin, double angle plate have been

1. Assistant Professor of Orthopedics
TMSS Medical College, Bogura.
2. Assistant Professor of Community Medicine
Abdul Malek Ukil Medical College, Noakhali.
3. Assistant Professor of Orthopedics
Chittagong Medical College, Chattogram.
4. Associate Professor of Community Medicine
Chittagong Medical College, Chattogram.
5. Assistant Registrar of Orthopedics
Chittagong Medical College Hospital, Chattogram.
6. Junior Consultant of Orthopedic Surgery
Centre for Woman and Child Health, Dhaka.

***Correspondence:** Hasina Momotaj Hira
Cell : 01711 78 87 57
E-mail: hira.sbmc33@gmail.com

Submitted on : 28.04.2022

Accepted on : 21.05.2022

described for the management of fracture neck of femur.^{2,11}

There are two principal treatment modalities for femoral neck fracture are DHS with side plate and de-rotation screw or cannulated hip screw. DHS with side plate which was introduced in 1950's maintains normal neck-shaft angle, allow ideal placement of a single screw in femoral head and compression across the fracture line.^{9,12,13} Dynamic hip screw or sliding screw fixation consists of a lag screw, a side plate and cortical screws which fix the side plate to the proximal femoral shaft. The lag screw is inserted into the head of femur from the lateral aspect.¹⁴ But it has some disadvantages of tissue stripping and additional blood loss which can be prevented by an additional 6.5mm cancellous screw which helps to prevent rotation of proximal fragment during triple reaming.^{15,16}

Cannulated hip screw which introduced in 1989 has some advantages of decreased blood loss, reduced operative time, lower transfusion requirement and early hospital leaving.¹⁷ But it has also been reported that early loosening of screws may occur if lateral cortex is damaged from osteoporosis.¹⁸ Kyle determined that the most consistent results were obtained with internal fixation using multiple hip screw.¹⁹ In five years' experience in treating neck of femur fracture with closed reduction and cannulated screw fixation, Khoo et al found no significant relationship between the incidence of AVN in relation to age of patient, fracture displacement, number of cannulated screw used, fracture reduction acceptability and anatomical locations of fracture.²⁰

Kuokanen et al concluded that there was no difference in the functional outcome between these two procedures.²¹ In a study by Kaplan et al the non-union rates 9% for DHS group while it was 3% for CHS group.²² Jetto and James described that multiple screw fixation for intracapsular hip fracture was associated with a higher conversion rate to hemiarthroplasty or THA at one and four years, compared with DHS fixation.²³ This study was aimed to compare the clinico-radiological outcome of fracture neck femur treated with DHS with de-rotation screw or cannulated hip screw in adult (AO/OTA 31-B).

Materials and methods

This quasi-experimental study was carried out in the Department of Orthopedic Surgery, Chittagong Medical College Hospital from July 2017 to June 2019. Sixty patients age limit between 18 to 55 years, with (AO/OTA 31-B) fracture was taken by purposive sampling technique as per set criteria and were treated either by DHS with side plate and de-rotation screw or by cannulated hip screws. Harris Hip Score was used for evaluation of functional outcome of surgery. Follow up was given at 3rd month, 6th month, 9th month and 12th month. Lost to follow up was, 3 patients at 2nd follow up, 6 patients at 3rd follow up and 8 patients at 4th follow up. After collection, data was checked, verified and edited as per specific objectives and key variables. Data analysis was done with SPSS (Statistical Package for Social Science), Ver. 25 and by using the MS Excel. Continuous data were expressed as mean \pm Standard deviation and range. They were compared by independent sample t-test. Categorical data were expressed as frequency, percentage and compared between groups by either Chi-square test or Fischer Exact test. p-value was considered as statistically significant when it is less than 0.05 and confidence interval was set at 95% level.

To conduct this study written permission was taken from Ethical Review Committee, Chittagong Medical College and institutional clearance was obtained from the Director of Chittagong Medical College Hospital.

Results

In this study, maximum age incidence was found in 26-36 years age group (30%). Average mean \pm SD age was 36.83 \pm 11.05 and range was 19-55 years. Among them, 50(83%) were male and 10(17%) were female. Regarding mechanism of injury, 60% was due to RTA. According to side of injury, 51.7% patients had injury on left side (Table I). Among 60 patients, in DHS with de-rotation screw group, patients had suffered with post-operative complication like soft tissue infection only 2(6.7%), deep seated infection and delayed union only 1(3.3%), non-union and hip stiffness 3(10%) and AVN 2(6.7%). In cannulated hip screw group, patients had suffered with postoperative complication like soft tissue infection 3(10%), deep seated infection and

delayed union 2(6.7%), non-union and hip stiffness 4(13.3%) and AVN 3(10%). There was no significant difference in complications among the two groups of fixations according to p value (Table II).

Figure 1 shows out of 45 patients who had complete radiological union of bone, found statistically significant according to p value (p=0.021), where time taken for radiological union was less in DHS with de-rotation screw group. Average mean ± SD radiological union time were 13.07 ± 1.498 weeks. Mean ± SD radiological union time in DHS with de-rotation screw group was 12.50 ± 1.225 and in cannulated hip screw group was 13.61 ± 1.559. At 12th month follow up, among 52 patients, 24(46.2%) patient's functional outcome was excellent and 21(40.4%) patient's functional outcome was good. In DHS group, 17(68%) patient's functional outcome was excellent and 6(24%) patient's functional outcome was good. In cannulated hip screw group, 15(55.6%) patient's functional outcome was good and 7(25.9%) patient's functional outcome was excellent. According to p value, functional outcome was significantly better in DHS with de-rotation screw group (p=0.01) (Figure 2).

Table I Demographic features and injury details (n=60)

	DHS with de-rotation screw n (%)	Cannulated Hip Screw n (%)	Total n (%)
i) Age (In years)			
18-25	7(23.33%)	4(13.33%)	11(18.33%)
26-35	11(36.66%)	7(23.33%)	18(30.00%)
36-45	6(20.00%)	11(36.66%)	17(28.33%)
46-55	6(20.00%)	8(26.66%)	14(23.33%)
Mean ± SD	34.70 ± 11.31	38.97 ± 10.54	36.83 ± 11.05
ii) Sex			
Male	25(83.3%)	25(83.3%)	50(83.3%)
Female	5(16.7%)	5(16.7%)	10(16.7%)
iii) Mechanism of injury			
RTA	20(66.66%)	16(53.33%)	36(60%)
Fall from height	10(33.33%)	14(46.66%)	24(40%)

Table II Post-operative complications (n=60)

	DHS with de-rotation screw n (%)	Cannulated Hip Screw n (%)	Total n (%)	p value
i) Soft tissue infection	2(6.7%)	3(10.0%)	5(8.3%)	0.640 ^{ns}
ii) Deep seated infection	1(3.3%)	2(6.7%)	3(5%)	0.554 ^{ns}
iii) Delayed Union	1(3.3%)	2(6.7%)	3(5%)	0.554 ^{ns}
iv) Non union	3(10.0%)	4(13.3%)	7(11.7%)	0.688 ^{ns}
v) Hip stiffness	3(10.0%)	4(13.3%)	7(11.7%)	0.688 ^{ns}
vi) AVN	2(6.7%)	3(10.0%)	5(8.3%)	0.640 ^{ns}

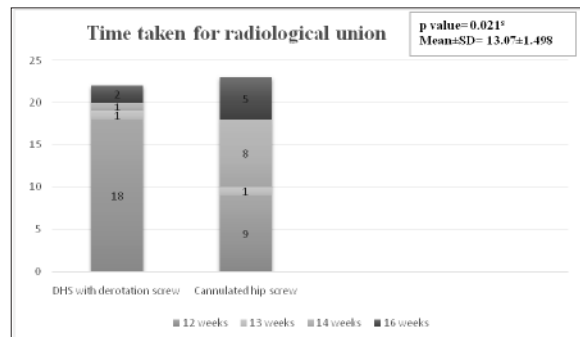

Figure 1 Distribution of the patients regarding time taken for radiological union and type of operation (n=45)

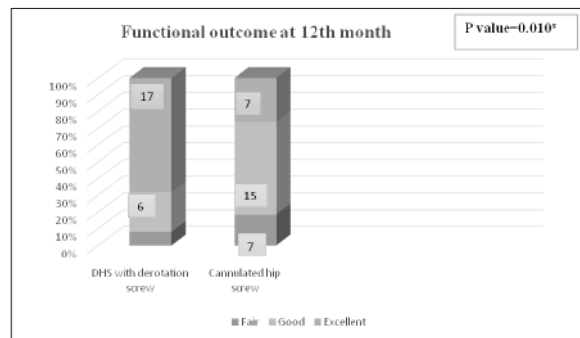


Figure 2 Distribution of the patients according to functional outcome at 12th month and type of operation (n=52)

Discussion

In this study several follow up were done at 3rd month, 6th month, 9th month and 12th month. Functional assessment was done according to Harris Hip Score.²⁴ The complications were defined as conditions leading soft tissue infection, deep seated infection, delayed union, non-union, hip stiffness and Avascular Necrosis (AVN). The overall clinical outcomes were categorized according to Harris Hip Score as excellent, good, fair and poor.²⁴

Present study shows, average mean \pm SD age was 36.83 ± 11.05 and range was 19-55 years. The mean age was 34.70 ± 11.31 in DHS group and 38.97 ± 10.54 in cannulated screw group. Maximum age incidence was found in 26-36 years age group (30%). These figures were compared favorably with other workers. Kaplan et al. showed the mean age of the patients at the time of surgery was 46 years (Range: 25-67) in DHS group and 45 years (Range: 18-68) in cannulated hip screw group.²² In other studies, like Jettoo and James showed 18.2% were aged 50 to 69 years, 43.5% 70 to 85 years, and 38.3% >85 years. More patients aged 50 to 69 years underwent multiple screw fixation than DHS fixation (21.4% vs. 15.0%, $p < 0.001$), whereas more patients aged 85 years underwent DHS fixation than multiple screw fixation (41.4% vs. 35.2%, $p < 0.001$) and Chen et al. (2017) showed mean \pm SD age was 58.3 ± 9.3 years in DHS group and 56.8 ± 8.6 years in cannulated hip screw group.^{23,25}

This study had 50(83%) male and 10(17%) were female. In both DHS and cannulated hip screw group, 25(83.3%) patients were male and 5(16.7%) patients were female. Similar demographic scenario was revealed in studies Chen et al. He showed 18(42.86%) were male and 24(57.14%) were female in DHS group and 20(45.45%) were male and 24(54.54%) were female in cannulated hip screw group.²⁵ In Jettoo and James study, there was a female preponderance (73.8%).²³

According to side of injury, in DHS group, 14(46.66%) patients had on right side and 16(53.33%) patients had on left side. In cannulated hip screw group, 15(50%) patients had on right side and 15(50%) patients had on left side involvement. In comparison to this study Schwartzmann et al had got right sided involvement was 28(54.3%) and 25(45.7%) on left side.²⁶

Regarding the mechanism of injury, in DHS group, 20(66.66%) patients had RTA and 10(33.33%) patients had fall from height. In cannulated hip screw group, 16(53.33%) patients had RTA and 14(46.66%) patients had fall from height. p value was 0.796 that is statistically not significant. This result corresponds to Kaplan et al study where causes of were seen more frequently after a fall on stair.²²

This study represents that, among 60 patients, in DHS with derotation screw group, patients had suffered with postoperative complication like soft tissue infection only 2(6.7%), deep seated infection and delayed union only 1(3.3%), non-union and hip stiffness 3(10%) and AVN 2(6.7%). In cannulated hip screw group, patients had suffered with postoperative complication like soft tissue infection 3(10%), deep seated infection and delayed union 2(6.7%), non-union and hip stiffness 4(13.3%) and AVN 3(10%). There was no significant difference in complications among the two groups of fixations according to p value. A recent study carried by Chen et al revealed, in DHS group AVN was 7.1% and in cannulated hip screw group AVN was 9.1% and non-union was 4.5%.²⁵ Another study showed, in DHS group, infection was 0.44%, AVN was 0.1% and non-union was 1.2% and in cannulated hip screw group, infection was 0.39%, AVN was 0.06% and non-union was 1.6%. According to p value, in case of AVN was significant other wise non-significant.²³

Regarding time taken for radiological union, out of 45 patients who had complete radiological union of bone, found statistically significant according to p value, where time taken for radiological union was less in DHS with derotation screw group. Average mean \pm SD radiological union time were 13.07 ± 1.498 weeks. Mean \pm SD radiological union time in DHS with derotation screw group was 12.50 ± 1.225 and in cannulated hip screw group was 13.61 ± 1.559 . Union was achieved in both group patients at the 24th week.²²

According to Harris Hip Score criteria 04 categories were subdivided- excellent, good, fair and poor.²⁴ In this study out of 52 patients at 12th month follow up, 24(46.2%) patient's functional outcome was excellent and 21(40.4%) patient's functional outcome was good. In DHS group, 17(68%) patient's functional outcome was excellent and 6(24%) patient's functional outcome was good. In cannulated hip screw group, 15(55.6%) patient's functional outcome was good and 7(25.9%) patient's functional outcome was excellent. According to p value, functional outcome was significantly better in DHS with derotation screw group. A recent study by Chen et al revealed similar result, in both group maximum

patient's functional outcome was good. P value was 0.178, statistically non-significant.²⁵ Another study done by Kaplan et al. (2012) showed the valuation of functional results according to Harris Hip Score revealed, in DHS group, the proportion of excellent and good results was 85% and of fair results 15% and 91% excellent and good results, 6% fair and 3% poor results in cannulated hip screw group.²²

Limitations

It was a single centered study. The follow up period was short in comparable to other series. So, we could not evaluate very late post-operative complications. Due to poor socio-economic condition, maltreatment, misdiagnosis and refusal for operative treatment, sample size could not be more than 60.

Conclusion

Fracture of the neck of femur in adults is relatively unstable with lots of variation management modality worldwide. In this study both fixation by DHS with side plate and de-rotation screw and fixation by cannulated hip screw for femoral neck fracture were compared, which showed that pain, gait, daily activities, range of motion etc. as well as functional outcome was significantly better in DHS with de-rotation screw group than cannulated hip screw group. Complication associated with these two techniques were minimum and radiological union time was significantly more in cannulated hip screws group than DHS with de-rotation screw group.

Recommendation

Further study with large samples and multicentered are recommended.

Acknowledgements

All the authors express their thanks and gratitude to the all respondents.

Contribution of authors

1. SKS Conception, design, acquisition of data, data analysis, manuscript writing and final approval.
2. HMM- Data analysis, interpretation of data, manuscript writing and final approval.
3. JJ-Acquisition of data, interpretation of data, critical revision and final approval.
4. AD-Data analysis, manuscript writing, final approval.

5. MM-Acquisition of data, critical revision and final approval.
6. SRKG-Data analysis, manuscript writing and final approval.

Disclosure

All the authors declared no competing interest.

References

1. Bergström U, Jonsson H, Gustafson Y, Pettersson U, Stenlund H. and Svensson O. The hip fracture incidence curve is shifting to the right A forecast of the age-quake. *Acta Orthopaedica*. 2009; 80 (5):520–524.
2. Raaymakers EL. Fractures of the femoral neck: a review and personal statement. *Acta ChirOrthop Trauma Cech*. 2006; 73(1): 45-59.
3. Broderick JM, Bruce-Brand R, Stanley E, et al. Osteoporotic hip fractures: The burden of fixation failure. *Sci World J*. 2013: 515197.
4. Wilk R, Skrzypek M, Kowalska M, et al. Standardized incidence and trend of osteoporotic hip fracture in Polish women and men: A nine-year observation. *Maturitas*. 2014; 77: 59-63.
5. Marsh JL, Slongo TF, Agel J, Broderick JS, Creevey W, Decoster TA, et al. Fracture and dislocation classification compendium – 2007: Orthopaedic Trauma Association classification, database and outcomes committee. *J Orthop Trauma*. 2007; 21(10 Suppl): S1-S133.
6. Rogmark C, Flensburg L. and Fredin H. Undisplaced femoral neck fractures – no problems? A consecutive study of 224 patients treated with internal fixation. *Injury*. 2009; 40: 274-276.
7. Angelini M, McKee MD, Waddell JP, et al. Salvage of failed hip fracture fixation. *J Orthop Trauma*. 2009; 23: 471–478.
8. Parker MJ. Results of internal fixation of Pauwels type-3 vertical fracture neck of femur. *J Bone Joint Surg Am*. 2009; 91: 490-491.
9. Bjørgul K. and Reikerås O. Hemiarthroplasty in worst cases is better than internal fixation in best cases of displaced femoral neck fractures. *Acta Orthopaedica*. 2006; 77 (3): 368–374.
10. Bjørgul K. and Reikerås O. Outcome of undisplaced and moderately displaced femoral neck fracture. *Acta Orthopaedica*. 2007; 78 (4): 498–504.
11. Liporace F, Gaines R, Collinge C. and Haidukewych GJ. Results of internal fixation of Pauwels type-3 vertical fracture neck of femur. *J Bone Joint Surg Am*. 2008; 90(8): 1654-1659.
12. Jain R, Koo M, Kreder HJ, Schemitsch EH, Davey JR. and Mahomed NN. Comparison of early and delayed fixation of subcapital hip fractures in patients sixty years of age or less. *J Bone Joint Surg Am*. 2002; 84(9): 1605-1612.

13. Sidhu AS, Walia JPS, Brar BS, Mann HS. and Punia S. A comparative study of 60 cases of intracapsular fracture neck femur treated with multiple cannulated screws and dynamic hip screw. *Pb Journal of Orthopaedics*. 2012; 13(1):49-52.
14. PervezM, Shah I, Ahmed MU. and Shah FH. Treatment of Femoral Neck Fractures with Dynamic Hip Screw in Young Adults. *Biomed J Sci & Tech Res*. 2018; 3(3): 3245-3248.
15. Lindequist S. Cortical screw support in fracture neck of femur. A radiographic analysis of 87 fractures with a new mensuration technique. *Acta Orthop Scand*.1993; 64(3): 289-293.
16. Deneka D, Simonian P, Stankewich C, Eckert D, Chapman J. and Tencer A. Biomechanical Comparison of Internal Fixation Techniques for the Treatment of Unstable Basicervical Femoral Neck Fractures. *Journal of Orthopaedic Trauma*. 1997; 11(5): 337-343.
17. Leighton RK. Fractures of the Neck of Femur. In: Rockwood and Green's Fractures in Adults. Bucholz RW, Heckman JD, Court-brown CM: editors. Philadelphia. Lippincott Williams & Wilkins. 6th ed, 2006; 2: 1753-1792.
18. Jewell DP, Gheduzzi S, Mitchell MS. and Miles AW. Locking plates increase the strength of dynamic hip screws. *Injury*. 2008; 39(2): 209-212.
19. Kyle RF. Operative techniques of fixation for femoral neck fractures in young adults. *Tech Orthop*. 1986; 1: 33.
20. Khoo CCH, Haseeb A. and Singh VA. Cannulated Screw Fixation for Femoral neck Fractures: A 5-year experience In a Single Institution. *Malaysia Orthopaedic Journal*. 2014; 8(2): 14-21.
21. Kuokkanen H, Korkala O, Antti-poika I, Tolonen J, Lethimaki MY. and Silvennoinen T. Three cancellous bone screws versus a screw-angle platein the treatment of Garden I and II fractures of the femoral neck. *Acta OrthopaedicaBelgica*. 1991; 57(1): 53-57.
22. Kaplan T, Akesen B, Demirag B, Bilgen S. and Durak K. Comparative results of percutaneous cannulated screws, dynamic compression type plate and screw for the treatment of femoral neck fracture. *Turkish Journal of Trauma & Emergency Surgery*. 2012; 18 (1): 65-70.
23. Jettoo P. and James P. Dynamic hip screw fixation versus multiple screw fixation for intracapsular hip fracture. *Journal of Orthopaedic Surgery*. 2016; 24(2): 146-149.
24. Harris WH. Traumatic arthritis of the hip after dislocation and acetabular fractures: treatment by mold arthroplasty. An end-result study using a new method of result evaluation. *J Bone Jt Surg Am*.1969; 51: 737-755.
25. Chen C, Yu L, Tang X, Liu M, Sun L, Liu C and Zhang Z. Dynamic hip system blade versus cannulated compression screw for the treatment of femoral neck fractures: A retrospective study. *Acta Orthopaedica et Traumatologica Turcica*. 2017; 51: 381-387.
26. Schwartzmann CR, Lammerhirt HM, Spinelli LF and Neto ASU. Treatment of displaced femoral neck fractures in young patients with DHS and its association to osteonecrosis. *Rev Bras Orthop*. 2017: 11681-11686.