

A Case Report on Kikuchi-Fujimoto Disease: A Rare Lymphohistiocytic Disorder of Unknown Etiology

Mohammad Masud Karim^{1*} Tareak Al Nasir² Pratik Kumar Banik³ Tasnia Hoque³

Abstract

Background: Reported first in 1972, histiocytic necrotizing lymphadenitis, also known as Kikuchi-Fujimoto Disease (KFD), is an infrequent and self-restricting disorder of lymph nodes, predominantly found in the Southeast Asian region. The common presentation of this disease is a young Asian individual presenting with painful cervical lymph node enlargement. Due to this disease's uncommon nature, it is often misdiagnosed by clinicians as Systemic Lupus Erythematosus (SLE) malignant lymphoma, or tuberculosis. Although there are numerous hypotheses about the etiology of this illness being viral or autoimmune in nature, strong evidence is yet to be established. To let our readers to know about the disease so that we can deal patients with lymphadenopathy keeping this rare disease in our mind.

Case Presentation: Here we present A 20 years-old-female hailing from the hill tracts of Bandarban in Bangladesh presented with three months history of right-sided inguinal lymphadenopathy, which was progressive and non-tender in nature. Associated symptom includes low-grade fever. There was no history of night sweats, weight loss, cough and no other group of lymphadenopathies. So, lymphnode biopsy done and report came as Kikuchi-Fujimoto disease. The patient made full recovery with supportive care only.

Conclusion: Fever with lymphadenopathy may be due to wide range of etiologies. Although Kikuchi-Fujimoto disease is rare, it is important to diagnose it accurately. So, we can prevent further costly investigations and imaging at the same time we can avoid potential harmful treatments and psychological stress to the patient.

Key words : Inguinal swelling; Kikuchi-Fujimoto disease; Lymphadenopathy; Pyrexia of unknown origin.

Introduction

Kikuchi-Fujimoto Disease (KFD) also known as histiocytic necrotizing lymphadenitis, is a benign,

sporadic, self-limiting lymphohistiocytic disorder. It was originally described in 1972 by Kikuchi and Fujimoto individually.¹ It is frequently associated with fever and lymph node enlargement, along with some systemic symptoms. The first case was identified in Japan; since then, KFD has been reported from all around the world, with a higher prevalence in Southeast Asia.² The disease was previously thought to be female predominant (Male: female ratio of 1: 4). But recent reports suggest that the actual ratio is closer to 1: 1.³ Typically, the disease affects young adults between the age of 20-30, but the pediatric age groups are also reported to be affected. However, compared to adults, males are more frequently affected than females (1.14: 1) in the pediatric age group.⁴ There is no specific treatment, and management is mainly symptomatic.

Case Presentation

A 20 years old female hailing from the hill tracts of Bandarban in Bangladesh presented with three months history of right-sided inguinal lymphadenopathy, which was progressive and non-tender in nature. Associated symptom includes low-grade fever. There was no history of night sweats, weight loss, cough, upper respiratory tract infections, headache, joint pain, myalgia, rash, or ocular manifestations. There was no history of contact with any Tuberculosis patient. Menstrual history and family history of autoimmune diseases were insignificant. On presentation, the patient was hemodynamically stable with an average Body Mass Index (BMI). The patient was slightly anemic. Blood pressure was recorded at 100/60 mm Hg with a pulse rate of 90/min, regular and of good volume, and respiratory rate was 20 breaths/min. Oral, nasal and ear examination findings were normal. On physical examination, there was lymphadenopathy involving both the inguinal and axillary regions. The right inguinal lymph node was the largest, measuring approximately 4×2 centimeters, whereas other lymph nodes were approximately 0.5×0.5 centimeters. Lymph nodes were firm,

1. Associate Professor of Surgery
Chittagong Medical College, Chattogram.
2. Professor of Lab Medicine
Imperial Hospital Limited, Chattogram.
3. Clinical Research Assistant
Toxicology Society of Bangladesh, Chattogram.

***Correspondence:** Dr. Mohammad Masud Karim
Cell : 01713 10 65 12
E-mail: mkarimctg@gmail.com

Submitted on : 25.05.2021

Accepted on : 24.06.2021

rubbery, and mobile with no inflammatory signs. Abdominal examination revealed no hepatosplenomegaly. Respiratory, cardiovascular and neurological examinations were unremarkable. Initially, a complete blood count and chest X-ray were performed. Complete blood count revealed raised ESR with anemia; other parameters were within the normal range (Table I).

To ensure a definitive diagnosis, surgery with lymph node excision and biopsy was performed from the right inguinal lymph node. The histopathological report revealed features of histiocytic necrotizing lymphadenitis characterized by large areas of necrosis along with nuclear debris surrounded by transformed lymphocytes, histiocytes and plasmacytoid monocytes with no evidence of malignancy (Figure 1, 2). Thus, a definitive diagnosis of histiocytic necrotizing lymphadenitis was made. Subsequently, watchful waiting was advised with supportive treatment (500mg Paracetamol tablet if there is fever) and follow up twice a month to monitor the spread of lymphadenopathy. The disease course was uneventful. Lymphadenopathy and fever resolved gradually within a month with no complications. The patient was scheduled for a six-monthly follow-up and advised to return if there were any symptoms of autoimmune diseases (Rash, joint pain, weight loss or gain etc).

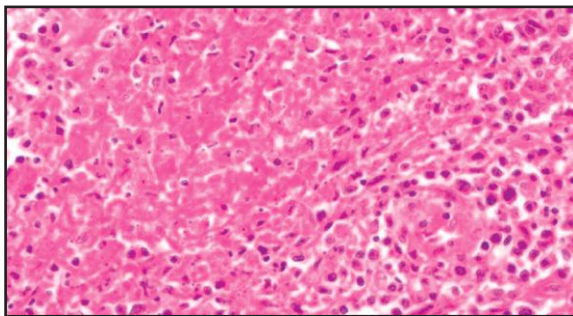


Fig 1 Necrosed area surrounded by transformed lymphocytes, histiocytes and plasma cytoid cells

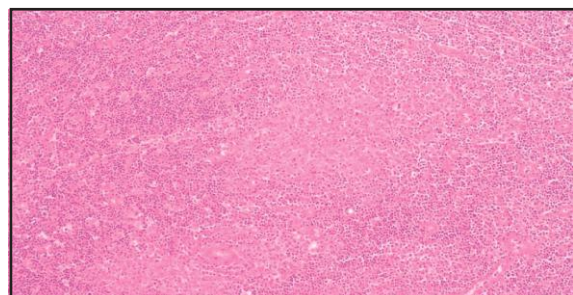


Fig 2 Necrotizing lymphadenitis (Kikuchi-Fujimoto Disease) showing large areas of necrosis with nuclear debris

Table I Lab investigations of respondent

Tests	Result	Reference value
Hemoglobin	10.2 g/dL	Male: 14-18 g/dL Female: 12-16 g/dL
Red blood cells	5.18 million/ul	4.2-6.2 million/ul
Platelets	350,000/Cmm	150,000-450,000/Cmm
White blood cells	6,800/Cmm	4,000-11,000/Cmm
Neutrophil	62%	40-75%
Lymphocyte	27%	20-45%
Monocyte	3%	2-8%
Eosinophil	8%	1-6%
Basophil	0%	0-1%
PCV (Hct)	32.2%	Male: 47-54% Female: 37-47%
ESR	40 mm	Male: 0-10 mm Female: 0-15 mm
MCV	62.2 fL	76-96 fL
MCH	19.7 pg	26.6-33.5 pg
MCHC	31.7 g/dL	31.4-38.5 g/dL

Discussion

There are many hypotheses about KFD, but none of them is confirmed yet. The theories indicate that the disease may be related to viral infection or autoimmune process. Organisms such as Epstein-Barr virus, cytomegalovirus, varicella-zoster virus, human herpes virus-6, human immunodeficiency virus, *Yersinia enterocolitica*, and *Toxoplasma gondii* were investigated, but no correlation could be established.⁵ Some literature speculated that KFD is a hyperimmune condition triggered by virus-infected transformed lymphocytes. This hypothesis depends on the histopathological highlights of the illness, which are like those seen in viral diseases.⁶ KFD has been reported to have association with SLE, Still's disease, Wegener's granulomatosis, Graves' disease, Sjogren's disease, Hashimoto's Thyroiditis.^{7,8} Pathogenesis of KFD is still poorly understood, but it has been suggested that KFD represents an exuberant T-cell-mediated immune response to various antigens in genetically susceptible people.² Human Leukocyte Antigen (HLA) class II alleles, specifically HLA-DPA1 and HLA-DPB1 have been frequently found in Asian KFD patients, which is extremely rare in other ethnicities.⁹ The most common presentation of KFD is lymphadenopathy (100%). The affected nodes are usually unilateral, firm, tender, mobile, non-fluctuant, non-draining. Although the cervical

nodes are commonly involved, our patients had enlarged non-tender inguinal nodes. Axillary or supraclavicular lymph nodes can also be involved. The onset is acute or subacute, developing within a few days or weeks.¹⁰ Lymphadenopathy is frequently accompanied by low-grade fever (35%). Other common symptoms include- fatigue (7%), joint pain (7%), anemia (23%), erythematous rash (10%).⁵ Occasionally, weight loss, nausea, vomiting, sore throat, and night sweats can be seen.¹⁰ Very rarely, hepatomegaly (3%) and splenomegaly (2%) have been reported in an analysis of 244 cases.⁵ Younger children can sometimes present with neurological symptoms (11%) resembling aseptic meningitis or encephalitis.^{11,5} Some reports described ocular symptoms like- oculomotor palsy with papillary edema, conjunctival injection with mild bilateral anterior uveitis.¹² Of all these clinical features, our patient presented with fever, lymphadenopathy and mild anemia. If the anemia should not be considered significant or not is uncertain as young girls from poor socio-economic populations of Bangladesh commonly suffer from a mild degree of nutritional anemia.

Hematological findings of KFD reveal mild granulocytopenia, lymphocytosis, and thrombocytopenia.¹³ Although these lab values were normal in our patient, anemia was present. Lactate Dehydrogenase (LDH) C-reactive Protein (CRP) and Erythrocyte Sedimentation Rate (ESR) can be elevated. Lab values may show decreased complement level.⁵ Autoimmune antibody studies including antinuclear antibody (ANA), Rheumatoid Factor (RF) and anti-ds DNA are usually negative, which helps in differentiation from other autoimmune diseases. Although in our case, the autoimmune panel was not done due to the patient's poor socio-economic condition, rather a direct approach to diagnosis by excisional biopsy was done by the surgeon. Ultrasound study of enlarged lymph node shows features of echogenic hilum, absence of internal calcification and necrosis with a regular vascular pattern. These are typical features of Kikuchi disease.¹⁴ Fine Needle Aspiration (FNA) can aid in diagnosis with an accuracy of 56.75%.¹⁵ But a definitive diagnosis can be made by lymph node biopsy and histological examination. Microscopically, there is focal and well-circumscribed paracortical necrosis. The degree of necrosis may vary from

patient to patient. But there is abundant karyorrhectic debris, scattered fibrin deposits, and collection of mononuclear cells with cellular debris.¹⁶ The primary lesional cells are histiocytes (CD68 and CD163+), which are involved with the aggregates of plasmacytoid dendritic cells (TCL1 and CD123+).¹⁷

Several diseases can be considered as a differential diagnosis of Kikuchi disease, such as - cat scratch disease, Epstein-Barr virus, Infectious Mononucleosis, Kawasaki disease, leprosy, SLE, sarcoidosis, syphilis, Toxoplasmosis, tuberculosis etc. An absence of neutrophils in areas of necrosis and lack of follicular lymphoid hyperplasia differentiate Kikuchi from cat scratch disease and other bacterial infections. Presence of hematoxylin bodies, plasma cells, and neutrophils rules out SLE. Incomplete architectural effacement with patent sinus, plasmacytoid dendritic cells at the periphery of lesions with low mitotic activity and the absence of Reed - Sternberg cells can rule out malignant lymphoma.¹⁸ Clinically KFD can closely resemble the clinical features of TB, so often, the patients are wrongfully started on anti-TB medications. This can be easily avoided by histological analysis of the affected lymph node.

KFD is a benign, self-limiting disease that usually doesn't require treatment. In mild form of the disease, treatment mainly focuses on relieving symptoms. Rest, analgesic, and antipyretics should alleviate the fever and lymph node tenderness. In case of asymptomatic disease, only observation has proven to be sufficient. Patients with extra nodal involvement, such as - CNS, eyes, or skin involvement can benefit from a short corticosteroid regimen.¹⁹ In a child with symptomatic KFD, rapid response to hydroxychloroquine has also been reported.²⁰ Surgical intervention may be necessary to make a confirmatory diagnosis by excisional biopsy of affected lymph node.

Being a benign disease, KFD has a good prognosis. It usually resolves within 1 to 4 months.¹⁰ However, an analysis of 244 cases of KFD has reported a mortality rate of 2.1%.⁵ So far, 4 deaths have occurred from KFD-triggered hemophagocytic syndrome, pulmonary hemorrhage, anemic heart failure, and multiorgan failure. These patients were immunosuppressed, and there were probably other factors involved in their fatal prognosis.

After analyzing approximately 800 cases, the recurrence rate of KFD is estimated at less than 10%.¹⁹ Recurrence can occur as long as 8 years after the initial presentation.² Also, there is a risk of developing other autoimmune conditions. 4 cases are reported where patients developed SLE after 4-13 months of diagnosis with KFD.²¹ So, a long-term follow-up should be implemented for KFD patients.

Limitations

Most important limitations of this study were language problem. We had to take help of a translator to communicate with the patient as the patient cannot speak in Bangla language properly. The other limitation was the patient came from a remote area of hill tract where well transport and mobile network were not available. So, we could not follow up exactly in time as we expected.

Conclusion

This case represents an unusual cause of lymphadenopathy with low-grade fever in a young girl residing in hill tracts (Bandarban, Bangladesh). Ethnicity, traveling history, and concurrent presence of autoimmune disease - these factors are yet to be established in such cases. Though Kikuchi-Fujimoto Disease is a rare and relatively benign disease, sometimes clinical features are often mistaken as other common infectious diseases. This sometimes leads to symptomatic treatment of such patients rather than definitive diagnosis considering the socio-economic background of developing countries.

Recommendation

Priority should be given to establishing the definitive diagnosis, which will prevent harmful costly treatments and psychological stress to the patient, as well as help us to show more detailed information of this disease in the future.

Acknowledgments

We wish to thank Delta Health Care Chittagong Limited and Imperial Hospital Limited for playing a crucial role in the diagnosis and management of this patient.

Consent

Written informed consent was obtained from the patient to publish her clinical details and clinical images. Necessary permission was taken from the both authorities before begins the study.

Contribution of authors

MMK-Conception, design, critical revision & final approval.

TAN-Critical revision, drafting & final approval.

PKB-Manuscript writing, citing references & final approval.

TH-Critical revision, citing references & final approval.

Disclosure

All the authors declared no competing interests.

References

1. Kikuchi-Fujimoto Disease: A Review. Anamarija M. Perry, Sarah M. Choi. Archives of Pathology and Laboratory Medicine. 2018;142:1341-1346.
2. Enigmatic Kikuchi-Fujimoto disease: a comprehensive review. Xavier Bosch, Antonio Guilabert, Rosa Miquel, Elias Campo. American journal of clinical pathology. 2004;122:141-152.
3. Kikuchi's Disease: A Review and Analysis of 61 Cases. Lin HC, Su CY, Huang CC, Hwang CF, Chien CY. Otolaryngol Head Neck Surg. 2003;128, :650-653.
4. Characteristics of Kikuchi-Fujimoto disease in children compared with adults. Tae Yeun Kim, Kee-Soo Ha, Yunkyung Kim, JungHwa Lee, KwangChul Lee, JooWon Lee. European Journal of Pediatrics. 2014;173: 111-116.
5. Kikuchi-Fujimoto Disease: Analysis of 244 cases. Yasar Kucukardali, Emrullah Solmazgul, Erdogan Kunter, Oral Oncul, Sukru Yildirim, Mustafa Kaplan. Clinical Rheumatology. 2007;26:50-54.
6. Kikuchi-Fujimoto Disease: A Rare Cause of Fever in the Returning Traveller. Matthew R. Wilson, Gordon Milne, Evangelos Vryonis. Case Reports in Medicine. 2014.
7. Kikuchi-Fujimoto disease: A review. A. M. Perry, S. M. Choi. Archives of Pathology and Laboratory Medicine. 2018;142:1341-1346.
8. SLE developing in a follow-up patient of Kikuchi's disease: A rare disorder. A. Patra, S. K. Bhattacharya. Journal of Clinical and Diagnostic Research. 2013;7:752-753.
9. DNA typing of HLA class II genes (HLA-DR, -DQ and -DP) in Japanese patients with histiocytic necrotizing lymphadenitis (Kikuchi's disease). T Tanaka, M Ohmori, S Yasunaga, K Ohshima, M Kikuchi, T Sasazuki. Tissue Antigens. 1999;54:245-253.
10. Kikuchi-Fujimoto disease. Xavier Bosch, Antonio Guilabert. Orphanet Journal of Rare Diseases. 2006;1.
11. Histiocytic necrotizing lymphadenitis (Kikuchi-Fujimoto disease) with CNS involvement in a child. Luís F. Gonçalves, Larisa V. Debelenko, Kanta J. Bhambhani, Andrea Scheid and Deniz Altinok. Pediatric Radiology. 2014; 44:234-238.

12. Kikuchi's disease and ocular manifestation. F Rocher, B Pelosse, M Momtchilova, L Laroche. *Journal Français D'Ophthalmologie*. 2006;29: 932-936.
13. Kikuchi -Fujimoto's disease associated with systemic lupus erythematosus: Difficult case report and literature review. B Ruaro, A Sulli, E Alessandri, G Fraternali-Orcioni, M Cutolo. *Lupus*, 2014;23:939-944.
14. Comparison of ultrasonographic findings of Biopsy-Proven Tuberculosis Lymphadenitis and Kikuchi Disease. Inseon Ryoo, Sangil Suh, Young Hen Lee, Hyung Suk Seo, Hae Young Seol. *Korean Journal of Radiology*. 2015;16:767-775.
15. Diagnosing Kikuchi disease on fine needle aspiration biopsy : A retrospective study of 44 cases diagnosed by cytology and 8 by histopathology. T R Tong, O W Chan, K C Lee. *Acta cytologica*. 2001;45: 953-957.
16. Bone marrow necrosis in children with malignant disease. C H Pui, S Stass, A Green. *Cancer*. 1985;56:1522-1525.
17. A pathologist's view of the bone marrow. Rywlin, A M. 2, February 1980, *The Journal of the Florida Medical Association*. 1980;67:121-124.
18. Guidelines for the diagnosis and treatment of chronic lymphocytic Leukaemia :a report from the International workshop on Chronic Lymphocytic leukemia updating the National Cancer Institute- working group 1996 guidelines. Michael Hallek, Bruce D Cheson, Daniel Catovsky, Federico Caligaris-Cappio, Guillaume Dighiero, Hartmut Döhner, Peter Hillmen, Michael J Keating, Emili Montserrat, Kanti R Rai, Thomas J Kipps, International Workshop on Chronic Lymphocytic Leukemia. 2008; 111: 5446-5456.
19. Pathogenesis, Diagnosis, and Management of Kikuchi–Fujimoto Disease. Darcie Deaver, Pedro Horna, Hernani Cualing, Lubomir Sokol. *Cancer Control*. 2014;313-321.
20. Kikuchi-Fujimoto disease: An amazing response to hydroxychloroquine. Po-Hung Chen, Yung-Feng Huang, Chia-Wan Tang, Shue-Ren Wann, Hong-Tai Chang. *European journal of pediatrics*. 2010;169:1557-1559.
21. Association of Kikuchi–Fujimoto's disease with SLE. F. Goldblatt, J. Andrews, A. Russell, D. Isenberg. *Rheumatology*. 2008;47:553–554.