

WEGENER'S GRANULOMATOSIS : CASE REPORT

Pradip Kumar Dutta ^{1,6} Sayed Md Javed ^{2,6} Md Nurul Huda ^{3,6} Saibal Das ³ Md Manirul Islam ⁴
Dipen Chowdhury ⁴ Md Shariful Islam ⁴ Merina Arjumand ⁵ Rabiul Alam Md Erfan Uddin ⁵

Summary

Wegener's granulomatosis (WG) is an uncommon small vessel vasculitis characterized by necrotizing granulomatosis of the upper and lower respiratory tract and glomerulonephritis. We describe a case of a 28 year old man with symptoms of pansinusitis who later developed renal features of WG, so that disease was diagnosed long 3 years after pansinusitis symptoms. This case report emphasizes early diagnosis and treatment to avoid fatal outcome.

Introduction

Wegener's granulomatosis (WG) is one of systemic vasculitides mainly characterized by granulomatous inflammation of upper and lower respiratory tract and glomerulonephritis though it can affect any organ of the body¹. Its hallmark features include necrotizing granulomatous inflammation and pauci-immune vasculitis in small and medium sized blood vessels. We report a case who has history of recurrent sinusitis, but diagnosis of WG is delayed for 2-3 years till he developed renal failure. Literature showed if left untreated WG may cause >90% mortality within 2 years², yet this case responded well to immunosuppressive agents.

Case report

A 28 year old non-smoker male was admitted in the department of Nephrology of Chittagong Medical College with flitting polyarthralgia chiefly involving large joints, cough and occasional haemoptysis. He received NSAIDs and antibiotics in several settings without significant improvement of any of his symptoms. Besides this, he has been suffering from

recurrent rhinorrhoea and sinusitis with occasional epistaxis for last 2-3 yrs. He was diabetic for 1 yr. and was on diet.

During admission, he looks pale, non-icteric, non-edematous, having no lymphadenopathy or bony tenderness, pulse-100/min, BP-130/70, Temp-100°F, R/R- 22/min. Grade-2 tenderness was present over joints without evidence of arthritis. Chest auscultation revealed coarse crepitations in both lung fields, more on right lower area. No cardiac or neurological abnormality or any organomegaly was detected on further examination. Nasal examination only revealed septal deviation to the right with no tenderness over sinuses.

Initial investigations revealed Hb% 8.5g/dl, ESR- 129 mm in 1st hr, WBC-12000/cmm with 76% neutrophil and 3% eosinophil & normocytic normochromic anaemia on PBF. Urine routine examination revealed 1+ albumin and 10-15 RBC/HPF; S. creatinine 1.7 mg/dl. CXR showed bilateral patchy opacity involving middle and lower zone of both sides. Anti pr3 Ab (c-ANCA) was positive with titre 5.42 (Index<1.10). p-ANCA and ANA was negative. X-Ray PNS showed DNS (rt.) with bilateral hypertrophy of turbinates. USG of the whole abdomen revealed normal. Further investigation a week later confirmed persistently raised ESR (125mm), progressive haematuria (20-30 RBC/HPF) and rising creatinine (2.2mg/dl). Renal biopsy was done with inconclusive histological report but no immune deposition was noted on immunofluorescence study.

In view of the above clinical and laboratory criteria (sinusitis, high ESR, positive c-ANCA and microscopic haematuria) patient was labeled as Wegener's Granulomatosis and treatment with steroid and cyclophosphamide was commenced. Patient was clinically improved supported by rapid decline in ESR to 20 mm and disappearance of RBC in urine 15 days after treatment had been started. CXR showed decreasing size of opacification (Fig 1 & 2). From that time till now he had no relapse.

1. Associate Professor of Nephrology
Chittagong Medical College, Chittagong
2. Honorary Medical Officer of Nephrology
Chittagong Medical College & Hospital, Chittagong
3. Assistant Professor of Nephrology
Chittagong Medical College, Chittagong
4. MD (Nephrology) Thesis part student
Chittagong Medical College & Hospital, Chittagong
5. Indoor Medical Officer of Medicine
Chittagong Medical College & Hospital, Chittagong
6. These authors contributed equally to this work

Correspondence : Dr Pradip Kumar Dutta
email: duttaprd@gmail.com

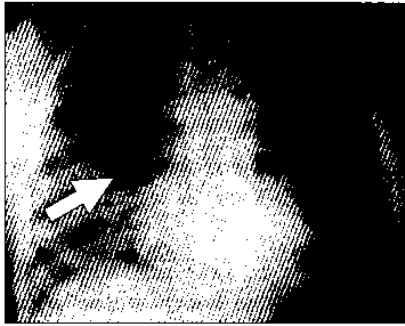

Fig 1 : Consolidation in right lower zone of chest (arrow)

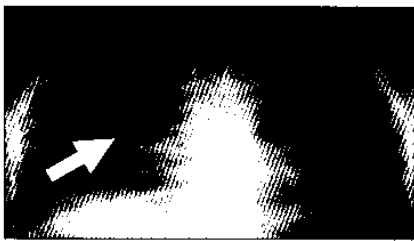

Fig 2: Clearance of opacification of right lung (arrow) after treatment

Discussion

WG was first described by Klinger in 1933, followed by other investigators, including Rossle in 1933, Wegener in 1936 and 1939, and Ringertz in 1947¹.

WG is currently characterized as one of the ANCA-associated small vessel vasculitides. It is distinguished clinically by its predilection for affecting the upper and lower respiratory tracts and kidneys and by the histologic presence of necrosis, granulomatous inflammation, and vasculitis (Fig 3). It is uncommon, with a reported incidence of three per 100,000¹. Most patients are white, slight male preponderance, and most present in the fifth decade, although the age range extends to both extremes³. Our case is younger one (28) and is Asian. Chronic sinusitis is the most common initial complaint (67%); failure to respond to conventional treatment is suggestive⁴. Rhinitis and epistaxis occur in 22% and 11% of patients with WG, respectively⁴. Pulmonary disease may cause pulmonary infiltrates (71%), cough (34%), hemoptysis (18%), chest discomfort (8%), and dyspnea (7%)⁴. Diffuse alveolar hemorrhage (DAH) due to alveolar capillaritis is reported in 5%-45% of cases⁵. Renal disease is present in 17% at initial diagnosis and is usually asymptomatic⁴. Renal failure occurs in 11% at presentation⁴. Arthralgia, myalgia and/or arthritis occurred in two-third of patients and 28% had

nonerosive and nondeforming polyarthritis⁶. Neurologic symptoms are less common, but have been reported in approximately one third of patients, usually as a sensorineural hearing loss⁷. There is a strong and specific association with autoantibodies directed against proteinase 3, a constituent of neutrophil azurophilic granules⁸. In 1990, the American College of Rheumatology (ACR) proposed specific criteria for the classification of WG. Two of the following four criteria are required to meet the ACR classification for WG-

- Nasal or oral inflammation- Development of painful or painless oral ulcers or purulent or bloody nasal discharge
- Abnormal chest radiography findings- Chest radiograph showing nodules, fixed infiltrates, or cavities
- Urinary sediment- Microhematuria (>5 RBCs per HPF) or RBC casts in urine sediment
- Granulomatous inflammation on biopsy- Histologic changes showing granulomatous inflammation within the wall of an artery or in the perivascular or extravascular area⁹

The presence of autoantibodies to proteinase 3/ (cANCA) is not required for diagnosis of WG, by either ACR or Chaper Hill consensus Conference (CHCC) definition¹⁰. Though few patients can develop pANCA but according to the WGET trial, positive c-ANCA results in 88% of all patients of WG. Occasionally, patients with infection, inflammatory bowel disease, rheumatic disease, neoplasm develop ANCA¹¹

Our patient initially presented with sinusitis and later on non-specific polyarthralgia which drew attention towards connective tissue disease. His history of rhinitis and epistaxis, cough with haemoptysis along with high ESR (129mm), patchy infiltration in CXR and renal involvement (20-30 RBC/HPF) strongly suggest WG which was further confirmed by positive cANCA directed against proteinase 3. Though it is difficult to ascertain when renal involvement occurred, yet probably there was a gap between respiratory and renal involvement, so that our patient responded even 3 years after initial manifestation. And also younger age and non-Caucasian race may be of favorable prognosis. Although renal biopsy was inconclusive but absence of immune deposition by IF support diagnosis of ANCA associated GN. Respond to specific therapy further supported our diagnosis.

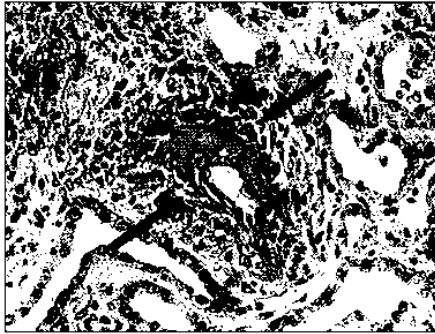


Fig 3: Focal necrotizing extracapillary glomerulonephritis. Fibrinoid material is red (red arrow)
 Source : www.ndteducational.org/ferrarioanca.asp

Limitations

Gold standard test to diagnose WG is histological findings of granuloma or necrotizing vasculitis. Biopsy was not done of upper respiratory tract, nor renal histopathology could show necrotizing lesion.

Conclusion

This report emphasized that Wegener's granulomatosis must be considered in a patient of multisystem involvement even though classified in the group of rare pulmonary diseases. If left untreated the disease can be fatal and within 5 months mortality is 50%¹². Early diagnosis and treatment can prevent renal failure, which is the most common cause of death¹³. Prompt institution of immunosuppressive drug therapy, including steroids and cyclophosphamide, results in remission of the disease in more than 90% of patients⁴.

Disclosure

All the authors declared no competing interestes.

References

1. Langford CA., Hoffman GS. Wegener's Granulomatosis; Thorax 1999; 54 :629-637
2. Khaled Shafiei, MD, Euil Luther, MD, Michael Archie, MD, Janis Gulick, MD and Marjorie R. Fowler, MD. Wegener Granulomatosis: Case Report and Brief Literature Review. The Journal of the American Board of Family Practice 2003; 16: 555-559
3. Hoffman GS, Kerr GS, Leavitt RY, Hallahan CW, Levovics RS, Traris WD et al. Wegener granulomatosis: an analysis of 158 patients. Ann Intern Med 1992; 116: 488-498
4. Fauci AS, Haynes BS, Katz P, Wolff SM. Wegener's granulomatosis: prospective clinical and therapeutic experience with 85 patients for 21 years. Ann Intern Med. 1983; 98: 76-85
5. Manganelli P, Fietta P, Carotti M, Pesci A, Salaffi F. Respiratory system involvement in systemic vasculitis. Clin Exp Rheumatol. 2006; 24: 48-59
6. Noritake DT, Weiner SR, Bassett LW, Paulus HE, Weisbart R. Rheumatic manifestations of Wegener's granulomatosis. J Rheumatol 1987 Oct; 14: 949-951
7. Takwoingi YM, Dempster JH. Wegener's Granulomatosis: An analysis of 33 Patients Seen Over a Ten Year Period. Clin Otolaryng 2003; 28: 187-194
8. Hewins P, Tervaert JW, Savage CO, Kallenberg CG. Is Wegener's granulomatosis an autoimmune disease? Curr Opin Rheumatol 2000; 12: 3-10
9. Leavitt RY, Fauci AS, Bloch DA, Michel BA, Hunder GG, Arend WP, et al. The American College of Rheumatology 1990 criteria for the classification of Wegener's granulomatosis. Arthritis Rheum 1990; 33: 1101-1107
10. Sorensen SF, Slot O, Tvede N, Petersen J. A prospective study of vasculitis patients collected in a five years period evaluation of the Chapel Hill nomenclature. Ann Rheum Dis 2000; 59: 478-482
11. Al Maini M, Carette S. Diagnosis of Wegener's Granulomatosis in the ANCA Era. The Journal of Rheumatology 2006; 41: S48-S59
12. Kaneishi NK, Howell LP, Russell LA, Vogt PJ, Lie JT. Fine needle aspiration cytology of pulmonary Wegener's granulomatosis with biopsy correlation. Acta Cytol 1995; 39: 1094-1100
13. Mark EJ, Matsubara O, Tan-Liu NS, Fienberg R. The pulmonary biopsy in the early diagnosis of Wegener's (pathergic) granulomatosis: a study based on 35 open lung biopsies. Hum Pathol 1998; 19: 1065-1071