

## TUBERCULOSIS - SARCOIDOSIS ASSOCIATION : A CASE REPORT

Asok Kumar Dutta<sup>1</sup> Pradip Kumar Dutta<sup>2</sup> A S M Zahed<sup>3</sup> Suman Chowdhury<sup>4</sup> Maruf Bin Habib<sup>5</sup>

### Summary

*The association of tuberculosis and sarcoidosis is rare and its differentiation is some times is very difficult. Here we will be going to present a case initially consulted for generalized lymphadenopathy accompanied by splenomegaly, prolonged high fever, cough & radiologically minimal pulmonary opacity suggestive of pneumonitis. Initially histopathological examination revealed granulomatous lesion compatible with tuberculosis. As there was no significant improvement after 1 month of antitubercular therapy(ATT) rebiopsy of lymph node from another site was done which showed both caseating & noncaseating granulomata and he was advised to continue ATT. After 4 months of intake of ATT he became afebrile but his general conditions deteriorated, so he was given steroid(prednisolone 20mg/day for 2 months along with ATT. He was gradually improving. After 12 months of ATT, he developed chin & lower lip nodules histopathology of which showed non-caseating granulomata. Angiotensin converting enzyme(ACE) level raised more than four fold from its normal value. He was supposed to be suffering from sarcoidosis ATT was stopped & put on only oral steroid therapy 60 mg/day appropriate for sarcoidosis. On subsequent follow up after one month he showed dramatic improvement with remission of fever, cough, gaining in weight, complete disappearance of lymph node, spleen & skin nodules. Henceforth this is probably a case of tuberculous sarcoidosis which is rarely documented in literature in our subcontinent.*

### Key words

Tuberculous sarcoidosis; caseating granuloma; non caseating granuloma

### Introduction

Clinico-radiological features and epithelioid granulomata are common in both sarcoidosis and tuberculosis.

1. Associate Professor of Medicine  
Chittagong Medical College, Chittagong
2. Associate Professor of Nephrology  
Chittagong Medical College, Chittagong
3. Assistant Professor of Medicine  
Chittagong Medical College, Chittagong
4. Medical Officer of Medicine  
Chittagong Medical College Hospital, Chittagong
5. Assistant Professor of Medicine  
Uttara Adhunik Medical College, Dhaka

**Correspondence:** Dr Asok Kumar Dutta

email : asokdutta@yahoo.com

While tuberculosis has an known etiological agent mycobacterium tuberculosis, etiology of Sarcoidosis continues to baffle us<sup>1</sup>. Some times there is a diagnostic dilemma because of remarkably similar clinical, radiological histopathological and immunological aspects. There were sporadic case reports of occurrence of both diseases in same patients. Chronologically it may be either: concomitant occurrence, sarcoidosis followed by tuberculosis or tuberculosis followed by sarcoidosis<sup>2,3,4</sup>. The term known as "Tuberculous Sarcoidosis" was introduced by Scadding in 1962<sup>5</sup>. The weakened tuberculous pathogenicity and altered immune defense mechanism in select individuals results in noncaseating granulomatous sarcoidosis instead of the usual caseating granulomatous tuberculosis. It is a state of transition through which tuberculosis demerges and evolves as sarcoidosis<sup>6</sup>. Tuberculous sarcoidosis has clinical manifestation of both diseases but the course is different and so also the treatment which is the combination of steroids in large doses prescribed for the specific treatment of sarcoidosis with anti tubercular drugs. Here we are reporting a case which was initially treated as tuberculosis with partial improvement but later on treated with specific treatment of sarcoidosis with full recovery. So this may be a case of tuberculous-sarcoidosis association or tuberculosis evolving into sarcoidosis.

### Case report

A 27 year old male on 27-10-09 presented with multiple swelling in left side of neck & left upper arm for last 5 years which increases in number & size involving both sides of neck, axilla & inguinal regions for last 1 month. He suffered from low grade fever, undue weakness and anorexia for last 6 months. And in last one month he lost significant weight and developed persistent dry cough, itching, excessive watering & excess mucus formation in both eyes. He is known asthmatic since his childhood. He had taken multiple antibiotics & other medications for relief of cough, fever & swelling without any improvement. On examination his height was 5ft 8 inch & weight was 52 kg. He was febrile, mildly anemic & ill looking. There was no jaundice, cyanosis & clubbing. He had multiple lymph nodes of variable sizes & shapes involving both sides of neck, axilla, arms & inguinal regions.

The lymph nodes were non tender, firm, & not fixed to underlying structures, overlying skin was free. There was no sinus & fistula. There was no bony tenderness. In chest, there was bilateral fine ronchi & few scattered creps in right upper & mid zones. Cardiovascular system showed no abnormality. Liver was palpable 4 cm from mid clavicular line which was non tender, firm, smooth surface with rounded border. Spleen was 5 cm from midclavicular line which was firm, & smooth. There was no ascites. Laboratory investigations revealed TC of WBC 8,400/cmm, Hb-12.6 gm/dl, ESR-05 mm 1st hour. DC of WBC – Neutro:62%, Lymph: 30%, Eosino:06%, Mono:02%. PBF-Non specific findings. FBS: 70 mg/dl, SGPT-41U/L, S. alkaline phosphatase- 60 IU/L S. creatinine-1mg/dl, serum FT3-3.95pmol/L (Normal range 2.80-7.10 pmol/L), Serum FT4-20.65 pmol/L (12-22 pmol/L), serum TSH- 1.65microIU/L (.27-4.20 microIU/L), S. Ca =8.5 mg/dl. Hb electrophoresis showed normal hemoglobin study. Serologies for hepatitis B, C & HIV was negative. Urinalysis was normal. Tuberculin test: Negative (00 mm). Cx-R P/A view showed indistinct opacities in both lungs suggestive of bilateral pneumonitis (Fig-1). Because of non productive cough no sputum examination was possible. Patient failed to do CT scan of chest. USG of abdomen showed moderate hepatosplenomegaly with lymphadenopathy. Cervical Lymph node biopsy showed multiple epitheloid granulomata & fibrosis without caseation compatible with tuberculosis. On the basis of this above clinical findings & laboratory investigations after ten days of presentation he was given a course of antitubercular therapy (Cat-1) consisting of Rifampicin- 600mg/d, INH-300mg/d, Pyrazinamide-1500mg/d, Ethambutol-1000mg/d along with Pyridoxin-20mg/d for 2 months. After one month repeat chest x-ray showed no radiological improvement. He was then advised to do another lymph node biopsy for histopathology from another site. Tissue was sent for histopathology in two different histopathologist. One report showed multiple epitheloid granulomata, caseation necrosis & fibrosis compatible with tuberculosis. Another report revealed both caseating & non caseating granulomas. So he was advised to continue anti TB therapy. On follow up after four months he reported that fever was subsided but he developed loose motion & his general condition was deteriorating. Stool R/E report was within normal limit. Barium follow through x-ray of small gut showed normal finding. He was then advised to take tab prednisolone 20 mg daily in addition to anti TB drugs.

After a few days the no & sizes of lymph nodes was decreased & he remained afebrile. Follow up after one year revealed that he developed few pinkish nodules involving the chin & lower lips (Fig-2). An x-ray chest P/A view was advised which showed increased in bilateral lung opacity (Fig-2). Excision biopsy was done from chin nodule which showed non-caseating granulomatous inflammation (Fig-4) ACE levels were 284u/lit (8-65). After thirteen months the antitubercular drug was stopped & the dose of prednisolone increased to 60 mg daily. On further follow up one month later he showed marked clinical improvement. Pt remained afebrile, appetite was increased, he gained 3 kg of wt, lymph nodes were completely disappeared, chin nodule disappeared, loose motion stopped. Till to date he remained asymptomatic without any relapse with maintenance dose of steroid (15mg/day).

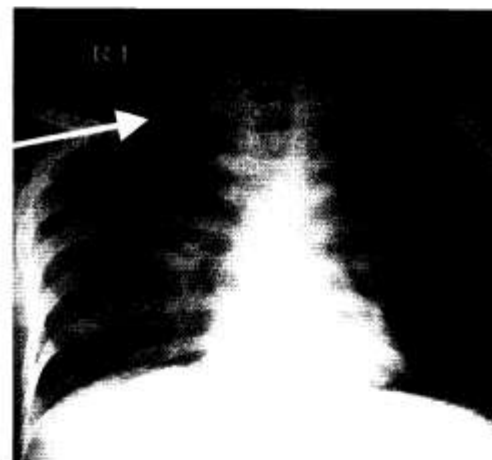


Fig 1: CXR-P/A view showing patchy Opacity in upper zone

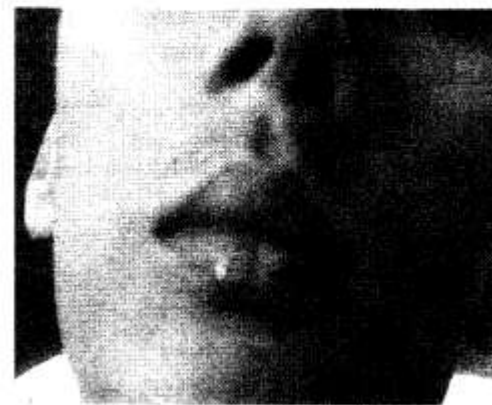
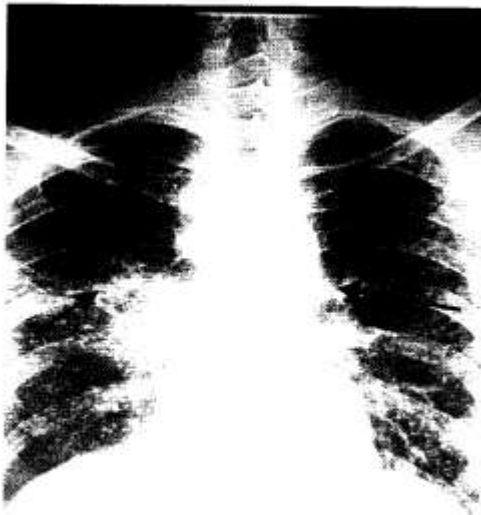
Fig 2 : Chin nodule



**Fig 3:** CXR P/A view showing bilateral extensive patchy opacity



**Fig 4:** Histopathology of Chin nodule showing non-caseating granuloma

#### Discussion

The initial presenting features of patient which includes long standing fever, dry cough, anorexia, weight loss and generalized lymphadenopathy arouses suspicion of tuberculosis. This suspicion is further strengthened by presence of opacity in chest x-ray and histopathological findings of presence of granuloma with fibrosis compatible with tuberculosis.

There is no visible improvement after intake of 4 months of antitubercular therapy. The subsequent histopathology report showed presence of both caseating and noncaseating granuloma. Granulomas are seen in a wide variety of diseases, both infectious and non-infectious<sup>7</sup>. Infections that are characteristic of granulomas include tuberculosis, leprosy, histoplasmosis, cryptococcosis, coccidioidomycosis, blastomycosis and cat scratch disease. Examples of non-infectious granulomatous diseases are sarcoidosis, Crohn's disease, berylliosis, Wegener's granulomatosis, Churg-Strauss syndrome, pulmonary rheumatoid nodules. The granulomas of tuberculosis tend to contain necrosis ("caseating tubercles"), but non-necrotizing granulomas may also be present. Sarcoidosis is a disease of unknown cause characterized by granulomas in multiple organs and body sites<sup>8</sup>. The granulomas of sarcoidosis are similar to the granulomas of tuberculosis and other infectious granulomatous diseases. However, in most cases of sarcoidosis, the granulomas do not contain necrosis and are surrounded by concentric scar tissue (fibrosis). After getting 4 months of antitubercular therapy the fever was subsided but overall general condition was deteriorated. The condition was little improved after receiving oral steroid in lower doses. The condition was further complicated by appearance of skin nodules in chin histopathology of which showed non caseating granuloma. There was also increase in bilateral lung opacity. There was more than four fold rise in blood levels of ACE enzymes. All these findings favoured sarcoidosis. Many clinicians in the Europe believed that sarcoidosis was related to tuberculosis. Pinner<sup>9</sup> had earlier reported that acid fast bacilli were occasionally found in sarcoidosis but that normally they were rapidly destroyed. Sadding<sup>5</sup> reported that 34 cases of tuberculous sarcoidosis. In 5 cases sarcoidosis followed by caseating tuberculosis. In remaining 18 cases tubercular bacilli were isolated during the course of sarcoidosis although clinical, immunological and radiological features remained characteristic of sarcoidosis. In our case the initial features were in favour of tuberculosis but there was little improvement after getting antitubercular drugs. Further improvement was observed after receiving 20 mg of steroids daily in addition to ATT. But remarkable improvement only occurred after receiving high doses of steroid which was appropriate for sarcoidosis.

Wong et al<sup>4</sup> reported a case of sarcoidosis in a patient previously treated for tuberculosis and showed that one of the mechanism of developing sarcoidosis is a continued reaction of mycobacterium tuberculosis. In his case the patient was histologically and bacteriologically confirmed as tubercular lymphadenitis. After 15 months of antitubercular drug and despite resolution of lymph nodes, developed exertional dyspnea. Histologically findings from tissue obtained via transbronchial biopsy and open lung biopsy proved sarcoidosis but also showed the presence of mycobacterium DNA by PCR. She subsequently showed good response clinically, radiologically, biochemically after one year of corticosteroid treatment for her sarcoidosis and remained relapse free afterwards. Based on the chronological progression of our presenting case, initial presence of granuloma in lymph node, later appearance of both caseating and non caseating granuloma, dramatical response after high dose steroid therapy and review of literatures, we believe that our patient initially had tuberculosis which ultimately evolved as sarcoidosis.

#### **Conclusion**

The reported case is an example of tuberculous sarcoidosis association or tuberculosis evolving into sarcoidosis. So in a granulomatous lesion with partial improvement after ATT, the patient should be followed and evaluated for sarcoidosis.

#### **Disclosure**

All the authors declared no competing interestes.

#### **References**

1. Milman N. Respiration 2006 ; 73 : 14 – 15
2. Papaetis GS et al J Med Case Report 2008 ; 2: 226
3. Baugman RP. Chest 1998;114:363
4. Wong et al. A case of concomittent Tuberculosis and Sarcoidosis with mycobacterial DNA present in sarcoid lesion Chest 1998;114:626-629
5. Scading J G The relation between sarcoidosis and tuberculosis Brompton hospital case report. Lyoled – Luke 1962; 31-34
6. Shah JR. Lung India 2007;24:83-86
7. Woodard BH, Rosenberg SI, Farnham R, Adams DO (1982). "Incidence and nature of primary granulomatous inflammation in surgically removed material". American Journal of Surgical Pathology 6 : 119–129
8. Iannuzzi M, Rybicki BA, Teirstein AS (2007). "Sarcoidosis". New England Journal of Medicine 357 : 2153–2165
9. Pinner M. Noncaseating Tuberculosis. An analysis of literature. Am.Rev;1938;37:690-728