

# FAMILIES WITH NEUROCUTANEOUS SYNDROME- A REPORT OF TWO CASES

SAHA R<sup>1</sup>, MAHMUD R<sup>2</sup>, HOSSAIN MZ<sup>3</sup>, SARKER PK<sup>4</sup>

## Abstract:

*Neurocutaneous syndrome is inherited as autosomal dominant condition. Tuberous sclerosis is one of the important neurocutaneous disorder characterized by development of widespread hamartomatous lesions involving skin, brain, kidney, retina etc. Recently we came across two cases of tuberous sclerosis. Both cases presented with status epilepticus and had a positive family history but the first case also had family history of neurofibromatosis.*

**Key words:** Neurocutaneous syndrome, Tuberous sclerosis, Neurofibromatosis.

*J Dhaka Med Coll. 2013; 22(1) : 102-107.*

## Introduction:

Neurocutaneous syndrome is a group of genetic disorders also known as Phakomatoses, produces a variety of developmental abnormalities of skin along with increased risk of nervous system tumors. These disorders are inherited as autosomal dominant condition with variable penetrance. These include Neurofibromatosis, tuberous sclerosis, Von HIPPEL-LINDAU syndrome.<sup>1</sup>

Tuberous sclerosis, also known as tuberous sclerosis complex (TSC), is an autosomal dominant, multisystem, neurocutaneous disorder characterized by development of widespread hamartomatous lesions involving skin, brain, kidney, retina etc. Von Recklinghausen first described tuberous sclerosis in 1862. Bourneville coined the term *sclerose tubereuse*, to indicate the superficial resemblance of the lesions to potato.<sup>2</sup>

Tuberous sclerosis is characterized by cutaneous lesion, seizure, and mental retardation. The cutaneous lesion includes adenoma sebaceum, ash leaf hypopigmented macule, shagreen patches and depigmented nevi.<sup>1</sup>

Mutation of both 9q (TSC-1) and 16p (TSC-2) are associated with tuberous sclerosis. The mutated gene code for tuberin, protein that modulate the GTPase activity.<sup>3</sup> More than 90% of patient develop subependymal giant cell

Astrocytoma. It may be complicated by Ependymoma and Hydrocephalus. Rhabdomyoma of myocardium and angiomyoma of kidney, liver, adrenals and pancreas may develop.<sup>3</sup>

Treatment is symptomatic. Control of convulsion is difficult. In severe case most of the patient die within 30 years of age.<sup>1</sup>

## Case Report:

First case:

Mrs Shahida a 30 years old muslim housewife, admitted on 05/03/11 in Faridpur Medical College Hospital with the complaints of repeated unremitting convulsion for 3 days. She had history of recurrent episodes of convulsion for 20 years.

She developed recurrent episodes of convulsion since her 10 years of age. It was complex partial seizure with secondary generalization. It was not associated with involuntary micturition, defecation or tongue biting. But she experienced trauma in different parts of the body in several times. She used to experience these episodes once or twice per month.

She had no history of headache or head trauma preceding this illness. Her birth was uneventful and her milestones of development were normal. She had average intellect. Three days back prior to admission she developed repeated unremitting convulsion associated with loss of consciousness and involuntary micturition and tongue biting. The convulsion was focal involving the right side of her body.

1. Dr. Radheshyam Saha, Associate Professor, Department of Neurology, Faridpur Medical College, Faridpur.

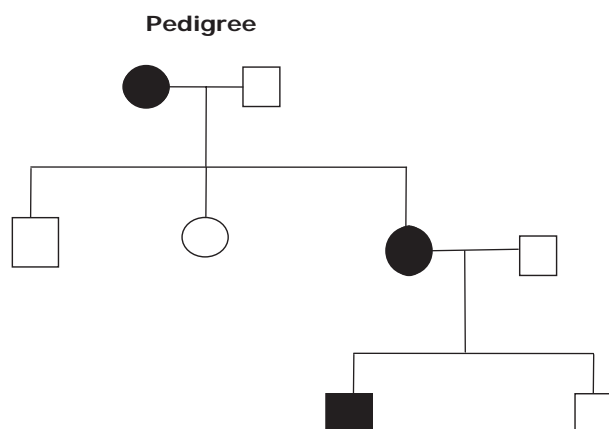
2. Dr. Reaz Mahmud, Assistant Registrar, Department of Medicine, Faridpur Medical College Hospital, Faridpur.

3. Dr. Mohammad Zaid Hossain, Assistant Professor of Medicine, Dhaka Medical College Hospital, Dhaka.

4. Dr. Prodip Kumar Sarker, IMO, Department of Medicine, Dhaka Medical College Hospital, Dhaka

**Correspondence:** Dr. Radheshyam Saha, Associate Professor, Department of Neurology, Faridpur Medical College, Faridpur.

She used to take tab Phenobarbitone infrequently. Her mother has plexiform neurofibroma in her face. Her older son has history of epilepsy and mental retardation. She belongs to low socioeconomic status.

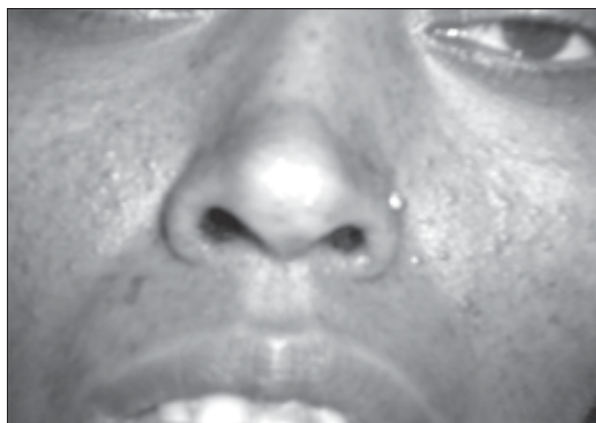


**Fig-1:** Pedigree of the patient

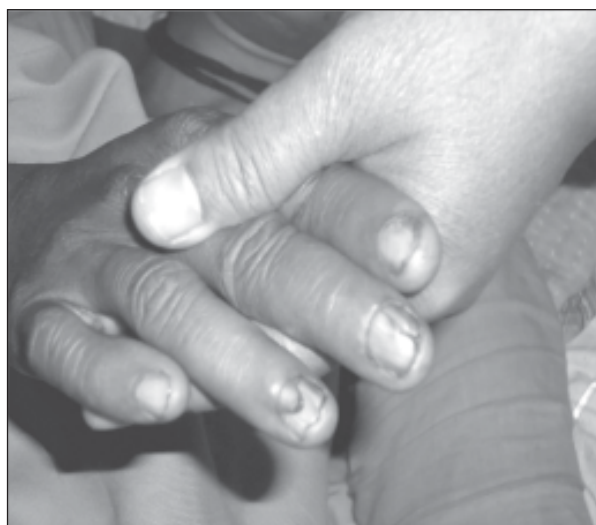

**Fig-2:** Mother of the patient with Plexiform neurofibroma.

On examination she is ill looking, co-operative, having average body built and nutrition. She is mildly anaemic, not icteric, and not cyanosed. She has adenoma sebaceum on her face, Subungual fibroma in right ring and left middle finger. Most of her nails are ridged. There is multiple ash leaf macule present on her trunk but no shagreen patches. She has multiple scar marks in different parts of her body.



**Fig-3:** Picture of the patient showing adenoma sebaceum.

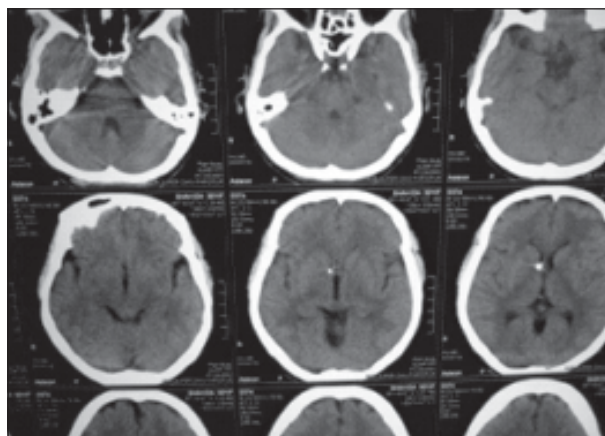


**Fig-4:** Picture of the patient showing subungual fibroma.

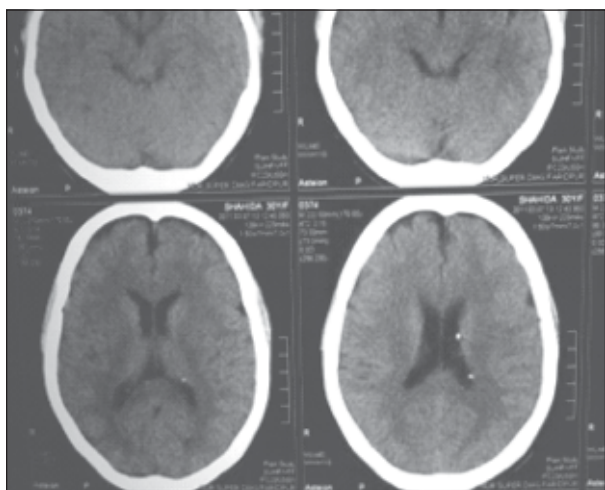
Neurological examination of the patient revealed, she was unconscious on admission. Her GCS was 06. But after one day she became fully conscious. She had average intellect and normal memory. There is no cranial nerve lesion and the fundus is normal.

On investigation total count of WBC is 14000, neutrophil 80%, lymphocyte 14%.

Hb%-68%, ESR-20, RBS-7.1 mmol/l, Serum Creatinine - 1.0 mg/dl, serum sodium -149 m mol/l, potassium 3.61 mmol/l. CT scan of the brain revealed Calcification in foramen of mono, Subependymal nodular calcification (candle guttering).



**Fig-5:** CT scan of the patient revealed calcification of foramen of monro.

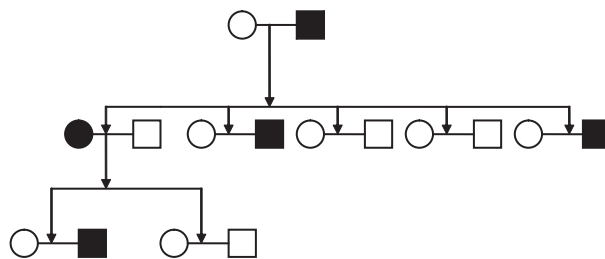


**Fig-6:** CT scan of the brain revealed Subependymal nodular calcification (candle guttering).

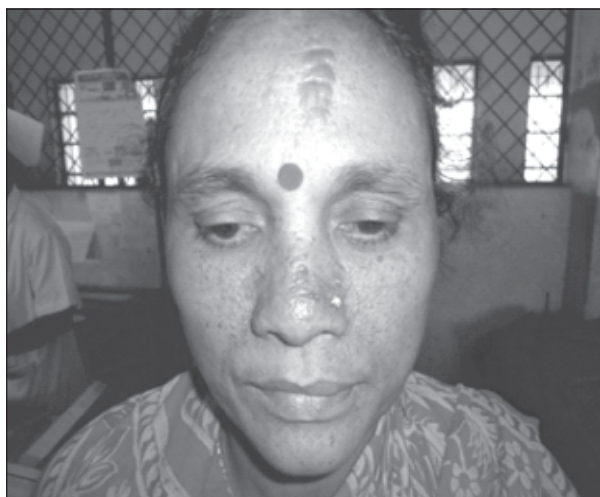**Second case:**

A 30 years old Hindu buissness man admitted on 28-03-2011 in Faridpur Medical college Hospital with a history of unremitting convulsion for one day. The convulsion was generalized and was associated with loss of consciousness. There was involuntary micturition and tongue biting. He had no history of fever and head trauma. He regained his consciousness after one day with treatment in the hospital. He had history of convulsion at his 8 month of age. Between this convulsion she was completely alright without any treatment. His milestones of development were normal and he has average intellect. His maternal grand father, two maternal uncles and his mother has skin lesion suggestive of

adenoma sebaceum. None of them has history of convulsion.

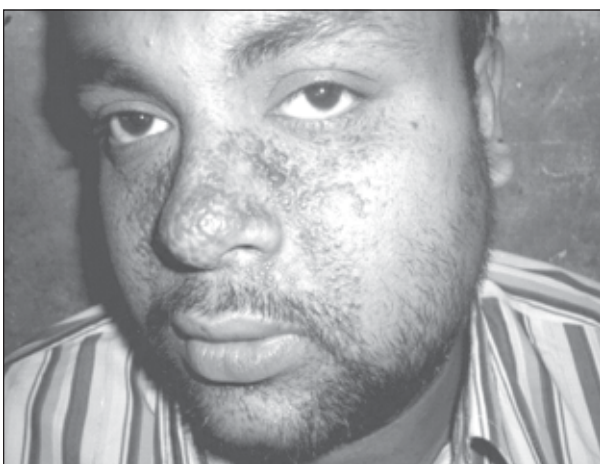

**Fig-7:** Pedigree of the patient

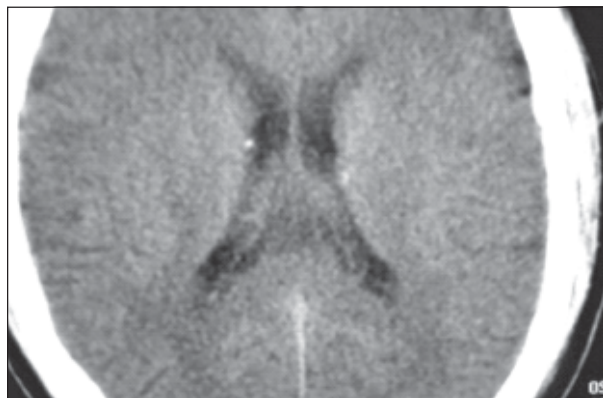

**Fig-8:** Mother of the patient with adenoma sebaceum.

On examination patient was ill-looking , obese . All of his vital sign were with in normal limit. There is adenoma sebaceum over his face. No asleaf macule or shagreen patch. But there is generalized ecthyema over his trunk.



**Fig-9:** Picture of the patient showing adenoma sebaceum.



**Fig-10:** CT scan of the patient revealed Subependymal nodular calcification(candle guttering).

Investigation revealed HB% 60% Total count of WBC was 8400 and neutrophil 70% Lymphocyte-25%. ESR 40 mm of Hg, RBS 5.6 mg / dl. Serum creatinine was 1.1 mg/dl. CT scan revealed calcification in subependymal region and foramen of monro.

#### Discussion:

Tuberous Sclerosis is an autosomal dominant disorder with almost complete penetrance but variable expressivity.<sup>4</sup> In our 1<sup>st</sup> case mother of patient had neurofibromatosis, among her three siblings she only has tuberous sclerosis and one of her offspring has tuberous sclerosis.

In our second case the grandfather of the patient had tuberous sclerosis, other than his mother two of his maternal uncle are also affected and he does not have any issue.

Some form of dermatological sign will be present in 96% of individuals with TSC. The most common skin abnormalities include:<sup>4</sup>

- Facial angiofibromas (“adenoma sebaceum”): A rash of reddish spots or bumps, which appear on the nose and cheeks in a butterfly distribution. They consist of blood vessels and fibrous tissue.
- Periungual fibromas: Also known as Koenen’s tumors, these are small fleshy tumors that grow around and under the toenails or fingernails.
- Hypomelanotic macules (“ash leaf spots”): White or lighter patches of skin that may

appear anywhere on the body and are caused by a lack of melanin. Forehead plaques: Raised, discolored areas on the forehead.

- Shagreen patches: Areas of thick leathery skin that are dimpled like an orange peel, usually found on the lower back or nape of the neck.
- Other skin features are not unique to individuals with TSC, including molluscum fibrosum or skin tags, which typically occur across the back of the neck and shoulders, *café au lait* spots or flat brown marks, and poliosis, a tuft or patch of white hair on the scalp or eyelids.

Our 1<sup>st</sup> case had adenoma sebaceum, periungual fibroma and ash leaf macules. Our 2<sup>nd</sup> case only had adenoma sebaceum.

About 50% of people with TSC have learning difficulties ranging from mild to significant,<sup>5</sup> and studies have reported that between 25% and 61% of affected individuals meet the diagnostic criteria for autism, Three type of brain tumours may be associated with TSC: i. Giant cell astrocytoma: (grows and blocks the CSF flow leading to dilatation of ventricles causing headache and vomiting) ii. Cortical tubers: after which the disease is named. iii. Sub-ependymal nodules: form in the walls of ventricles. A variable degree of ventricular enlargement, either obstructive (e.g. by a subependymal nodule in the region of the foramen of Monroe) or idiopathic in nature may be present.<sup>6</sup>

None of our patient had learning difficulty and both of them had sub-ependymal nodules.

Between 60 and 80% of TSC patients have benign tumors (once thought hamartomatous, but now considered true neoplasms) of the kidneys called angiomyolipomas (AML). frequently Approximately 20-30% of people with TSC will have renal cysts, causing few problems. However, 2% may also have autosomal dominant polycystic kidney disease.<sup>7</sup>

A cardiac rhabdomyoma can be discovered using echocardiography in approximately 50% of people with TSC.<sup>4</sup>

Retinal lesions, called astrocytic hamartomas (or “phakomas”), which appear as a greyish or yellowish-white lesion in the back of the globe on the ophthalmic examination.<sup>4</sup>

Non-retinal lesions associated with TSC include<sup>4</sup>

- Coloboma
- Angiofibromas of the eyelids
- Papilledema (related to hydrocephalus)

None of our patient had any cardiac, renal and retinal lesion

According to revised diagnostic criteria, definite tuberous sclerosis complex is diagnosed by the

presence of 2 major features or 1 major feature plus 2 minor features . Probable tuberous

sclerosis complex is indicated by 1 major feature plus 1 minor feature. Possible tuberous sclerosis

complex is indicated by either 1 major feature or 2 or more minor features.<sup>8</sup>

Revised diagnostic criteria of Tuberous Sclerosis

#### Major features

1. Facial angiofibromas or forehead plaque
2. Nontraumatic unguis or periungual fibromas
3. Hypomelanotic macules (>3)
4. Shagreen patch (connective tissue nevus)
5. Multiple retinal nodular hamartomas
6. Cortical tuber
7. Subependymal nodule
8. Subependymal giant cell astrocytoma
9. Cardiac rhabdomyoma, single or multiple
10. Lymphangiomyomatosis
11. Renal angiomyolipoma

#### Minor features

1. Multiple randomly distributed
2. pits in dental enamel
3. Gingival fibromas
4. Confetti skin lesions
5. Multiple renal cysts
6. Bone cysts
7. Hamartomatous rectal polyps

#### 8. Cerebral white matter radial migration lines

Our 1<sup>st</sup> case had 4 major criteria and 2<sup>nd</sup> case had 2 major criteria on the background of positive family history. so they were undoubtedly labeled as tuberous sclerosis.

Drug therapy for some of the manifestations of TSC is currently in the developmental stage. <sup>9</sup> for example, a 2008 study found that treatment with rapamycin rescued learning and memory deficits in a mouse model of tuberous sclerosis.<sup>10</sup> The patients usually have relapse of symptoms in the clinical course. Unless any vital function is affected, life expectancy is good. Majority of patients will require some medications to control symptoms, e.g., anti-epileptics to control seizures.

In both of the cases we have only prescribed anti-epileptic drugs.

#### Conclusion:

Tuberous sclerosis is a benign condition with malignant potential. In 2010 we have a reported case of tuberous sclerosis who developed bilateral angiomyolipoma of the kidney.<sup>11</sup> The patient have to be follow up life long, so that we can detect malignancy at very early stage.

#### References

1. Schofield OMV, Rees JL. The skin in systemic disease. In: Davidson's principle and practice of medicine. Nicki R. college, Brain R Walker, Stuart H Ralston. 21<sup>th</sup> ed. Philadelphia: Elsevier; 2010: 1006.
2. Bourneville DM. Sclerose tubereuse des circonvolutions cerebrales: idiotie et epilepsie hemiplegique. Arch Neurol (Paris) [Article in French][Abstract]1880; 1: 81-91.
3. Stephen M, Sagar, Mark A, Israel. Primary and Metastatic tumor of the nervous system. In: Kasper DL, Braunwald E, Fauci AS, Longo DL, Jamison LJ eds. Harrison's principles of internal medicine. 17<sup>th</sup> ed. New York: Mc Graw Hill; 2008; 2: 2607.
4. Roach E, Sparagana S. Diagnosis of tuberous sclerosis complex. J Child Neurol 2004; 19(9): 643-9.
5. Staley BA, Montenegro MA, Major P et al. Self-injurious behavior and tuberous sclerosis complex: frequency and possible associations in a population of 257 patients. Epilepsy Behav , 2008; 13(4): 650-3.

6. Ridler K, et al. Standardized whole brain mapping of tubers and subependymal nodules in tuberous sclerosis complex. *J Child Neurol* 2004; 19(9): 658-65.
7. Henske EP. Tuberous sclerosis and the kidney: From mesenchyme to epithelium, and beyond. *Pediatr Nephrol* 2005; 20: 854-7.
8. Roach ES, Gomez MR, Northrup H. Tuberous sclerosis complex consensus conference: revised clinical diagnostic criteria. *J Child Neurol* 1998; 13(12): 624-8.
9. Yates JR. Tuberous sclerosis. *Eur J Hum Genet* 2006; 14(10): 1065-73.
10. Ehninger D, Han S, Shilyansky C, et al. Reversal of learning deficits in a *Tsc2*<sup>+/</sup> mouse model of tuberous sclerosis. *Nat Med* 2008; 14(8): 843-8.
11. Haque MA, Sharmi LS, Ekram ARMS, Islam MS. Tuberous sclerosis complex in a family. *J Medicine* 2010; 11: 94-8.