

PREOPERATIVE PREDICTORS OF OSSICULAR DISCONTINUITY IN NON-CHOLESTEATOMA CHRONIC OTITIS MEDIA

SAHA KL¹, GHOSH NC², AKHTAR N³, TALUKDER DC⁴

Abstract:

Background: Though ossicular discontinuity is more common in cases of cholesteatoma, it may happen in non-cholesteatoma COM. The long process of incus is more frequently involved ossicle. Preoperative assessment of ossicular integrity is the gold standard way. But the discontinuity of the ossicular chain can be assumed before surgery by analyzing perforation edge adherent to medial wall and wide air-bone gap. The purpose of the study was to find out the preoperative findings which can predict the ossicular discontinuity in non-cholesteatoma cases.

Methods: This cross-sectional study was conducted in the department of Otolaryngology-Head & Neck Surgery, Bangabandhu Sheikh Mujib Medical University from January 2013 to June 2014. 81 patients of COM without cholesteatoma were selected as per inclusion and exclusion criteria. Relevant data were collected in a predesigned data collection sheet and analyzed with standard statistical method. Statistically significant inferred for P value <0.05. No groups whose ability to give voluntary informed consent questionable was not included. No potential risks exist in designed this study.

Results: Air-bone gap > 40 dB was found in 60% cases of ossicular discontinuity, followed by air bone gap 31-40 dB(20%), 21-30 dB(13.33%) and 11-20 dB(6.67%) respectively. So ossicular discontinuity was more in higher air-bone gap group and it was statistically highly significant ($p<0.001$). Perforation edge attached to medial wall where ossicular discontinuity was 93.3% and perforation edge free from medial wall was 6.7%. Ossicular discontinuity was higher when perforation edge was found attached to medial wall which was highly statistically significant ($p<0.001$). Out of 25 granulation tissue cases ossicular discontinuity was found 21(84%) and ossicular chain intact was found 4(16%). That was statistically significant ($p<0.01$).

Conclusion: Non-cholesteatoma COM may cause ossicular disconnection. Majority ossicular discontinuity found when average air bone gap > 40 dB. Ossicular discontinuity was also found more in cases where there is attachment of perforation edge to medial wall, and presence of granulation tissue. If preoperative information can be gathered to determine whether or not the ossicular chain is intact, the patient can be better informed, counseled for ossiculoplasty before surgery.

Key words: COM, non-cholesteatoma, ossicular discontinuity, hearing loss, A-B gap, per-operative.

DOI: <https://doi.org/10.3329/jdmc.v29i1.51171>
J Dhaka Med Coll. 2020; 29(1) : 47-52

Introduction:

Chronic otitis media(COM) with or without cholesteatoma may cause ossicular chain erosion^{1,2,3}. The long process of the incus and stapes suprastructure are frequently affected ossicles in COM^{3,4,5,6,7}. In non-cholesteatoma COM, adherence of perforation edges to medial wall may confine the granulation tissues and

inflammatory products in a small, dead space, therefore inducing further ossicular discontinuity^{8,9,10}.

Pathologies that interrupt the ossicular chain result in much hearing loss. Complete disruption of the ossicular chain can result in a 60dB hearing loss¹¹.

1. Dr. Kanu Lal Saha, Associate Professor, Department of Otolaryngology and Head-Neck Surgery, Bangabandhu Sheikh Mujib Medical University, Dhaka, Bangladesh.
2. Dr. Nibash Chandra Ghosh, Assistant Professor, Department of Otolaryngology and Head-Neck Surgery, Dr Sirajul Islam Medical College and Hospital, Dhaka
3. Dr Nasima Akhtar, Professor, Department of Otolaryngology and Head-Neck Surgery, Bangabandhu Sheikh Mujib Medical University, Dhaka, Bangladesh
4. Dr. Debesh Chandra Talukder, Associate Professor, Department of ENT & Head Neck Surgery, Dhaka Medical College, Dhaka

Correspondence : Dr. Kanu Lal Saha, Associate Professor, Department of Otolaryngology and Head-Neck Surgery, Bangabandhu Sheikh Mujib Medical University, Dhaka, Bangladesh. Cell:01711252815, Email: drklsaha@gmail.com

Received: 08-01-2020

Revision: 18-01-2020

Accepted: 21-03-2020

Per-operative assessment is the gold standard method of confirmation of the discontinuity of the ossicular chain. But it would be of great help if we can predict it before surgery.

The difference in the thresholds of air and bone conduction (A-B gap) is a measure of the degree of conductive deafness. The air conduction threshold and air -bone gap in patients with ossicular discontinuity are higher than that in patients with ossicular continuity.

So, subjects with a wide air bone gap at higher frequencies (i.e. > 30 dB at 2 kHz and > 40 dB at 4 kHz) assessed by pure tone audiometry should undergo exploration of the ossicular chain with reconstruction when possible^{12,13}.

High resolution computed tomography scan can help identify middle ear ossicles and detect their discontinuity^{7,10}. It is not a confirmatory pre-operative investigation, and not a routine test for non-cholesteatoma chronic otitis media patients.

Surgery is the treatment of choice for COM. Successful operation is to obtain a intact new tympanic membrane, and to restore or improve hearing depending upon the pathology. If the ossicular discontinuity is predicted before surgery, it helps the surgeon to know the possibility of performing an ossiculoplasty, and to counsel patients about the procedure, success ,failure and complications. In this study preoperative predictive findings of ossicular chain discontinuity in non-cholesteatoma chronic otitis media has been assessed.

Methodology: The medical records of 81 patients of non-cholesteatoma COM managed at the Bangabandhu Sheikh Mujib Medical University, Dhaka, Bangladesh from January 2013 to June 2014 were included in this study. Patients with previous history of ear surgery, congenital cholesteatoma, age below 12 and more than 60 years and profound hearing loss were excluded from this study. Patients age, sex, presenting symptoms, side, preoperative and per-operative findings and audiological data were documented and analyzed. Audiological evaluation was done by pure tone audiogram. All patients underwent tympanoplasty with or without mastoidectomy under general anesthesia. Preoperative Air-Bone gap, presence of adherence of perforation margin to medial wall were used as outcome variables, and intraoperative findings of ossicular discontinuity with related features were noted.

Methods of sampling: Purposive, non-random sampling.

Data collection technique:

Relevant data were collected in a predesigned data collection sheet for each of the patient with chronic otitis media. Diagnosis was made by history, clinical, otoscopic, microscopic examination and radiological investigation and peroperative findings.

Analysis of data and result:

Data were processed manually and analyzed with the help of SPSS (Statistical package for social sciences) Version 19.0. Quantitative data were expressed as mean and standard deviation and comparison were done by student “t” test. Qualitative data were expressed as frequency and percentage comparisons were carried by chi-square (X²) test. Other statistical test was done whenever it is necessary. A probability value (p) of less than 0.05 was considered to indicate statistical significance.

Results:

Table I

Age group distribution of the patients (n=81)

Age in years	Number	Percentage (%)
16-30	55	67.90
31-45	16	19.75
46-60	10	12.35
Total	81	100.00
Mean ±SD	23.79(±10.33)	15-53 years

Table I shows that 55(67.90%) of the study population were in the age group 16-30 years, followed by 19.75% in age group between 31-45 years of age and in age group between 46-60 years was 12.35%. Majority of the study population were in the age group 16-30 years. Mean age was 23.79(±10.33) years.

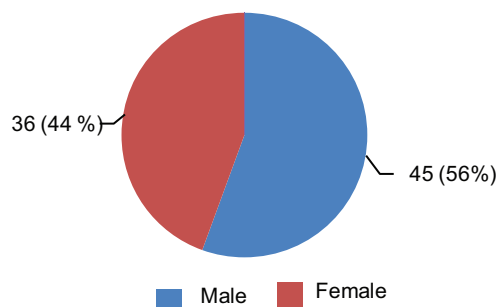


Fig.-1: Sex distribution of the patients (n=81)

Figure 1 shows that 56% were male and 44% were female. Male female ratio was 1.27: 1. Male were clearly majority in number.

Table II

Distribution of symptoms among study patients (n=81)

Symptoms	Number	Percentage(%)
Ear discharge	81	100
Hearing impairment	62	76.54
Earache	11	13.58
Vertigo	01	1.23

Table II shows that all patients 81(100%) had presented with history of otorrhoea, 62(76.54%) had hearing impairment, 11(9.73%) had earache, 01(0.88%) had vertigo. Most of the patients presented with more than one symptom. Commonest presenting complaint was ear discharge.

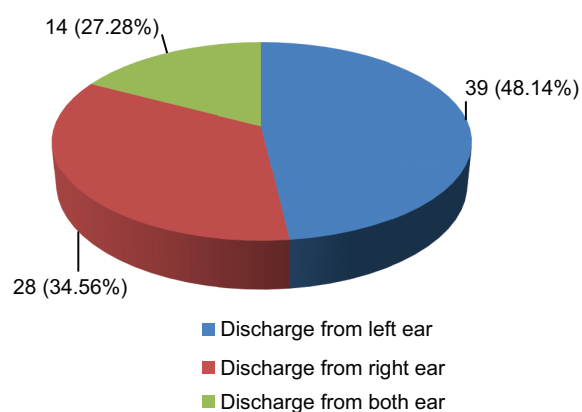


Fig.-2: Distribution of site of aural discharge in study population (n=81)

Figure 2 shows, discharge from right ear was 28(34.56%), discharge from left ear was 39(48.14%) and discharge from both ears was 14(17.28%).

Table III

Relation between preoperative degree of hearing loss with per operative Ossicular discontinuity (n=81)

Degree of hearing loss	Status of Ossicular chain		
	Intact n (%)	Discontinuity n (%)	p value
Normal (n=09)	09(13.6)	—	0.02*
Mild(n=27)	26(39.4)	01(6.7)	0.001*
Moderate (n=24)	17(25.8)	07(46.7)	0.04*
Moderately severe (n=16)	12(18.1)	04(26.7)	0.36
Severe (n=05)	02(3.0)	03(20.0)	0.003*
Total	66(100)	15(100)	

*= significant

Table III shows that out of 27 patients with mild degree of hearing loss 26(39.7%) had intact ossicular chain whereas discontinuity was seen in 1(6.7%) case. Out of 24 patients with moderate degree of hearing loss 07(46.7%) had ossicular discontinuity. Out of 16 patients with moderate to severe degree of hearing loss 12(18.1%) had intact ossicular chain whereas ossicular discontinuity was found 04(26.7%). Out of 05 patients of severe degree of hearing loss, 3(20%) cases had shown ossicular discontinuity. Cases with moderate and severe degree of hearing loss had significant ossicular discontinuity ($p < 0.05$).

Table IV

Relation between pre-operative air bone gap with per operative ossicular discontinuity (n=81)

Air bone gap (dB)	Status of ossicular chain		Total	P value
	Intact	Discontinuity		
0-10 (dB)	—	—	—	—
11-20 (dB)	8(12.12)	01(6.67)	09	0.38
21-30 (dB)	40(60.60)	02(13.33)	42	0.001*
31-40 (dB)	7(10.60)	03(20.0)	10	0.95
> 40 (dB)	11(16.67)	09(60.0)	20	<0.001*
Total	66(100)	15(100)	81	

Table IV shows that majority of ossicular discontinuity (60%) was seen when average air bone gap was > 40 dB, followed by 20% in air bone gap between 31-40 dB, 13.33% in 21-30 dB and 6.67% in 11-20 dB respectively. That means if air bone gap is greater, ossicular discontinuity is more (p<0.001) and was statistically highly significant.

Table V
Relation between perforation edge with ossicular discontinuity (n=81)

Perforation Edge	Status of Ossicular chain		Total	p value
	Intact	Discontinuity		
Attached	1(6.7)	14(93.3)	15(100)	<0.001
Free	65(98.48)	01(1.52)	66(100)	
Total	66(81.48)	15(18.51)	81(100)	

Table V shows that perforation edge attached to medial wall revealed ossicular discontinuity in 93.3%. and perforation edge free was in 6.7%. Perforation edge attached to medial wall was higher in ossicular discontinuity which was highly statistically significant (p<0.001).

Table VI
Relation between granulation tissues with operative status of ossicular chain (n=25)

Granulation tissue	Status of ossicular chain		p value
	Intact n(%)	Discontinuity n(%)	
Present	4(16)	21(84)	0.01

Table VI shows that out of 25 granulation tissue cases ossicular discontinuity was found in 21(84%) and intact ossicular chain was found 4(16%). That was statistically significant (p<0.01).

Discussion:

Though ossicular discontinuity is more common in cases of cholesteatoma, it may happen in non-cholesteatoma COM. Erosion of long process of incus is the most common ossicle involved in ossicular chain discontinuity. The discontinuity of the ossicular chain can be assumed before surgery by analyzing pre-operative, clinical audiological and imaging

findings. But it is usually confirmed during operation.

In present study showed that 55(67.90%) of the study population were in the age group 16-30 years, followed by 19.75% in age group between 31-45 years of age and in age group between 46-60 years was 12.35%. Majority of the study population were in the age group 16-30 years. Mean age was 23.79(±10.33) years.

This is near to similar findings was found in a study where mean age was 29.78 (±13.09) and the number of cases in the 16–25 years age group was 77 (51.33%)⁴.

This study showed that male was 56% and female was 44%. Male female ratio was 1.27: 1. Male were clearly majority in number. In different studies, it was shown that COM affected more in male than female^{14, 15,16,17}. This might be due to increase prevalence of COM among the male or it might be simple reflection of overall high male attendance in hospital.

In present study that all patients 81(100%) had presented with history of otorrhoea, 62(76.54%) had hearing impairment, 11(9.73%) had earache, 01(0.88%) had vertigo. Most of the patients presented with more than one symptom. Most of the patients presented with more than one symptom. Commonest presenting complaint was discharge . These results are comparable to the studies done by other authors^{18,19}.

In current study, discharge from right ear was 28(34.56%), and from left ear 39(48.14%) and discharge from both ears was 14(27.28%). That is dissimilar to another study⁴.

In present study showed that out of 27 patients with mild degree of hearing loss 26(39.7%) had intact ossicular chain whereas discontinuity was seen in 1(6.7%) case. Out of 24 patients with moderate degree of hearing loss 07(46.7%) had ossicular discontinuity. Out of 16 patients with moderate to severe degree of hearing loss 12(18.1%) had intact ossicular chain whereas ossicular discontinuity was found 04(26.7%). Out of 05 patients of severe degree of hearing loss, 3(20%) cases had shown ossicular discontinuity. Cases with moderate and severe degree of hearing loss had significant ossicular

discontinuity ($p < 0.05$). Cases with moderate and severe degree of hearing loss had significant ossicular discontinuity ($p < 0.05$). These findings are consistent with results of other study²¹.

In this study, shows that majority of ossicular discontinuity (60%) was seen when average air bone gap was > 40 dB, followed by 20% in air bone gap between 31-40 dB, 13.33% in 21-30 dB and 6.67% in 11-20 dB respectively. That means if air bone gap is greater, ossicular discontinuity is more ($p < 0.001$) and was statistically highly significant. That means if air bone gap is greater, ossicular discontinuity is more ($p < 0.001$) and statistically highly significant. These findings consist with findings of Jeng et al. study¹¹.

In the current study, when the perforation edge was found attached to medial wall then ossicular discontinuity was 93.3% and if perforation edge was found free from medial wall, the rate of ossicular discontinuity was 6.7%. Ossicular discontinuity was higher in when perforation edge was found attached to medial wall which was highly statistically significant ($p < 0.001$). This was correlated with findings of other studies^{10,21,22}.

In this study, out of 25 granulation tissues cases, ossicular discontinuity was found in 21(84%) and intact ossicular chain was found in 4(16%). That was statistically significant ($p < 0.01$).

Wide air bone gap suggests presence of ossicular chain discontinuity. So, in preoperative pure tone audiometry with higher air-bone gap or increased conductive threshold exploration of the ossicular chain with possible reconstruction is suggested on subjects with a high chance of ossicular chain discontinuity.

Conclusion:

Non-cholesteatoma COM may cause ossicular disconnection. Majority ossicular discontinuity found when average air bone gap > 40 dB. Ossicular discontinuity was also found more in cases where there is attachment of perforation edge to medial wall, and presence of granulation tissue. If preoperative information can be gathered to determine whether or not the ossicular chain is intact,

the patient can be better informed, counselled for ossiculoplasty before surgery.

References:

1. Sade J, Halevy A. The etiology of bone destruction in COM. *J Laryngol Otol* 1974 ;88:139-43.
2. Tos M. Pathology of the ossicular chain in various chronic otitis media. *J Laryngol Otol* 1979;93:769-80.
3. Thomsen J, Bretlau P, Jorgesen MB. Bone resorption in COM; the role of cholesteatoma: a must or an adjunct? *Clin Otolaryngol* 1981; 6: 179-86.
4. Varshney S, Nangia A, Bist SS, Singh R K, Gupta N, Bhagat S. Ossicular chain status in chronic suppurative otitis media in adults. *Indian J Otolaryngol Head Neck Surg* 2010;62(4): 421-426.
5. Anglitoiu A, Balica N. Ossicular chain status in the ontological pathology of the ENT clinic Timisoara. *Medicine in evolution* 2011; XVII (4) : 344-51.
6. Austin DF. Ossicular reconstruction. *Otolaryngol Clean North* 1972 ;5:145-60.
7. Swartz JD, Berger AS, Zwillenberg S, Popky GL. (1987). Ossicular erosions in the dry ear: CT diagnosis. *Radiology* 1987;163: 763 - 76.
8. Schachern P, Paparella MM, Sano S, Lamey S, Guo Y. A histopathological study of the relationship between otitis media and mastoiditis. *Laryngoscope* 1991;101:1050-5.
9. Chole RA, Choo MJ. (1998). COM, Mastoiditis, and petrositis. In: Cummings CW. *Otolaryngology Head Neck Surgery*, 3rd ed. CV Mosby: St. Louis 1998; 3026-46.
10. Jeng FC, Tsai MH, Brown CJ. (2003). Relationship of pre-operative findings and ossicular discontinuity in Chronic Otitis Media. *Otology and Neurotology* 2003;24: 29-32.
11. Bojrab DI, Balough BJ. Surgical anatomy of the temporal bone and dissection guide. In: Glasscock ME, Gulya AJ (eds) *Glasscock-Shambaugh surgery of the ear*, 5th ed. Reed Elsevier India Pvt. Ltd, New Delhi 2003;778.
12. Carrillo RJ, Yang NW, Abes GT. Probabilities of ossicular discontinuity in chronic suppurative otitis media using pure tone audiometry. *Otology and Neurotology* 2007; 28:1034-7.
13. Feng H, Chen Y, Ding Y. Analysis of preoperative findings and ossicular condition in chronic suppurative otitis media. *Lin Chuang Er Bi Yan Hou Ke Za Zhi* 2005; 19: 7-8.
14. Aktar N, Alauddin M, Siddiquee BH, Alam MM, Ahmed MU. (2003). Hearing loss in chronic Suppurative otitis media. *Bangladesh J of Otorhinolaryngology* 2003; 9:19-23.

15. Fakir AY, Hanif A, Ahmed KU, Haroon AA. Intracranial complications of CSOM - A study of 40 cases. *Bangladesh J of Otorhinolaryngology* 1999;9: 11-14.
16. Hossain MA, Sarker MZ, Bhuiyanv MAR, Alam KMN, Harun MAA, Hanif MA. (2014). Results of Tympanomastoid Surgery in CSOM with Cholesteatoma (Attico-Antral Variety)-A Study of 30 Cases, *Bangladesh J Otorhinolaryngology* 2014; 20: 20-26
17. Browning GG et al.(2008).Chronic otitis media. In: Gleeson M et al. *Scott Brown's Otorhinolaryngology, Head & Neck Surgery*.7th ed. Hodder Arnold, London 2008;3396-3445.
18. Glasscock ME, Dickins JRE, Welt R. Cholesteatoma in children. *Laryngoscope*1981; 91:1743-53.
19. Mac-Millian AS. (1969). Radiologic diagnosis of Neuro-otologic problems by conventional radiology. *Arch Otolaryngol*1969; 89:78-82.
20. Srinivas C, Kulkarni NH, Bhardwaj NS, Kottaram PJ, Kumar H, Mahesh SV.Factors influencing ossicular status in mucosal chronic otitis media – An observational study , *Indian Journal of Otology* 2014 20:16-19.
21. Gulya AJ, Schuknecht HF. *Anatomy of the temporal bone with surgical implications*. 2nd ed. Parthenon Publishing Group, Pearl River (NY)1995,150-155.
22. Borg E, Nilsson R, Engstrom B. Effect of the acoustic reflex on inner ear damage induced by industrial noise. *Acta Otolaryngol* 1983;96: 361-9.