

## CASE REPORT

# TREATMENT OF SYSTEMIC SCLEROSIS COMPLICATED BY CARDIAC ARRHYTHMIA: A CASE REPORT

AMIN MZ<sup>1</sup>, SARKER A<sup>2</sup>, SANYAL M<sup>3</sup>, SHUMY F<sup>4</sup>

### Abstract:

Cardiac manifestations are occasionally observed in Systemic Sclerosis patients. Primary cardiac involvement may occur as a direct consequence of the disease. Arrhythmias are also thought to be a direct result from conduction system fibrosis. Early diagnosis and treatment of arrhythmia can be rewarding for this patient as if untreated may lead to a fatal outcome. Beta blockers used to treat arrhythmia may worsen Raynaud's symptom in systemic sclerosis. So there has been a controversy regarding the treatment of arrhythmia in Systemic Sclerosis. Here we are reporting a case of Systemic Sclerosis who presented with palpitation and digital gangrene. Her resting ECG showed multiple premature ventricular complexes whereas echocardiogram did not show any significant abnormality. Then She was treated with non-selective beta blocker without any progression of her Raynaud's. For her digital gangrene, along with other conventional treatment (like nifedipine & tadalafil) she was treated with endothelin receptor antagonist (bosentan) and showed good response.

**Key words:** Scleroderma, Cardiac arrhythmia, Carvedilol.

DOI: <https://doi.org/10.3329/jdmc.v32i1.76457>  
J Dhaka Med Coll. 2023; 32(1) : 92-95

### Introduction:

Systemic sclerosis (SSc) is a rare connective tissue disease that is characterized by localized or diffuse skin thickening and fibrosis. Fibrosis can occur in various organs throughout the body. On the basis of extent of skin involvement, the disease is classified into two subtypes: diffuse cutaneous systemic sclerosis and limited cutaneous systemic sclerosis. Primary cardiac involvement, which develops as a direct consequence of SSc, may manifest as myocardial involvement, fibrosis of the conduction system, pericardial and, less frequently, as valvular disease. Furthermore, cardiac complications may develop as a secondary phenomenon due to pulmonary arterial hypertension (PAH), interstitial lung disease, and kidney pathology<sup>1, 2</sup>.

Arrhythmias and conduction abnormalities are thought to be a direct result from myocardial & conduction system fibrosis respectively<sup>3, 4</sup>.

Supraventricular arrhythmias are considered to be more common in SSc patients, occurring in approximately two thirds of the cases, and much more frequent than ventricular tachyarrhythmias<sup>5</sup>.

Ferri et al in their studies registered arrhythmias and conduction defects in SSc patients using 24-h Holter monitoring. Rhythm and conduction abnormalities (e.g., conduction defects, supraventricular or ventricular arrhythmias and ST-T changes) were found in 42% of the patients on resting electrocardiogram<sup>6</sup>.

It was emphasized that SSc individuals should have earlier intervention compared to non-SSc

1. Md. Zahid Amin, Consultant & Head, Department of Medicine, Central Police Hospital, Dhaka
2. Arpita Sarker, Post-Graduation Trainee, Department of Medicine, Central Police Hospital, Dhaka.
3. Mousumi Sanyal, Consultant, Department of Medicine, Central Police Hospital, Dhaka,
4. Farzana Shumy, Associate Consultant (Rheumatology), Square Hospitals Ltd.

**Correspondence:** Md. Zahid Amin, Consultant & Head, Department of Medicine, Central Police Hospital, Dhaka,  
Email: dr.zahidamin@gmail.com Mobile: +8801818778671

**Received:** 25.01.2023

**Revision:** 19.11.2023

**Accepted:** 03.01.2024

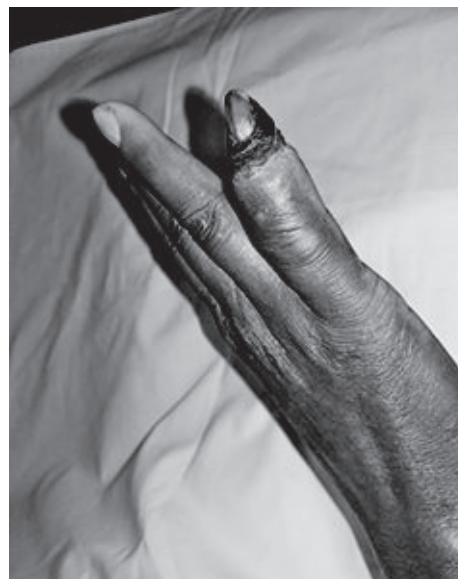individuals in regard to cardiac complications. Same treatment principle could be applied but betablockers may aggravate Raynaud's phenomenon.<sup>7</sup> However there are some studies where carvedilol (non-selective betablocker) was used safely in these patients.<sup>8</sup>

Digital gangrene is an important complication of systemic sclerosis. Generally, calcium channel blockers, phosphodiesterase 4 inhibitors and anti-platelets are used for the treatment but recent evidence suggest endothelin 1 receptor antagonist (ERAs) could also have a good role for recovery and further ulcer prevention.

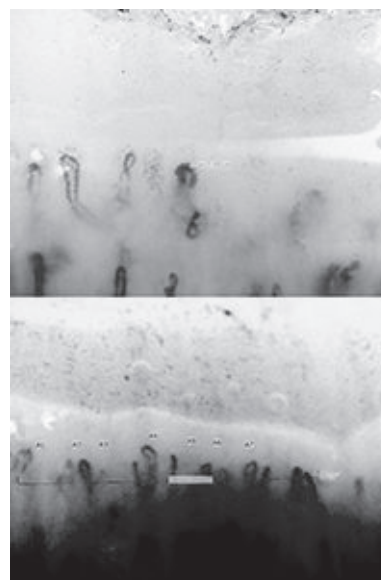
Here we are reporting a case of Systemic Sclerosis presented with digital gangrene and Premature Ventricular complexes (PVC) in her resting ECG.

**Case History:** A 40-year-old diabetic, hypertensive female, previously diagnosed as diffuse cutaneous systemic sclerosis, came to us with occasional palpitation for last few days without any chest pain. For last one year she was suffering from skin thickening, blackish discoloration along with multiple digital gangrenes in both hands and feet with yellowish oozing (figure- 1). She was treated with different medications including calcium channel blocker and anti-platelet agent for progressive Raynaud's. During investigations she was found positive for ANA and Anti Ds DNA. Her capillaroscopy showed reduced number of capillaries, some area of hemorrhage and disorganization, enlarged loop of capillaries and the comment was late scleroderma pattern (Figure 2). Her pulse was 92/min, blood pressure was 110/80 mmHg and all her peripheral pulses were intact. There was no abnormality on cardiac auscultation. Her resting ECG showed multiple premature ventricular complexes (PVC) (figure-3). Her Echocardiography findings were arrhythmia with poor echo window, LA dilated (41 mm), normal ventricular systolic function (LVEF 68%) and PASP 20 mmHg. For her progressive Raynaud's & digital gangrene we prescribed her phosphodiesterase-5 inhibitor & endothelin-1 antagonist. She tolerated these medications well and her Raynaud's as well as gangrene were improving but still, she continued to have palpitation and PVC in her resting ECG. Then

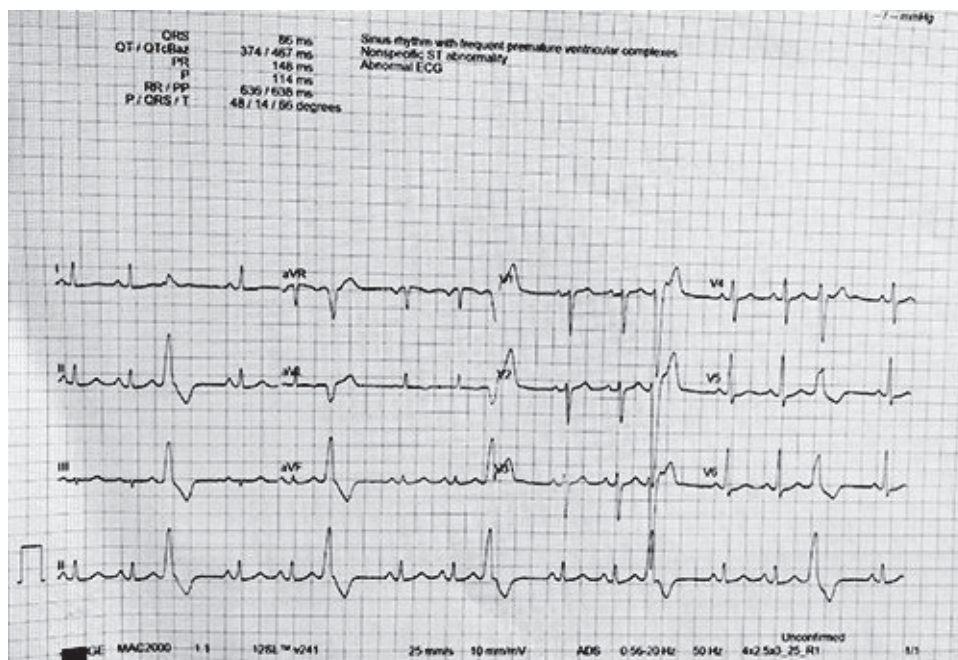
she was put on carvedilol 6.25mg twice daily. During further follow-up, her palpitation improved without any deterioration of her Raynaud's. Her recent ECG did not show any feature of PVC (figure-4). During further examination we found bi basal crepitation. In spirometry and HRCT chest moderate restriction and DPLD were found respectively. On that basis we started Mycophenolate Mofetil and during further follow-up her lung symptoms were also improved.



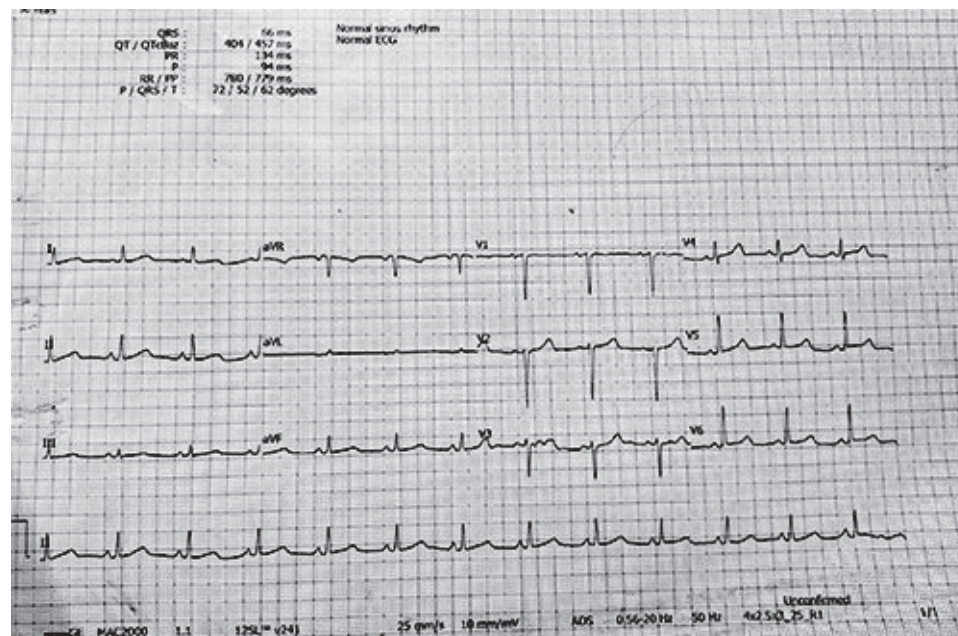
**Figure 1:** *Hand of the Systemic Sclerosis Patient showing digital gangrene*



**Figure 2:** *Nailfold Capillaroscopy of the patient showing enlarged loop of capillaries, disorganization and loss of capillaries*



**Figure 3:** ECG of the Systemic Sclerosis Patient showing PVC



**Figure 4:** Subsequent normal ECG of the Systemic Sclerosis Patient after carvedilol treatment

**Discussion:**

Systemic sclerosis (SSc) patients may experience arrhythmias, which are associated with a worse prognosis and account for 6% of all patient deaths.<sup>9</sup> The underlying arrhythmogenic mechanisms are not well understood but myocardial damage and fibrosis seem to be the most important factors. Here

we have described a case of systemic sclerosis who presented with progressive Raynaud’s and palpitation. During investigation her resting ECG showed multiple PVC. Later her echo cardiogram did not show any features of pulmonary hypertension, pericardial or myocardial involvement, septal hypertrophy or any valvular abnormality. The patient also

developed digital gangrene for which we started tadalafil 10mg (phosphodiesterase -4 inhibitor) daily and aspirin 75mg daily in addition to nifedipine 20mg three times daily. There has been always a chance that Raynaud's would be deteriorated after starting beta blocker due to increased vasoconstriction. Till date no randomized controlled trials have been performed to see the efficacy of beta blocker in this situation. Luca et al suggested among all beta blockers, carvedilol & bisoprolol known to have less effect on Raynaud's phenomenon.<sup>10</sup> So she was put on carvedilol 6.25 mg twice daily and observed for any decrement of her Raynaud's Phenomenon. After some days her resting ECG were improved and there was no decrement in her Raynaud's Phenomenon. In addition, we observed that her digital ulcer was not healing sufficiently while she was in the hospital, so we began endothelin receptor antagonist therapy in addition to her previous therapy. A study showed that nine patients treated with bosentan for digital ulcer have complete recovery.<sup>11</sup>

### Conclusion:

Arrhythmias and conduction defects are frequent manifestations of cardiac involvement in patients with SSc. These abnormalities may be mild, but can also lead to a fatal outcome. Early recognition of life-threatening ventricular arrhythmias may be crucial in improving the overall prognosis of SSc patients. In this case addition of carvedilol improves the arrhythmia without decrement of Raynaud's phenomenon.

### References:

1. Varga J, Denton CP, Wigley FM. Scleroderma. New York: Springer; 2012. pp. 361–371; 373-395.
2. Dinser R, Frerix M, Meier FM, et al. Endocardial and myocardial involvement in systemic sclerosis—is there a relevant inflammatory component? *Joint Bone Spine*. 2013;80:320–323.
3. Lubitz SA, Goldbarg SH, Mehta D. Sudden cardiac death in infiltrative cardiomyopathies: sarcoidosis, scleroderma, amyloidosis, hemochromatosis. *Prog Cardiovasc Dis*. 2008;51:58–73.
4. Ridolfi RL, Bulkley BH, Hutchins GM. The cardiac conduction system in progressive systemic sclerosis. Clinical and pathologic features of 35 patients. *Am J Med*. 1976;61:361–366.
5. Clements PJ, Furst DE, Cabeen W, et al. The relationship arrhythmias and conduction disturbances to other manifestations of cardiopulmonary disease in progressive systemic sclerosis (PSS) *Am J Med*. 1981;71:38–46.
6. Ferri C, Bernini L, Bongiorno MG, et al. Noninvasive evaluation of cardiac dysrhythmias, and their relationship with multisystemic symptoms, in progressive systemic sclerosis patients. *Arthritis Rheum*. 1985;28:1259–1266.
7. Nie LY, Wang XD, Zhang T, Xue J. Cardiac complications in systemic sclerosis: early diagnosis and treatment. *Chin Med J* 2019; 132:2865–2871
8. J D Coffman, H M Rasmussen . Effects of beta-adrenoreceptor-blocking drugs in patients with Raynaud's phenomenon. [PubMed]. 1985 Sep;72(3):466-70. doi: 10.1161/01.cir.72.3.466.
9. De Luca G, Bosello SL, Gabrielli FA, et al. Prognostic Role of Ventricular Ectopic Beats in Systemic Sclerosis: A Prospective Cohort Study Shows ECG Indexes Predicting the Worse Outcome. *PLoS ONE* (2016) 11(4): e0153012. doi:10.1371/journal.pone.0153012
10. De Luca G, Bosello S, Parisi F, et al. AB0699 Beta-Blockers Control Frequent Ventricular Ectopic Beats in Systemic Sclerosis: A Monocentric Study *Annals of the Rheumatic Diseases* 2015;74:1131-1132
11. Launay D, Diot E, Pasquier E, et al . Bosentan for treatment of active digital ulcers in patients with systemic sclerosis; *Presse Med*;2006 Apr;35(4 Pt 1):587-92;