

# ATRIAL SEPTAL DEFECT CLOSURE DEVICE DISLODGE- MENT - EMERGENCY SURGICAL RETRIEVAL

RAHMAN M<sup>1</sup>, HOSSAIN MA<sup>2</sup>, HASAN MK<sup>3</sup>, KHAN OS<sup>4</sup>, SHAHA SK<sup>5</sup>, ADHIKARY AB<sup>6</sup>

## **Abstract:**

*Cardiac catheterization has changed its role from a diagnostic to therapeutic procedure. Interventional catheterization now played a significant role in the treatment of congenital heart diseases with technical skills and miniaturization of interventional tools, catheterization is still burdened by substantial risk. We presented a case of dislodgement of an atrial septal defect closure device that embolized to the right ventricle which required emergency surgical retrieval in a young adult done in the Department of Cardiac Surgery, Bangabandhu Sheikh Mujib Medical University (BSMMU), Dhaka.*

**Key words:** Atrial septal defect (ASD), cardiac catheterization, dislodgement of septal defect closure device

*J Dhaka Med Coll. 2012; 21(2) : 209-210.*

## **Introduction:**

Since the catheter based device closure era of atrial septal defects (ASDs) beginning 1976, the results have been favourable, with some authors reporting success rate in 94% range.<sup>1</sup> However, there are numerous reports of significant complications, including cardiac perforation, fistula formation,<sup>2</sup> thrombosis<sup>1</sup> and device dislodgement both to the systemic<sup>3</sup> and pulmonary circulation.<sup>4,5</sup> These have resulted in varying symptoms and degrees of hemodynamic compromise, most requiring surgical retrieval. We report a case of ASD closure device with profound circulatory collapse due to compromise of right ventricular outflow.

## **Case report:**

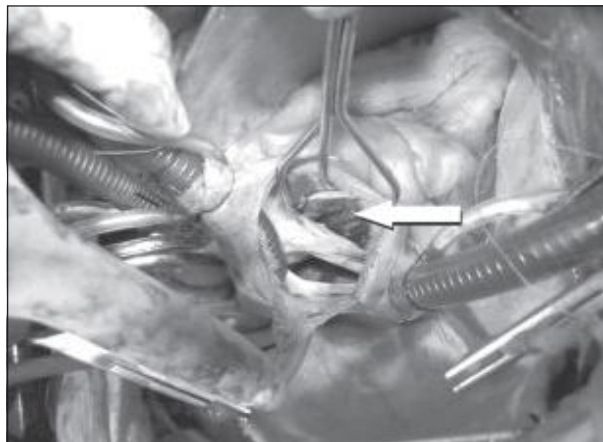
A 27 years old male patient weighting 56 kg underwent device closure of ASD in a cardiac catheterization laboratory. Preoperatively he was detected by transthoracic echocardi-

graphy to have a 14mm ostium secundum ASD with left to right shunt. Standard practice was adopted for deployment of the device. While attempting to position the left atrial disc, the disc could be seen on fluoroscopy, getting embolized to the tricuspid valve. The hemodynamic state of the patient was unstable with systolic blood pressure fluctuating between 70-90 mm of Hg, heart rate was above 150 beats/min. The ABG analysis revealed PaO<sub>2</sub> 85mm of Hg on FiO<sub>2</sub> 100%, PCO<sub>2</sub> 55 mm of Hg and base deficit of 5 mmol/L. The patient was taken emergently to the operating theatre, sternotomy was performed and cardiopulmonary bypass was established with bi-caval cannulation. The aorta was clamped and the heart was arrested with antegrade cardioplegia. The right atrium was opened and encountered a 14 mm secundum ASD. The device was found impinged to the tricuspid valve. It was grasped with a forceps and withdrawn from the right heart (Fig. 1). ASD

1. Dr. Mostafizur Rahman, Associate Professor, Department of Cardiac Surgery, Bangabandhu Sheikh Mujib Medical University (BSMMU), Dhaka.
2. Dr. Md. Aslam Hossain, Associate Professor, Department of Cardiac Surgery, Bangabandhu Sheikh Mujib Medical University (BSMMU), Dhaka.
3. Dr. Md. Kamrul Hasan, Associate Professor, Department Cardiac Surgery, NICVD, Dhaka
4. Dr. Omar Sadeque Khan, Medical Officer, Department of Cardiac Surgery, Bangabandhu Sheikh Mujib Medical University (BSMMU), Dhaka.
5. Dr. Sanjoy Kumar Shaha, Consultant, Department of Cardiac Surgery, Bangabandhu Sheikh Mujib Medical University (BSMMU), Dhaka.
6. Dr. Asit Baran Adhikary, Professor, Department of Cardiac Surgery, Bangabandhu Sheikh Mujib Medical University (BSMMU), Dhaka.

**Correspondence:** Dr. Mostafizur Rahman, Associate Professor, Department of Cardiac Surgery, Bangabandhu Sheikh Mujib Medical University (BSMMU), Dhaka. E-mail: ratan\_cts@yahoo.com

was slit like and was closed by direct suturing. Patient was gradually weaned from cardiopulmonary bypass. He was extubated after 4 hours of ventilation. The post-operative course was uneventful.



**Fig 1:** Dislodged ASD device in right ventricle.

#### Discussion:

Complications related to or outright failure of catheter based ASD closure devices are reportedly few and many cardiologists, percutaneous device closure of ASDs are standard treatment. This is in contrast to minimally invasive surgical closure, which in most institution carries a negligible risk. Agarwal and colleagues enumerated a number of reported complications dating back to the original implementation of ASD closure devices 30 years ago.<sup>6</sup> This included residual shunts, device malpositions possibly related to device size mismatched, caval thrombosis, pulmonary and systemic embolism, tearing of ASD ring itself and perforation of the heart. Many of these were not free from long term complications such as stroke or arrhythmias. Pattern of failure also depends partly on the mechanical structure of the device itself. We have presented a case of right heart embolization of an ASD device into the tricuspid valve annulus that occurred during deployment. Had this patient been not attendant on emergency basis he would almost certainly

have died. In our case, the clinical situation of respiratory distress and profound decrement in right ventricular function resulted in an emergency operation in an unstable young adult underscoring that while less invasive procedures are rather seductive in their perceived freedom from the morbidity and mortality of open heart surgery; they do carry a recognizable risk of serious adverse events. This potentially life threatening complications need to be weighed against the perceived advantage of a non-surgical, outpatient procedure when counseling the patient and their family regarding the alternative of minimally invasive surgical closure, which probably carries less overall risk and is less expensive.

#### References:

1. Bohm J, Bittigau K, Köhler F, Baumann G, Konertz W. Surgical removal of atrial septal defect occlusion system-devices. *Eur J Cardiothorac Surg* 1997; 12(6): 869-72.
2. Amin Z, Hijazi ZM, Bass JL, Cheatham JP, Hellenbrand WE, Kleinman CS, Erosion of Amplatzer septal occluder device after course of secundum atrial septal defects: review of registry of complications and recommendations to minimize future risk. *Catheter Cardiovasc Interv* 2004; 63(4): 496-502.
3. Verma PK, Thingnam SK, Sharma A, Teneja JS, Varma JS, Grover A. Delayed embolization of Amplatzer septal occluder device: an unknown entity - a case report. *Angiology* 2003; 54(1): 115-8.
4. Mashman WE, King SB, Jacobs WC, Ballard WL. Two cases of late embolization of Amplatzer septal occluder devices to the pulmonary artery following closure of secundum atrial septal defects. *Cather Cardiovasc Interv* 2005; 65(4): 588-92.
5. Contrafouris CA, Chatzis AC, Giannopoulos NM, Milonakis M, Kousi T, Kirvassilis G, et al. Emergency surgical intervention for runaway atrial septal defect closure devices: a word of caution. *J Thorac Cardiovasc Surg* 2006; 132(5):1234-5.
6. Agarwal SK, Ghosh PK, Mittal PK. Failure of devices used for closure of atrial septal defects: mechanisms and management. *J Thorac Cardiovasc Surg* 1996; 112(1): 21-6.