

## CASE REPORTS

# SPONDYLITIS PRESENTING WITH CAUDA EQUINA SYNDROME IN A 12 YEAR OLD BOY

DAS S<sup>1</sup>, ASHFAQ M<sup>4</sup>, JAHAN KFI<sup>2</sup>, KHAN SI<sup>3</sup>, ISLAM R<sup>4</sup>, ISLAM MM<sup>4</sup>

### Abstract

A 12-year-old boy presented with a 2-week history of low back pain and 10-day history of weakness of the lower limbs, 5-day history of inability to pass urine. An MRI scan of the lumbar spine showed dehiscent lamina of L5, S1 and an epidural abscess. He was admitted to hospital and treated with a high dose of IV antibiotics followed by radical surgical excision of the lesion. Histopathology showed features of abscess. He eventually recovered bowel and bladder control and regained muscle power in the lower limbs. Infection is not a common cause of cauda equina syndrome. Aggressive surgical treatment combined with a prolonged antibiotic regime is recommended to achieve a satisfactory result.

**Key words:** Cauda equina, Epidural abscess, Dehiscent lamina.

*J Dhaka Med Coll. 2019; 28(1) : 119-122*

### Introduction

Infections in the spine can lead to a wide range of problems for both the patient and physician. There is perhaps no more devastating complication than the neurological consequences of a cauda equina syndrome due to spinal infection<sup>1</sup>. Patient outcome following treatment of a spinal epidural abscess varies depending on a number of factors. Those with multiple medical condition or a history of spinal surgery appear to have worse outcomes<sup>1,3,4,5</sup>. In general the goals of treatment of infections include disease eradication, pain relief, preservation of neurological function and spinal stability<sup>6,7</sup>.

### Case Report

A 12 year old boy came with Low back pain for 15 days, Weakness of both lower limbs for 10 days, Inability to pass urine for 5 days.

**On local examination :** No gibbus or any spinal deformity, tenderness on palpation in L4,5 region, restriction of lumbar spine movement.

### On lower limb examination :

**Motor:** MRC 4/5 in right, 3/5 in left, ankle jerk absent bilaterally, SLR 60 degree in right, 40 in left. **Sensory:** Reduced sensation along L5, S1 dermatome in left.

Haematological investigation reveals, TC : 18000/cmm of blood

DC: Neutrophil: 78%, Lymphocyte: 15%, Monocyte: 4%

Eosinophil: 2%, Hb: 13 gm/dl, ESR: 33 mm in 1<sup>st</sup> hour.

MRI of lumbosacral spine showing, there is a lesion in L5, S1 region which is isointense to hypointense in both T1, T2 weighted images [A,C] and there is mild peripheral contrast uptake in contrast image [B]. There is dehiscence of L5, S1 posterior bony complex appreciated in axial cuts [Figure: 2].

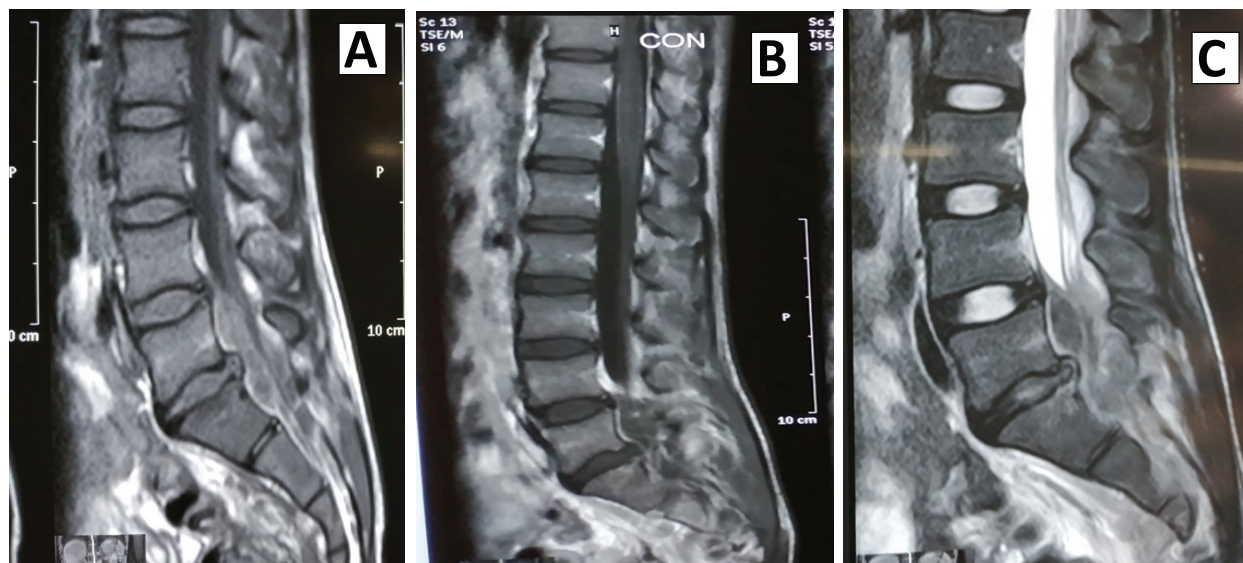
- 1 Dr. Sukriti Das, Associate Professor, Department of Neurosurgery, Dhaka Medical college Hospital, Dhaka, Bangladesh
- 2 Dr. Kaniz Fatema Ishrat Jahan, Assistant Professor, Department of Neurosurgery, Dhaka Medical college Hospital, Dhaka, Bangladesh
- 3 Dr. Shamsul Islam Khan, Medical Officer, Department of Neurosurgery, Dhaka Medical college Hospital, Dhaka, Bangladesh
- 4 Dr. Musannah Ashfaq, Dr. Rakibul Islam, Dr. Md. Moidul Islam, Resident, Department of Neurosurgery, Dhaka Medical college Hospital, Dhaka, Bangladesh

**Correspondence:** Dr. Musannah Ashfaq, Resident, Department of Neurosurgery, Dhaka Medical college Hospital Dhaka, Bangladesh

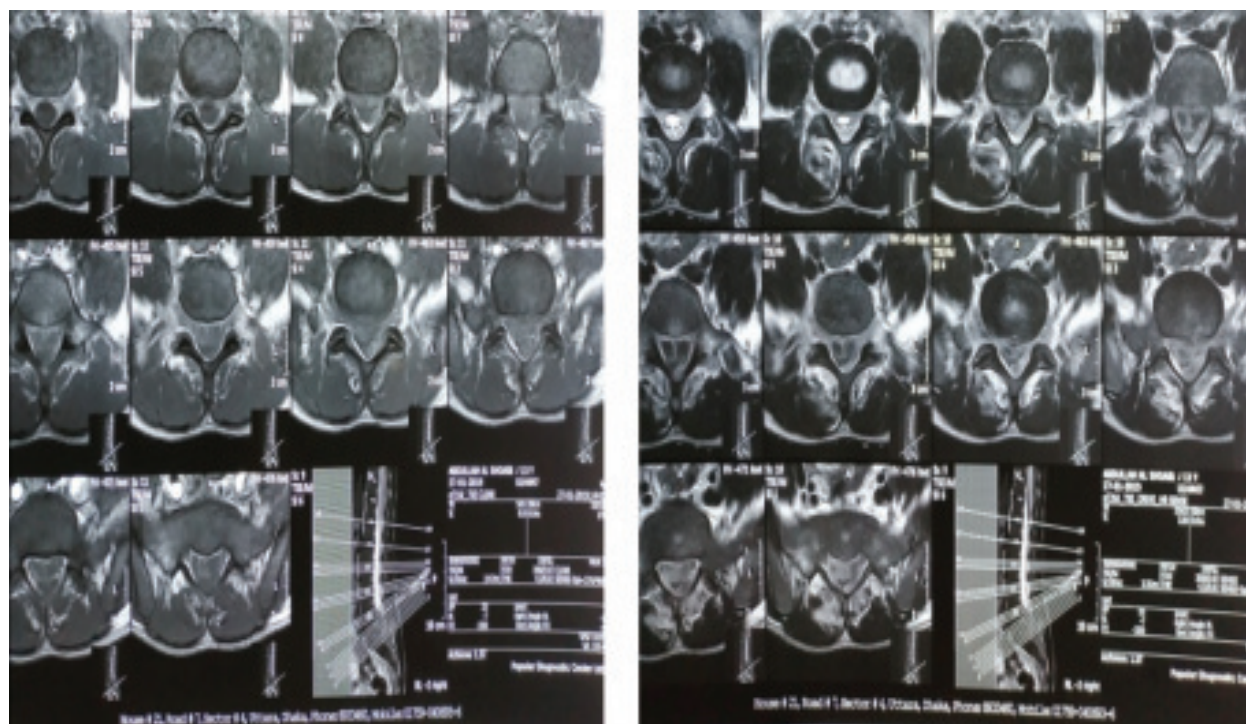
**Received:** 10 February 2019

**Revision:** 02 March 2019

**Accepted:** 30 March 2019



**Fig.-1:** (A) MRI of lumbosacral spine sagittal section showing isointense lesion in L5,S1 region (C) isointense to hypointense in T2 weighted images [B] mild peripheral contrast uptake.

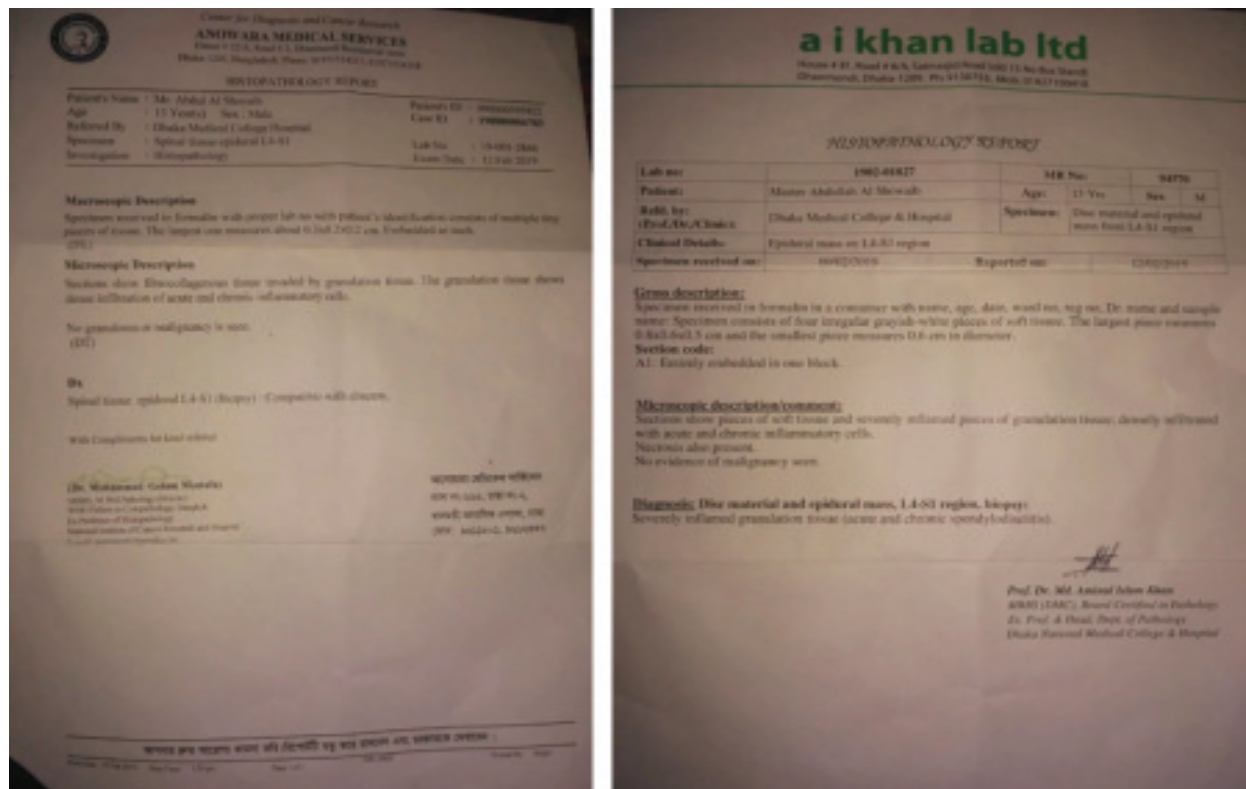


**Fig.-2:** MRI Lumbosacral spine axial section showing dehiscence of L5, S1 posterior bony complex

**Surgical procedure**

A posterior midline incision was approached from L3 to S1 . Dissection carried out carefully. There was dehiscence lamina of L4, L5 vertebra. There was bony gap between L4-5 & L5-S1 region. Granulation tissue seen

with necrotic materials. Posterior decompression and foraminotomy done. Tissue sent for histopathology. Histopathology was reported as abscess or spondylitis [Figure:3].



**Fig.-3:** Histopathological examination reveals as abscess or spondylitis.

**Discussion**

Pyogenic spinal epidural abscesses are a rare but clinically important entity with an overall incidence of between 0.2 and 1.2 cases/10,000 hospital admissions<sup>8,9</sup>.

The initial diagnosis of a spinal epidural abscess is often difficult because the classic clinical triad of fever, back pain, and progressive neurological deficit is not always present. On clinical presentation, back pain is the most common physical symptom (85–90% of patients)<sup>3,4</sup>.

Both ESR and Creactive protein level are typically elevated following any spinal procedure (including lumbar puncture).<sup>36</sup> Thus, although they can be useful markers of the effectiveness of treatment of a spinal epidural abscess, their diagnostic value is limited<sup>10</sup>.

In the presence of an infection, T2weighted signal intensity will increase due to the associated edema, whereas T1-weighted signal intensity will decrease due to replacement of the marrow fat.<sup>1,2</sup> Gadolinium enhancement can help differentiate infection from postsurgical change and pus from granulation tissue. This

combination allows MR imaging studies to be 95% accurate in the diagnosis of spinal infections and epidural abscesses<sup>16</sup>.

The mainstay of treatment for spinal epidural abscess is surgical decompression of the thecal sac with drainage of the abscess and long-term antibiotic therapy<sup>12</sup>. The surgical approach for decompression should be modified based on particular characteristics of the case including the location of the infection (anterior compared with posterior), the region of the spine involved (cervical, thoracic, or lumbar), the presence of a significant bone or paraspinal abscess.

The result of treating of epidural infections can be quite remarkable. With nonsurgical management, most areas of destruction will undergo some degree of autofusion.

A significant proportion of patients with neurological deficits will demonstrate a progressive return to neurological function.

**Conclusion**

Cauda equina syndrome associated with spinal infections can result in devastating outcomes

in patients. Based on the nature of the infection (pyogenic compared with nonpyogenic) and the duration of symptomatology, either surgical or nonsurgical care can play a pivotal role in the long-term outcome in a patient. In general, recently progressive neurological deficits (that is, those occurring within 48 hours) require surgical intervention in almost all patients regardless of the nature of the infection. In patients with pyogenic abscesses without neurological deficits, medical management can be initiated, but any sign of decline in neurological function mandates surgical intervention.

### References

1. DAVID B. COHEN, 'Infectious origins of cauda equina syndrome' *Neurosurg Focus* 16 (6):e2, (2004):05-10
2. Sumit Batra, 'A rare etiology of cauda equina syndrome' *J Infect Dev Ctries* 2011; 5(1):079-082
3. Tang HJ, Lin HJ, Liu YC, et al: Spinal epidural abscess—experience with 46 patients and evaluation of prognostic factors. *J Infect* 45:76–81, 2002
4. Rigamonti D, Liem L, Sampath P, et al: Spinal epidural abscess: contemporary trends in etiology, evaluation, and management. *Surg Neurol* 52:189–197, 1999
5. Khanna PK, Malik GM, Rock JP, et al: Spinal epidural abscess: evaluation of factors influencing outcome. *Neurosurgery* 39: 958–964, 1996
6. Moon MS: Tuberculosis of the spine. Controversies and a new challenge. *Spine* 22:1791–1797, 1997
7. Sixth report of the Medical Research Council Working Party on Tuberculosis of the Spine: Five-year assessments of controlled trials of ambulatory treatment, debridement and anterior spinal fusion in the management of tuberculosis of the spine: studies in Bulawayo (Rhodesia) and in Hong Kong. *J Bone Joint Surg Br* 60:163–177, 1978
8. Schlossberg D, Shulman JA: Spinal epidural abscess. *South Med J* 70:669–673, 1977
9. Hakin RN, Burt AA, Cook JB: Acute spinal epidural abscess. *Paraplegia* 17:330–336, 1979
10. Thelander U, Larsson S: Quantitation of C-reactive protein levels and erythrocyte sedimentation rate after spinal surgery. *Spine* 17:400–404, 1992.