

# DUODENAL GASTROINTESTINAL STROMAL TUMOR: A RARE CAUSE FOR RECURRENT ANAEMIA

*J Dhaka Med Coll. 2009; 18(1) : 85-87*

AFTAB H<sup>1</sup>, ALAM J<sup>2</sup>, PERVEEN S<sup>3</sup>, HOSSAIN M Z<sup>4</sup>, AHMED F<sup>5</sup>, KIBRIA MG<sup>1</sup>

## Introduction:

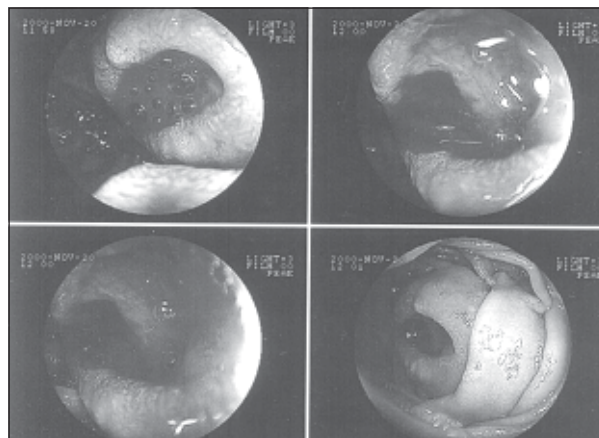
Gastrointestinal Stromal tumors are rare neoplasm that account for < 1% of all GI malignancies. GISTs arise rarely in the duodenum and clinical presentation is variable. This report describes a case of a GIST arising from the duodenum resulting in recurrent anaemia.

## Case Report

A 45 years old man admitted with the history of generalized weakness and anaemia for seven months. He gave history of occasional passage of black tarry stool. There was no history of fever, cough, jaundice, haematemesis, haematuria or any bowel alteration. His appetite was okay. There was no significant weight loss. Physical examination revealed moderate anaemia, others were unremarkable.

Laboratory findings at admission were as follows: Hb 6.2g/L, ESR 20 mm in 1<sup>st</sup> hour, complete blood count was otherwise within normal limit, peripheral blood film showed combined deficiency anaemia, blood glucose was normal, liver function tests and renal function tests were normal. He had a normal chest X-ray. Ultrasonography of abdomen showed an irregular hypoechoic mass size 53 x 42 along right lower aspect the duodenum. An upper gastrointestinal endoscopy (Fig-1) showed a large globular polypoid elevated lesion with central ulceration in the second part of the duodenum, biopsy from the lesion was not


conclusive. Colonoscopy and Barium follow through of small bowel revealed no abnormality. On exploratory laparotomy, an ulcerated growth was found in the second part of the duodenum proximal to the junction of 2<sup>nd</sup> and 3<sup>rd</sup> part of the duodenum, extending through the lateral wall. The growth with adequate margin was excised and prophylactic gastrojejunostomy was performed. Postoperative period was uneventful and patient was discharged on 10th postoperative day. Histopathology report showed spindle cells arranged in interlacing bundles and whorls having enlarged nuclei and high mitotic rate (Fig:II). Immunohistochemical analysis could not be performed due to lack of facilities. The patient refused to undergo radio chemotherapy. He remained symptom free for about a year and died from its' recurrence with distant metastasis.



**Fig.-1:** Endoscopic picture of Duodenal Gastrointestinal Stromal Tumor

1. Assistant Professor, Department of Gastroenterology, Dhaka Medical College, Dhaka
2. Assistant Professor, Department of Gastroenterology, Sylhet MAG Osmani Medical College, Sylhet.
3. Classified Medical Specialist, Combined Military Hospital (CMH), Patenga, Chittagong.
4. Assistant Professor, Department of Medicine, Dhaka Medical College, Dhaka
5. Professor, Department of Gastroenterology, Dhaka Medical College, Dhaka

**Correspondence:** Dr. Hazera Aftab



**Fig.-2:** Photomicrograph of Duodenal Gastrointestinal Stromal Tumor(H&E,x100)

### Discussion:

GISTs are a heterogeneous group of diseases that differ in frequency, clinical symptoms and pathologic behavior in patients. Until recently it was categorized as a tumor of smooth muscle derivation. In the mid 1980s GIST has been suggested as a distinct entity by Mazur and Clark<sup>(1)</sup> GISTs are low-grade malignant tumors that may arise anywhere in the alimentary tract, and in the past, most of them were diagnosed as intestinal leiomyoma or leiomyosarcoma<sup>(2)</sup>. Recently, they have been classified as c-kit- or CD34-positive mesenchymal tumors based on immunohistochemical and electromicroscopic approaches<sup>(3)</sup>. Distribution of these tumors in the alimentary tract are as follows, stomach (40%), jejunum (20%), ileum and rectum (14.3% each), duodenum (8.57%) and oesophagus (2.86%)<sup>(4)</sup>. The majority of patients present in the fifth to the seventh decade of life. Although a few studies show a male predominance (2:1)<sup>(5, 6)</sup> most indicate no sex prediction<sup>(7-11)</sup>

Small lesions of less than 2 cm are rarely symptomatic and are usually benign, often having been detected incidentally during the investigation of non-specific symptoms. Symptomatic lesions have manifestations that depend on tumor size, growth pattern, and location. When tumors become larger, however, they may stimulate bleeding, abdominal pain, anaemia, abdominal distension or abdominal mass. In the present paper, the patient complained of recurrent anaemia due to oozing of blood from overlying mucosal ulceration.

The diagnostic evaluation of GIST is similar to that of other GI malignancies. A double-contrast GI series may show a characteristic smooth-lined filling defect with clearly demarcated borders. Endoscopic examination characteristically reveals a smooth protrusion of bowel wall lined by intact mucosa, which may show signs of ulceration and or bleeding. Endoscopic ultrasonography (EUS) is a valuable imaging tool for this neoplasm. The diagnosis of a stromal tumor is based on the demonstration of a hypoechoic mass that is contiguous with the fourth hypoechoic layer (muscularis propria) of the normal gut wall. EUS may help differentiate benign form malignant stromal tumors. In one study, tumor size 4 cm, irregular extraluminal border, echogenic foci, and cystic spaces were independently associated with malignancy<sup>(12)</sup> Biopsy should be attempted. However, the majority of GISTs are situated submucosally, and the yield of obtaining adequate tissue is diminished. In a study by Conlon et al<sup>(13)</sup> only 49% of patients evaluated endoscopically had a histological diagnosis before surgery. Percutaneous fine-needle aspiration, although advocated by some authors for preoperative diagnosis<sup>(14)</sup> risks intra-abdominal tumor spillage and is not recommended. Computed tomography and magnetic resonance imaging are equally capable of delineating tumor extension. Recently positron emission tomography scanning has been shown to be more sensitive than MRI. The accurate diagnosis of GIST requires IHC staining for c-kit (CD 117) expression. Other antigenic markers (CD34, SMA, Desmin 2, S 100, Ki 67) are also variably positive.

It is often difficult to predict the clinical behavior of GIST. Many pathologists believe that none of GISTs are truly benign. So terminologies of the GISTs are being replaced "low risk" versus "high risk". Prognostic factors for high risk are large tumor size (> 5 cm), many mitotic figures (>5 per 50 HPF), fast growing and often infiltrating. Surgical resection has been the mainstay of therapy for GIST. It is essential to avoid tumor spillage or tumor rupture in the abdomen. They have been associated with an increased risk of peritoneal

recurrence<sup>(2)</sup>. Lymph node resection is not routinely performed because leiomyosarcoma does not spread via lymphatics. Recurrence of GIST is usual<sup>(15)</sup> The liver is the most common site of recurrence. Treatment options for recurrent and metastatic diseases have been limited. Clinical trials have shown that patients benefit from Imatinib therapy<sup>(16)</sup>. Regardless of the presentation, the disease specific survival rates with malignant duodenal stromal tumor are 69% at 1 year, 38%–44% at 3 years, and 29%–35% at 5 years<sup>(15)</sup>.

### References:

1. Crosby JA et al. Malignant Gastrointestinal Stromal Tumors of the small intestine: a review of 50 cases from a prospective database. *Annals of Surgical Oncology*, 2001; 8(1): 50-59.
2. Pidhorechly I, Cheney RT, Lraybill WG, Gibbs JF. Gastrointestinal stromal tumors: Current diagnosis, biologic behavior, and management. *Ann Surg Oncol* 2000;**7**:705–12
3. Mazur MT, Clark HB. Gastric stromal tumors. Reappraisal of histogenesis. *Am J Surg Pathol* 1983; 7:507–19
4. Fong-Fu Chou, Hock-Liew Eng, Shyr-Ming Sheen-Chen. Smooth muscle tumours of the gastrointestinal tract: Analysis and prognostic factors. *Surgery Feb. 1996*; 119 (2): 171-7.
5. Conlon KC, Casper ES, Brennan MF. Primary gastrointestinal sarcomas: analysis of prognostic variables. *Ann Surg Oncol* 1995; 2:26 –31.
6. He LJ, Wang BS, Chen CC. Smooth muscle tumours of the digestive tract: report of 160 cases. *Br J Surg* 1988; 75:184–6.
7. Spiliotis J, Scopa CD, Kyriakopoulou D, Pitsis A. Smooth muscle tumors of the gastrointestinal tract: a 10 year experience. *Eur J Surg Oncol* 1992; 17:580–4.
8. Ng E-H, Pollack RE, Romshdahl MM. Prognostic implications of patterns of failure for gastrointestinal leiomyosarcomas. *Cancer* 1991;69:1334–41.
9. Shiu MH, Farr GH, Papachristou DN, Hajdu SI. Myosarcomas of the stomach: natural history, prognostic factors and management. *Cancer* 1982; 49:177–187.
10. Chou FF, Eng HL, Sheen-Chen SM. Smooth muscle tumors of the gastrointestinal tract: analysis of prognostic factors. *Surgery* 1996; 119:171–7.
11. Evans HL. Smooth muscle tumors of the gastrointestinal tract: a study of 56 cases for a minimum of 10 years. *Cancer* 1985; 56:2242–50.
12. Chak A, Canto MI, Rosch T, Dittler HJ. Endosonographic differentiation of benign and malignant stromal cell tumors. *Gastrointest Endosc* 1997;45:468 –73.
13. Conlon KC, Casper ES, Brennan MF. Primary gastrointestinal sarcomas: analysis of prognostic variables. *Ann Surg Oncol* 1995;2:26 –31.
14. Dodd LG, Nelson RC, Mooney EE, Gottfried M. Fine-needle aspiration of gastrointestinal stromal tumors. *Am J Clin Pathol* 1998; 109:439–43.
15. De Matteo RP, Lewis JL, Leung D, et al. Two hundred gastrointestinal stromal tumors: Recurrence patterns and prognostic factors for survival. *Ann Surg* 2000; 231:51-7.
16. Demetri GD, Von Mehren M, Blanke CD, et al. Efficacy and safety of Imatinab mesylate in advanced Gastrointestinal stromal tumors. *N Engl J Med* 2002;347:472-80