

# A CASE OF MULTIPLE GASTROINTESTINAL ULCER: A RARE PRESENTATION OF STRONGYLOIDIASIS

BEGUM A<sup>1</sup>, MIAH MT<sup>2</sup>, A MALEKA<sup>3</sup>, PATWARY MSA<sup>4</sup>, DAS J<sup>5</sup>, ADNAN MA<sup>6</sup>, IMON RA<sup>7</sup>

## Abstract:

*Strongyloides stercoralis* is a common intestinal nematode in tropical and subtropical countries like Bangladesh. The presentation of this infection is nonspecific. Mostly it remains asymptomatic with peripheral eosinophilia. Immunocompromised individuals are at high risk of hyper infection to disseminated disease. We present a case of *Strongyloides* in an immunocompetent patient with features of gastric outlet obstruction. Laboratory findings revealed hypereosinophilia with multiple gastrointestinal ulcers on endoscopy. Biopsy was taken from a gastric ulcer which revealed ulceration and dense infiltration of acute and chronic inflammatory cells along with extensive intestinal metaplasia. There were tiny helminthic bodies within the mucosal glands and on the surface consistent with *Strongyloides stercoralis*. Routine examination of stool also revealed larvae of *Strongyloides stercoralis*.

**Keywords:** Gastric outlet obstruction, Hyperinfection, Intestinal metaplasia, *Strongyloides stercoralis*.

DOI: <https://doi.org/10.3329/jdmc.v31i1.65491>  
J Dhaka Med Coll. 2022; 31(1): 163-166

## Introduction

The soil-transmitted threadworm *Strongyloides stercoralis* is one of the most neglected helminth infections. The global prevalence of *S. stercoralis* infection is unknown, but it is estimated that more than three million people are infected worldwide. It is more prevalent in hot and humid climates and resource-poor countries with inadequate sanitary conditions, such as Asia, Africa, Southeast Asia, Bangladesh, and Central and South America.<sup>1</sup> In Bangladesh, the prevalence rate is 29.8% (21.7% - 39.8%, 95% CI) in a community-based survey.<sup>2</sup> Infected patients usually remain asymptomatic. The patient might present with peripheral eosinophilia or complain of a myriad of symptoms, including cough, wheezing, dyspnea, upper abdominal pain, nausea, vomiting, or diarrhea.

## Case Report

The patient was a 60-year-old male who presented with one month's history of vomiting and weight loss. Vomiting occurred 4 to 5 times a day, almost immediately after taking food containing undigested food particles. He had an occasional history of induced vomiting and hematemesis for two episodes since the symptoms started.

Sometimes he noticed a mobile mass in his abdomen passing from above to downwards. He lost about 6 kg of weight over the last month. On query, he gave the history of loose stool about one month ago, which persisted for 7-8 days, occurred almost 10-12 times a day and the content of stool was black with a minimal amount of fecal matter. There was no history of early morning vomiting, head injury, or any offending drugs, including steroids, radiation therapy, cough, chest pain, tinnitus, vertigo,

- 
1. Dr. Aysha Begum, Junior Consultant (Medicine), Upazila Health Complex, Keraniganj, Dhaka
  2. Dr. Md. Titu Miah, Principal and Professor of Medicine, Dhaka Medical College, Dhaka
  3. Dr. Maleka Ali, Medical Officer, National Institute of Kidney and Urology, Dhaka.
  4. Dr. Mohammad Shamsul Arefin Patwary, Asstt. Professor of Medicine, Dhaka Medical College, Dhaka.
  5. Dr. Jishu Das, Assistant surgeon, Upazila Health Complex, Sadar, Noakhali.
  6. Dr. Mirza Mohammad Asif Adnan, Asstt. Registrar of Medicine, Dhaka Medical College, Dhaka
  7. Dr. Refat Al Imon, Registrar of Medicine, Dhaka Medical College, Dhaka

**Correspondence:** Dr. Aysha Begum, Junior Consultant (Medicine), Upazila Health Complex, Keraniganj, Dhaka.  
E-mail: ayshadmc60@gmail.com, Cell +8801675184827

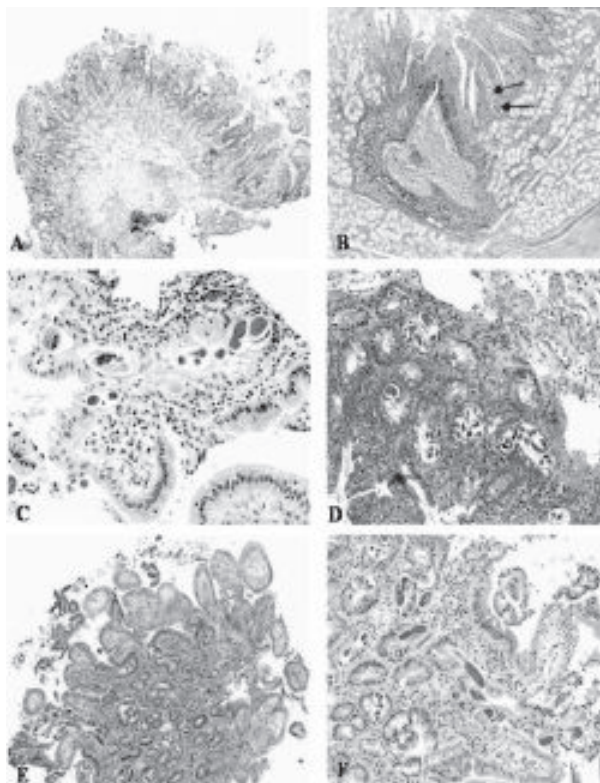
**Received:** 10-01-2022

**Revision:** 15-02-2022

**Accepted:** 16-03-2022

fever, jaundice, itching, abdominal pain, and constipation. He didn't give any history of steatorrhea. He was a smoker and used to take 15 sticks per day. On examination, he was ill-looking and mildly anemic. Abdominal examination revealed visible peristalsis.

The blood count showed: Haemoglobin 9.8gm/dl, the total count of WBC 8,400/cm<sup>3</sup>. On differential, the neutrophil count was 70%, lymphocyte-20%, monocyte-4.6%, and eosinophil-20.3%. ESR was 15 mm in 1st hr, and PBF revealed microcytic hypochromic anemia with eosinophilia. Serum electrolyte revealed mild hyponatremia with mild hypokalaemia. Serum calcium, SGPT, creatinine, and chest X-ray were normal. Random blood sugar was also normal, and anti-HIV 1 & 2 was negative.

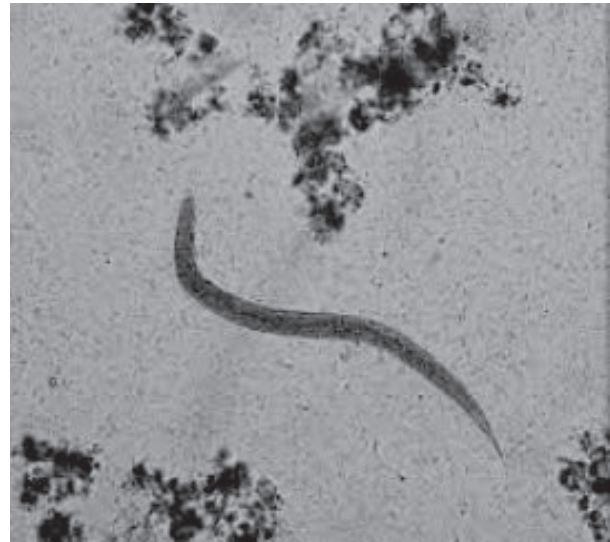

**Fig.-1:** Gastric mucosa showing infiltration of mucosa with inflammatory cells (white arrow) and tiny helminthic body of *Strongyloides stercoralis* within mucosal gland (black arrow).

Endoscopy of upper GIT showed multiple linear lesions in the lower end of the esophagus, extensive antral ulceration involving the pyloric

ring, and the duodenal bulb was oedematous, congested, and contained few ulceration.

Biopsy was taken from a gastric ulcer which revealed ulceration and dense infiltration of acute and chronic inflammatory cells along with extensive intestinal metaplasia. There were tiny helminthic bodies within the mucosal glands and on the surface consistent with *Strongyloides stercoralis*.



**Fig.-2:** Routine microscopic examination of stool showing larvae of *Strongyloides stercoralis* (black arrow).

Stool R/E was also sent and revealed larvae of *Strongyloides Stercoralis*.

Then this patient was treated with Tab. Albendazole, 400 mg orally two times a day for 7 days and he also got treatment symptomatically. After 4 weeks of discharge, he came to us with a report of stool R/E and it revealed clearance of infection.

#### **Discussion:**

The threadworm *Strongyloides stercoralis* is a soil-transmitted nematode and one of the most overlooked helminths among neglected tropical diseases (NTDs).<sup>3</sup> *S. stercoralis* was first described in 1876. The human life cycle, pathology, and clinical features were fully disclosed in the 1930s. The rhabditiform larvae are excreted in the stool of infected individuals. The larvae molt twice and then develop into infective 3rd stage filariform larvae, which can

infect a new host by penetrating intact skin. The larvae thrive in warm, moist/wet soil. Walking barefoot and engaging in work involving skin contact with the ground and low sanitary standards are risk factors for infection. After penetration, the larvae travel through the bloodstream to the lungs, where they break into the alveolar spaces, ascend the bronchial tree, are swallowed, and reach the small intestine. There the larvae mature into adult worms that penetrate the mucosa of the proximal bowel. Eggs hatch in the intestinal mucosa, releasing rhabditiform larvae that migrate to the lumen and pass with feces into the soil. Alternatively, rhabditiform larvae in the bowel can develop directly into filariform larvae that penetrate the colonic wall or perianal skin and enter the circulation to repeat the migration that establishes ongoing reinfection. This autoinfection cycle allows strongyloidiasis to persist for decades.<sup>1</sup>

Upper gastrointestinal ulcer due to *Strongyloides stercoralis* infection is rare in immunocompetent patients, with only one case reported. Patients with a compromised immune system are predisposed to disseminated disease that involves multiple systems with subsequent possible septic shock. Patients with a history of the human immunodeficiency virus (HIV) or human T-lymphotropic virus (HTLV-1) infection, malignancy, current chemotherapy, corticosteroid use, malnutrition, chronic pulmonary diseases, diabetes mellitus, or alcoholism are at a high risk of disseminated *Strongyloides stercoralis*.<sup>4</sup> In our case, we didn't find any underlying possible risk factors.

High eosinophil counts in the serum should prompt the provider to screen for parasitic disease. If there is still a strong suspicion, the absence of eosinophilia is not sensitive enough to rule out helminthic infections because eosinophils are mainly tissue-dwelling cells. In a study by Loutfy et al.<sup>5</sup>, sixty-nine of seventy-six patients positive for *Strongyloides stercoralis* diagnosed by stool tests had peripheral eosinophilia. In this pool of patients, the highest eosinophil count was 3310 eosinophil/mm<sup>3</sup>, and the median was 740

eosinophil/mm<sup>3</sup>. Absolute eosinophil count in the serum has been graded as mild (500/mm<sup>3</sup> to 1,500/mm<sup>3</sup>), moderate (1,500/mm<sup>3</sup> to 5,000/mm<sup>3</sup>), and severe (more than 5,000/mm<sup>3</sup>). Usually, moderate eosinophilia is required before tissue damage occurs; however, there is no reliable level that precisely reflects the concentration of the activated eosinophils within the affected tissue.<sup>5</sup> Our patient had a total white blood cell (WBC) count of 8,400/mm<sup>3</sup>; the eosinophil count was 1705/mm<sup>3</sup>, accounting for twenty percent of all WBCs. *Strongyloides stercoralis* nematode infection induced a dramatic local inflammatory response in an immunocompetent patient, as indicated by the absolute value of eosinophil cells. This extremely high number of eosinophils released an increased amount of toxic granules that produced multiple ulcerations in the upper gastrointestinal tract.<sup>5,6</sup> In our case, upper GI endoscopy revealed multiple ulcers involving the pyloric ring and duodenal bulb. It may be suggested that the eosinophilic cells played a central role in forming multiple ulcers.

Although the serological test enzyme-linked immunosorbent assay (ELISA) for diagnosing strongyloidiasis is highly sensitive (reaching up to 90%), the test is not always available, does not discriminate recent from old infections, and shows cross-reaction with other helminth infections. Thus the pathological examination of tissue sections and aspirate material gives the definitive diagnosis.<sup>7</sup>

In our case, the patient had a short history of gastrointestinal symptoms consistent with gastric outlet obstruction, which was relieved following the treatment of strongyloidiasis.

### Conclusion

Though the presentation of *Strongyloides stercoralis* in immunocompetent individuals is versatile, a high index of suspicion should be needed. Otherwise, diagnosis of this readily treatable disease may be missed.

### Conflict of Interests

The authors declare that there is no conflict of interests regarding the publication of this paper.

**References**

1. Weller PF. Infectious disease. In Fauci AS, Kasper DL, Longo DL, Braunwald E, Loscalzo J, editors. *Harrison's Principles of Internal Medicine* 16<sup>th</sup> ed. Philadelphia: McGraw-Hill;2008. P.1233-1237.
2. Schar F, Trostorf Ulf, Giardina F et al. *Strongyloides stercoralis* : Global Distribution and Risk Factors. *PLOS Neglected Tropical Diseases*: vol.7, issue.7, e2288, July 2013.
3. Olsen A, van Lieshout L, Marti H, Polderman T, Polman K, et al. (2009) *Strongyloidiasis*—the most neglected of the neglected tropical diseases? *Trans R Soc Trop Med Hyg* 103: 967–972.
4. P.B. Keiser and T. B. Nutman, “*Strongyloides stercoralis* in the immunocompromised population,” *Clinical Microbiology Reviews*, vol.17, no.1, pp.208–217, 2004.
5. L. Zuo and M. E. Rothenberg, “Gastrointestinal eosinophilia,” *Immunology and Allergy Clinics of North America*, vol.27, no.3, pp.443–455, 2007.
6. P.F. Weller, “The immunology of Eosinophils,” *The New England Journal of Medicine*, vol.324, pp.1110–1118, 1991.
7. Agrawal V, Agarwal T, Ghoshal UC. *Intestinal strongyloidiasis: a diagnosis frequently missed in the tropics*. *Trans R Soc Trop Med Hyg* 2009; 103: 242–6.