

# <sup>99m</sup>Tc RBC SCINTIGRAPHY IN THE DIAGNOSIS OF HEPATIC HAEMANGIOMA

HAQUE MM<sup>1</sup>, JANNAT SNE<sup>1</sup>, SALIMULLAH ASM<sup>1</sup>, SAHA A<sup>1</sup>, DATTA PK<sup>2</sup>

DOI: <https://doi.org/10.3329/jdmc.v31i1.65492>  
J Dhaka Med Coll. 2022; 31(1): 167-169

A 63 years old man with unremarkable medical history was admitted to Department of Gastroenterology of Dhaka medical college on 12<sup>th</sup> July, 2022 for evaluation of his intra abdominal lump that had been progressively enlarging for last 3 years. On admission, the patient had hugely distended abdomen which was completely occupied by the mass. General examination and other systemic examination revealed no other abnormality. Routine blood tests revealed low hemoglobin level (8.9 gm/dl), low Hematocrit (28%), normal WBC count (8800/<sup>3</sup>mm), thrombocytopenia (108000/<sup>3</sup>mm), normal reticulocyte count. Peripheral blood film showed hypochromic, macrocytic anaemia with thrombocytopenia. Liver function tests were normal with absence of viral markers for chronic hepatitis. D-dimer level was high (20 mcg/ml, reference value <0.5 mcg/ml) with slightly prolonged Prothrombin time (14.6 sec, control 14 sec) and activated partial thromboplastin time (32.5 sec, control 30 sec). For evaluation of thrombocytopenia, bone marrow was also studied which showed erythroid hyperplasia. USG of abdomen revealed gross hepatomegaly with a fairly large (10.4 x 9.6 cm) mixed echogenic focal lesion and multiple mixed echogenic focal lesion of variable size in both lobes of liver- suggestive of haemangioma.

CT scan of abdomen revealed gross hepatomegaly with vascular malformation predominantly in left lobe of liver. Then, <sup>99m</sup>Tc RBC scan of liver was done for further clarification as the patient had thrombocytopenia with coagulopathy. In <sup>99m</sup>Tc RBC scan of liver, Dynamic flow images showed increased radiotracer uptake throughout the hepatic parenchyma with a focal area of increased tracer activity that persisted at sequential images and at delayed planar images. There was gradual washout of tracer from rest of the hepatic parenchyma. All these findings are highly specific for haemangioma.

Finally, a working diagnosis of Kasabach Merritt Syndrome (KMS) was made on the presentations of unexplained thrombocytopenia, coagulopathy and hepatic haemangiomas. Biopsy of the hepatic haemangioma was not performed because of high risk of bleeding. After diagnosis, oral prednisolone (1 mg/kg daily, with a slow taper) and propranolol were started. Surgical opinion was sought from department of surgery of the same institute and surgery was declined because of extensive liver invasion. The patient was then discharged with advice for follow up.

1. Dr. Mohammad Majharul Haque, Dr. Syeda Nur E Jannat, Dr. ASM Salimullah, Dr. Amitav Saha, Assistant Professor, Department of Gastroenterology, Dhaka Medical College, Bangladesh.

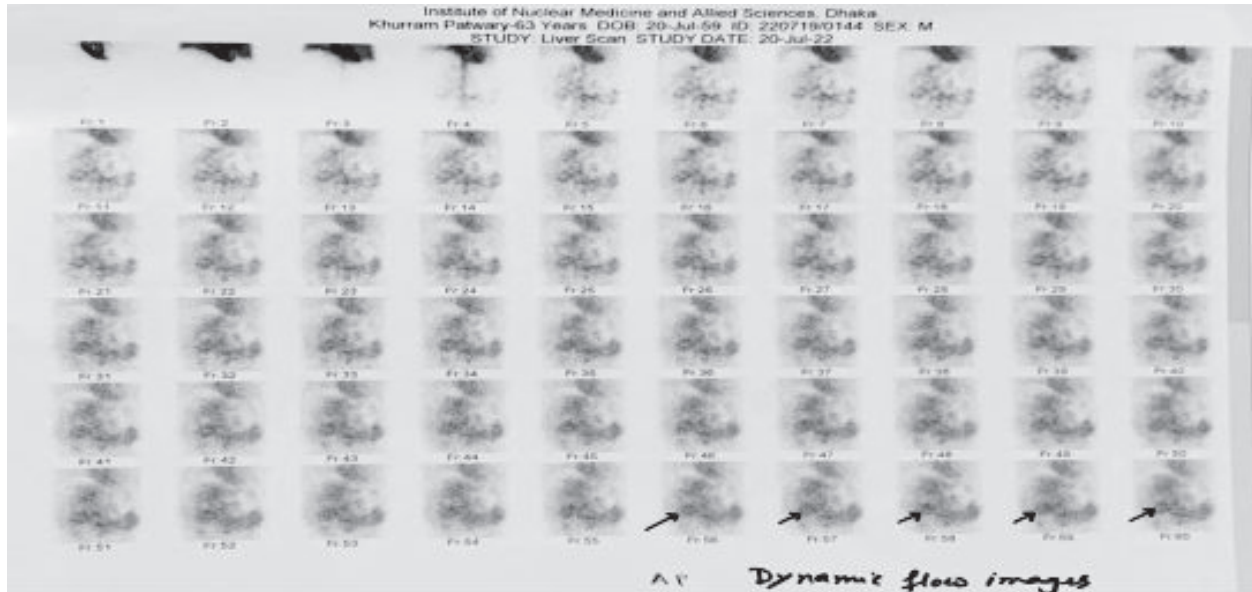
2. Dr. Ponkaj Kanti Datta, Assistant professor, Department of Medicine, Dhaka Medical College, Bangladesh.

**Corresponding author:** Dr. Mohammad Majharul Haque, Assistant Professor, Department of Gastroenterology, Dhaka Medical College. Email: majharhq@gmail.com

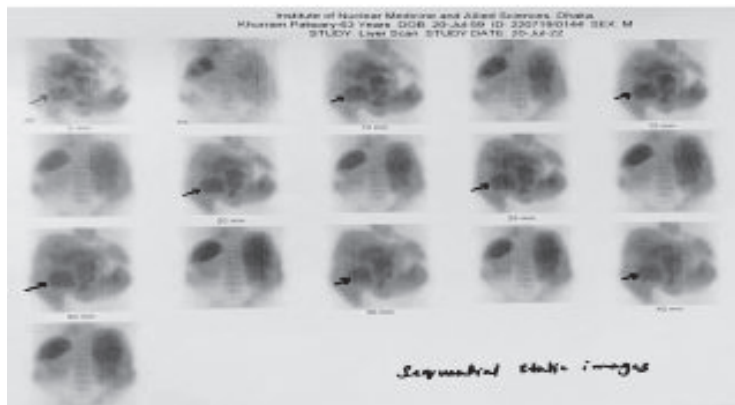
**Received:** 22-01-2022

**Revision:** 26-02-2022

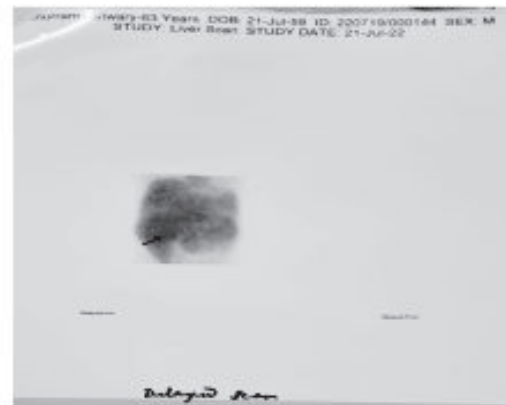
**Accepted:** 21-03-2022



(a) Dynamic flow image



(b) Sequential static image



(c) Delayed image

**Fig.** <sup>99m</sup>Tc RBC scintigraphy

**Discussion:**

Hepatic haemangiomas are the most common benign tumor of liver with an estimated prevalence of 7%.<sup>1</sup> They consist of blood-filled cavities fed by the hepatic arterial circulation, with walls lined by a single layer of endothelial cells.<sup>2</sup> They are congenital malformation which increase in size with the growth of liver. They can affect both sex and can occur at any age. They are usually asymptomatic, mostly discovered incidentally but giant hepatic haemangioma (>4 cm) can cause symptoms like abdominal discomfort, abdominal fullness, pain or even rupture.<sup>3</sup> Morbidity is related to haemorrhage, disseminated intravascular

coagulation, local invasion of vital structures, high output cardiac failure, multiorgan failure, or sepsis.<sup>4</sup> The main challenge in diagnosing hepatic haemangioma is to differentiate them from other hepatic lesion like adenoma, hepatocellular carcinoma, focal nodular hyperplasia and vascular metastases.

Ultrasound (US) is usually the first diagnostic step for hepatic haemangioma because of its wide availability and lack of radiation. The main limitation of US is that it is highly operator and patient-dependent. US has a good accuracy in differentiating small hepatic haemangioma <3 cm from malignant hyperechoic masses

(sensitivity of 94.1% and specificity of 80.0%). But, with the increase in size of haemangioma, its sensitivity and specificity decrease.<sup>5</sup>

CT scan also has good sensitivity and specificity in diagnosing hepatic haemangioma. But atypical haemangioma can show different enhancement pattern on CT. Hepatic haemangioma that are homogenous and rapidly enhancing in the arterial phase can be mistaken for hypervascular tumors. Moreover, CT has the limitation of radiation and use of iodinated contrast.<sup>6</sup>

On MRI, the typical appearance is a well-demarcated, homogenous lesion, hypointense on T1-weighted images and hyperintense on T2-weighted images.<sup>5</sup> But MRI may not be able to distinguish haemangioma from vascular metastases and also less sensitive for haemangioma >3 cm.

<sup>99m</sup>Tc RBC scintigraphy is a noninvasive method, which provides the most specific diagnosis of hepatic haemangioma. The characteristic, diagnostic presentation of Hepatic haemangioma on Tc-99 labeled RBC images is perfusion/ blood pool mismatch: decreased perfusion on early dynamic images and a gradual increase in activity on blood pool images over time.<sup>5</sup>

<sup>99m</sup>Tc RBC scan, in contrast to MRI, can also distinguish haemangioma from vascular metastases and can identify haemangioma more accurately when size is >2 cm. Limitation of <sup>99m</sup>Tc RBC scan is its difficulty to evaluate deeply seated lesion or lesion adjacent to normal vascular structures. Other limitations are reduced availability and its irradiating nature.

#### References:

1. Ishak KG, Rabin L. Benign tumors of the liver. *Med Clin North Am* 1975;59:995-1013.
2. Kim KW, Kim TK, Han JK, et al. Hepatic hemangiomas: spectrum of US appearances on gray-scale, power Doppler, and contrast-enhanced US. *Korean J Radiol.* 2000;1:191-197.
3. Edmondson HA. Tumors of the liver and intrahepatic bile ducts. In: *Atlas of tumor pathology. Section vii, Fascicle 25* Washington DC, Armed Forces Institute of Pathology, 1958 ;113.
4. Maguiness S, Guenther L. Kasabach-Merritt syndrome. *Journal of Cutaneous Medicine & Surgery.* 2002;6:335-9.
5. Bajenaru N, Balaban V, Săvulescu F, Campeanu I, Patrascu T. Hepatic hemangioma –review. *J Med Life.* 2015;8: 4-11.
6. Tateyama A, Fukukura Y, Takumi K, Shindo T, Kumagai Y, Kamimura K, Nakajo M. Gd-EOB-DTPA-enhanced magnetic resonance imaging features of hepatic hemangioma compared with enhanced computed tomography. *World J Gastroenterol.* 2012;18, 43:6269-6276.