

BARDET-BIEDL SYNDROME: A CASE REPORT

ISLAM A¹, RAHMAN MM², DATTA PK³, SAJIB MKH⁴, IMRAN MRA⁵, HAQUE MM⁶, SAIKOT MAM⁷, KHAN MS⁸, KHAN MAD⁹, SAKIB KN¹⁰, MITRA A¹¹.

Abstract:

Bardet-Biedl syndrome (BBS) is a rare autosomal recessive multisystem involvement genetic disorder with a broad spectrum of clinical presentations. It is characterized by rod-cone dystrophy, polydactyly, obesity, learning disabilities, hypogonadism in males or genital abnormalities in females, and renal impairment. We present a case of a 12-year-old boy who complained of gradual loss of vision (particularly noticeable at night), obesity, hypogonadism, and polydactyly. In addition, he had postaxial polydactyly in all limbs, obesity, retinitis pigmentosa, learning disabilities, hypogonadism, speech delay, developmental delay, astigmatism, and acanthosis nigricans. Multidisciplinary approaches need to manage this disorder and need regular follow-up. Genetic counselling is essential.

Keywords: Hypogonadism, Polydactyly, Obesity, Retinitis pigmentosa, Learning disabilities, Bardet-Biedl syndrome.

DOI: <https://doi.org/10.3329/jdmc.v31i2.73176>
J Dhaka Med Coll. 2022; 31(2) : 264-267

Introduction:

Laurence-Moon-Bardet-Biedl syndrome (LMBBS) is a rare ciliopathic, pleiotropic autosomal recessive defect that mainly occurs in children born from consanguineous marriages. Incidence rates in North America and Europe vary from 1:140,000 to 1:160,000 live births. Conversely, the rate is much greater in Kuwait and Newfoundland, with an estimated frequency of 1:13,500 and 1:17,500, respectively¹.

Laurence and Moon described four cases of retinitis pigmentosa accompanied by obesity, hypogonadism, and spastic paraplegia in 1886². Bardet³ and Biedl⁴ described patients with obesity, retinitis pigmentosa, polydactyly, mental retardation, and hypogonadism.

Laurence-Moon-Bardet-Biedl syndrome is no longer considered a valid term because

Laurence and Moon described paraplegia but no obesity or polydactyly, which is the crucial feature of Bardet-Biedl syndrome. Laurence-Moon syndrome and Bardet-Biedl syndrome is now considered separate entity⁵. Diagnosis of Bardet-Biedl syndrome mainly depends on clinical features. Beales et al. [1999] have suggested that the presence of four primary features or three primary features plus two secondary features is diagnostic⁶ (Table 1)

Case report:

A 12-year-old boy, the first born child of nonconsanguineous parents, came to the medicine department of Dhaka Medical College Hospital, Bangladesh, with complaints of gradual blurring of vision for the past three years. The mother noticed that the child could not see well, which was evident by repeated falls while walking on uneven surfaces at night, the

1. Dr. Aminul Islam, FCPS trainee, Department of Medicine, Dhaka Medical College Hospital, Dhaka.
2. Dr. Md. Motlabur Rahman, Associate professor, Department of Medicine, Dhaka Medical College Hospital, Dhaka.
3. Dr. Ponkaj Kanti Datta, Assistant professor, Department of Medicine, Dhaka Medical College Hospital, Dhaka.
4. Dr. Md. Kamrul Hasan Sajib, Register, Department of Medicine, Dhaka Medical College Hospital, Dhaka.
5. Dr. Md. Rakib Al Imran, Assistant register, Department of Medicine, Dhaka Medical College Hospital, Dhaka.
6. Dr. Md. Manjurul Haque, Indoor Medical Officer, Department of Medicine, Dhaka Medical College Hospital, Dhaka.
7. Dr. Md. Ahsan Ul Matin Saikot, Indoor Medical Officer, Department of Medicine, Dhaka Medical College Hospital, Dhaka.
8. Dr. Md. Sanaullah Khan, Indoor Medical Officer, Department of Medicine, Dhaka Medical College Hospital, Dhaka.
9. Dr. Md. Abu Daud Khan, Indoor Medical Officer, Department of Medicine, Dhaka Medical College Hospital, Dhaka.
10. Dr. Kazi Nazmus Sakib, Indoor Medical Officer, Department of Medicine, Dhaka Medical College Hospital, Dhaka.
11. Dr. Anik Mitra, Indoor Medical Officer, Department of Medicine, Dhaka Medical College Hospital, Dhaka.

Address of Correspondence: Dr Aminul Islam, Department of Medicine, Dhaka Medical College Hospital, Dhaka.
Mobile: 01818152629 Email: dr.aminul14@gmail.com

Received: 13/06/2022

Revision: 17/07/2022

Accepted: 19/08/2022

inability to see letters of the alphabet in books and unable to ride a bicycle in the daytime. The boy started to go to school at the age of 5 years. The first two years of his learning period were uneventful, but after that, his learning abilities were reduced day by day. Now he is incapable of memorizing his learning subjects and his friends. He was born at home by expected vaginal delivery with an extra digit of all four limbs. His birth weight was 4 kg with small size of external genitalia. For his childhood obesity, his parents consulted with a physician, and the physician gave only dietary advice. He had delayed developmental milestones as far back as his mother could remember, such as speech starting at two years and walking at 2.5 years. Patient mention that his sister was also diagnosed as Bardet-Biedl Syndrome (BBS). He was immunized as per the expanded program of immunization (EPI) schedule.

On examination, he had facial puffiness, depressed nasal bridge, hexadactyly in all four limbs, weight 75 kg, height- 155 cm, and Body mass index (BMI) 31.21 kg/m², which was more than 95 percentiles according to his age. Stretched penile length (SPL) was 2.5 cm, testicular volume (TV) was 5 ml, and axillary and pubic hair was at the prepubertal stage.

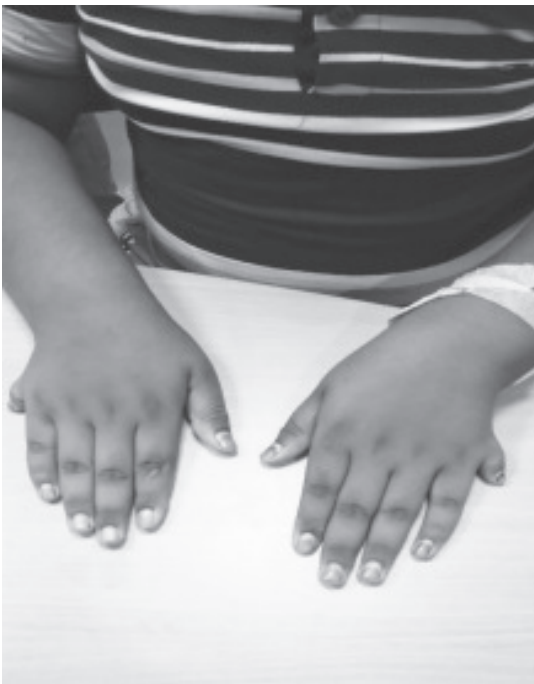

Fig.-1: Polydactyly on both hands

Acanthosis nigricans was found around the neck. His visual acuity was 6/60, and mixed astigmatism was present. Fundoscopic examinations revealed retinitis pigmentosa (both eyes). Other examinations revealed no abnormality.

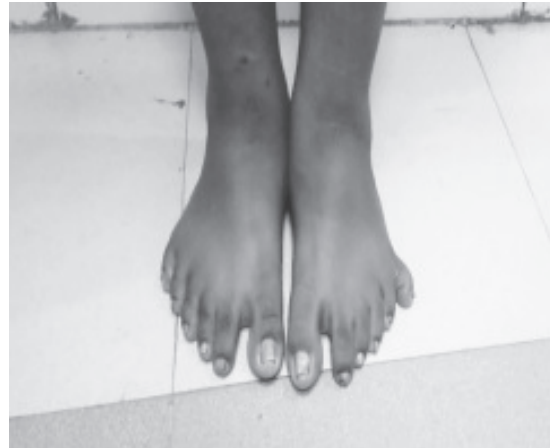

Fig.-2: Polydactyly on both feet

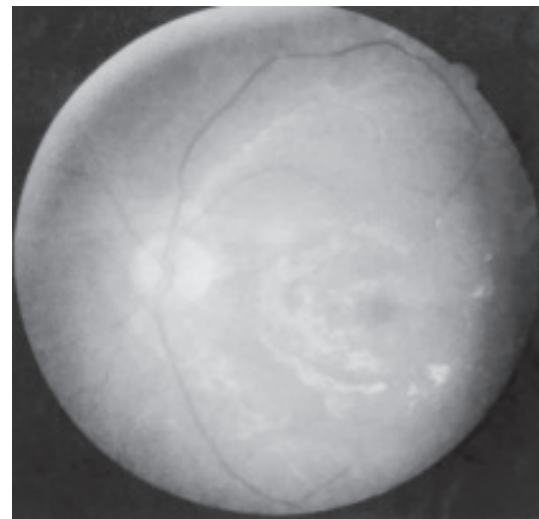


Fig.-3: Retinitis pigmentosa

Laboratory investigations include serum creatinine, Oral glucose tolerance test (OGTT), Alanine transaminase (ALT/SGPT), Fasting lipid profile, Free thyroxine (FT4), Thyroid stimulating hormone (TSH), Follicle-stimulating hormone (FSH) were normal. Luteinizing hormone (LH) was slightly low (aged matched reference range). Testosterone hormone low normal (aged matched reference range). Fatty infiltration in the liver (G-2) on ultrasound of the abdomen.

Our patient has polydactyly, obesity, retinitis pigmentosa, learning disabilities, hypogonadism, astigmatism, speech delay, and developmental delay. So, our patient clinically fulfils the diagnostic criteria for diagnosing Bardet- Biedl syndrome.

Discussion:

Bardet- Biedl syndrome (BBS) is a rare, an autosomal recessive, heterogenous and pleiotropic condition affecting multiple systems of the body. Bardet Biedl syndrome is characterized by rod-cone dystrophy, postaxial polydactyly, central obesity, mental retardation, hypogonadism in males or genital abnormalities in females, and renal dysfunction⁷ Brachydactyly/syndactyly, developmental delay, speech delay, ataxia, poor incoordination, mild spasticity, diabetes mellitus, dental crowding, high arched palate, cardiac or hepatic disease etc. also features of Bardet Biedl syndrome⁶.

Table I

Modified diagnostic criteria for Bardet-Biedl syndrome⁶.

Primary features	Secondary features
Rod cone dystrophy	Speech disorder/delay
Polydactyly	Strabismus/cataracts/ astigmatism
Obesity	Brachydactyly/ Syndactyly
Learning disabilities	Developmental delay
Hypogonadism in males	Polyuria/Polydipsia (Nephrogenic Diabetes Insipidus)
Renal anomalies	Ataxia/poor coordination/imbalance Mild spasticity Diabetes mellitus Dental crowding/ Hypodontia/small roots/High arched plate Left ventricular hypertrophy/ congenital heart disease Hepatic fibrosis

Rod-cone dystrophy found in Bardet-Biedl syndrome is an atypical retinitis pigmentosa characterized by an early decrease in visual acuity related to early macular involvement. The retinal periphery often has light bone spicule pigmentation, with central and peripheral RPE atrophy. Vessel attenuation and disc pallor are also present⁸. The retinal findings of our patient were consistent with retinitis pigmentosa.

Obesity in childhood may be a high index of suspicion for syndromic disorders. Obesity usually begins in childhood, and the severity increases with age. Our patient had 4 kg body weight at birth. Patient with Bardet Biedl syndrome also having an abnormality of the hands and feet. Postaxial polydactyly is common but extra finger may be present. Syndactyly is also presentation of Bardet Biedl syndrome usually found between the second and third toes. Fingers and toes may be short in length that is called brachydactyly may be present in Bardet Biedl syndrome. Our patient had polydactyly but no brachydactyly or syndactyly.

Hypogonadism occurs predominantly in men. Bardet-Biedl syndrome males have small penis and testes (88%)⁹. Renal failure is the major cause of morbidity and early mortality in BBS patients. A wide range of renal abnormalities has been described (chronic renal failure, parenchymal cysts, calyceal clubbing, fetal lobulation, scarring, unilateral agenesis, dysplastic kidneys, renal calculi, and vesicoureteric reflux)¹⁰. Renal dysfunction was absent in our case. Learning disabilities and developmental delay were found in our case. Fifty percent (50%) patient were developmental delay and late in reaching milestones⁶. Ataxia or poor coordination or imbalance is secondary features of Bardet Biedl syndrome. Forty percent (40%) patients showed signs of ataxia and poor coordination⁶ which were absent in our report. Fifty four percent (54%) patient having speech delay or deficit, requiring speech therapy⁶. Our patient had speech delay but improvement without any speech therapy. Acanthosis nigricans is a clinical sign of insulin resistance which was present in our case. Diabetes mellitus is a secondary features of Bardet Biedl syndrome but our patient having no diabetes mellitus. In Bardet Biedl syndrome

dental problems, congenital heart disease, left ventricular hypertrophy or hepatic fibrosis were present. Fatty infiltration in the liver (G-2) was present in our case. Bardet Biedl syndrome demonstrates highly variable expression, among affected siblings. Comparison of siblings with the Bardet-Biedl syndrome showed variation of the typical features, making the diagnosis difficult and often delayed.

Diagnosis of Bardet-Biedl syndrome is based on clinical features, but investigations may be needed to see the presence of complications, associated comorbidities and treatment plan. Genetic analysis is essential for molecular diagnosis, but it is not available in all places, especially in developing countries like Bangladesh.

Bardet-Biedl syndrome is a multisystem involvement disorder, so a multidisciplinary approach is needed to manage this disease. Genetic counselling is essential. Regular ophthalmological examination and periodic assessments clinically and biochemically to determine complications like renal, cardiac, hepatic and others. Dietary modifications and regular exercise for the obese patient. In many cases, surgical excision of extra digits for cosmetics purposes, visual aids, special school, speech & behavioral therapy, and hormonal therapy are required.

Conclusion

Bardet-Biedl syndrome is a rare disorder. Clinically diagnosis is possible, but the genetic analysis is also essential, which is not available in many countries. Proper counselling, as well as regular, follow up also important.

Acknowledgement

We gratefully acknowledge our Endocrinology & ophthalmology department, Dhaka Medical College Hospital.

References

1. Katsanis N, Lupski JR, Beales PL: Exploring the molecular basis of Bardet-Biedl syndrome. *Hum Mol Genet.* 2001, 10:2293-9. 10.1093/hmg/10.20.2293.
2. Laurence JZ, Moon RC. Four cases of retinitis pigmentosa occurring in the same family and accompanied by general imperfection of development. *Ophthalmol Rev* 1866; 2:32-41.
3. Bardet G. Sur un syndrome d'obésité congénitale avec polydactylie et rétinite pigmentaire (contribution à l'étude des formes cliniques de l'obésité hypophysaire). [These de Pris] (LeGrand) 1920;107.
4. Biedl A. Ein Geschwisterpaar mit adiposo-genitaler Dystrophie. *Dtsch Med Wochenschr* 1922; 48:1630
5. Kumar S, Mahajan BB, Mittal J. Bardet-Biedl syndrome: A rare case report from North India. *Indian J Dermatol Venereol Leprol* 2012; 78: 228
6. Beales PL, Elcioglu N, Woolf AS, Parker D, Flintner FA. New criteria for improved diagnosis of Bardet-Biedl syndrome: results of a population survey. *J Med Genet* 1999; 36:437-446.
7. Green JS, Parfrey PS, Harnett JD, Farid NR, Cramer BC, Johnson G, et al. The cardinal manifestations of Bardet-Biedl syndrome, a form of Laurence-Moon-Biedl syndrome. *N Engl J Med* 1989; 321:1002-9.
8. Iannaccone A, De Propriis G, Roncati S, et al. The ocular phenotype of the Bardet-Biedl syndrome. Comparison to nonsyndromic retinitis pigmentosa. *Ophthalmic Genet* 1997; 18: 13-26.
9. Kenneth Lyons Jones. Bardet-Biedl syndrome: Smith's Recognizable Patterns of Human Malformation 5th edition, saunders company; 1997;590-591.
10. Ahmed SN, Shahin MA, Chowdhury R, Ahammad AM, Shazzad MN, Alam MR, et al. A 13 year -old female with Bardet-Biedl syndrome - a case report. *Bangladesh J Med.* 2015; 26: 31-34.